

See discussions, stats, and author profiles for this publication at: <https://www.researchgate.net/publication/333774436>

Oxytocin-Induced Bilateral Serous Retinal Detachment

Article · June 2019

CITATIONS
0

READS
47

4 authors:



Nurgül Örnek

Kirikkale University

76 PUBLICATIONS 434 CITATIONS

[SEE PROFILE](#)



Kemal Örnek

Ahi Evran Üniversitesi

119 PUBLICATIONS 764 CITATIONS

[SEE PROFILE](#)



Inci Elif Erbahçeci

Ankara Atatürk Training and Research Hospital

13 PUBLICATIONS 48 CITATIONS

[SEE PROFILE](#)



Ozlem BANU Tulmac

Kirikkale University

12 PUBLICATIONS 41 CITATIONS

[SEE PROFILE](#)

Some of the authors of this publication are also working on these related projects:



Polycystic ovary syndrome [View project](#)



retina [View project](#)

Oxytocin-Induced Bilateral Serous Retinal Detachment

Oksitosine Bağlı İki Taraflı Seröz Retina Dekolmanı

Nurgül ÖRNEK¹, Kemal ÖRNEK², İnci Elif ERBAHÇEÇİ³, Özlem Banu TULMAÇ⁴

ABSTRACT

A 27-year-old multigravid patient was admitted with bilateral blurring of vision after caesarean delivery. She had history of oxytocin infusion for labor stimulation. Visual acuities were 1/10 in both eyes. Fundus examination showed bilateral serous retinal detachments affecting predominantly the posterior pole and the peripapillary area. Optical coherence tomography revealed bilateral serous retinal detachment of the macular area. Spontaneous resorption of the subretinal fluid started promptly the following day after the delivery. Large volumes of hypotonic solution with oxytocin may induce water retention during labor. This should be considered in the differential diagnosis of bilateral serous RD in pregnancy.

Key Words: Bilateral serous retinal detachment, oxytocin.

ÖZ

Yirmi yedi yaşında multigravid hasta sezaryenle doğum sonrası iki taraflı görme bulanıklığı ile başvurdu. Doğumu uyarmak amacıyla oksitosin infüzyonu hikayesi vardı. Görme keskinliği her iki gözde de 1/10 düzeyindeydi. Fundus muayenesi özellikle arka kutbu ve peripapiller alanı etkileyen bilateral seröz retina dekolmanı göstermekteydi. Optik koherens tomografide iki gözde makula bölgesinde seröz retina dekolmanı mevcuttu. Doğum sonrası ikinci günde subretinal sıvı kendiliğinden çekilmeye başladı. Doğum öncesi çok miktarda hipotonik sıvı ile birlikte oksitosin kullanımı sıvı retansiyonuna neden olabilmektedir. Gebelik döneminde iki taraflı seröz retina dekolmanı ayırıcı tanısında bu durum göz önünde bulundurulmalıdır.

Anahtar kelimeler: İki taraflı seröz retina dekolmanı, oksitosin.

INTRODUCTION

Acute visual loss after obstetrical interventions may not be so common in ophthalmology. It may occur due to various etiologies such as anemia, hypertensive choroidopathy and central serous chorioretinopathy etc.¹⁻⁴ Retinal detachment (RD) is a rare complication in pregnant women. It involves separation of the neurosensory retina from the pigmented retinal epithelium and it is one of the emergency states in ophthalmology. Many researches showed that, breakdown of blood-retina barrier, plays the major role in the pathogenesis of serous RD. There are several reports of bilateral serous RD due to preeclampsia and eclampsia which improved in the following weeks or months in the current literature.^{3,4}

Here, we report a rare case of drug-induced bilateral serous RD developing within hours after caesarean delivery who recovered in the following few days.

CASE REPORT

A 27-year-old multigravid patient experienced bilateral blurring of vision after caesarean delivery. Her medical history was unremarkable, with no smoking nor alcohol and drug consumption. She reported no past ocular history. The patient received continuous oxytocin infusion for labor stimulation. Six hours after she was admitted to the hospital, a caesarean section under spinal anaesthesia was performed due to failure to progress in the first stage of labor. Hemod-

1- Doç. Dr., Kırıkkale University School of Medicine, Department of Ophthalmology, Kırıkkale, Türkiye

2- Prof. Dr., Ahi Evran Üniversitesi, Training and Research Hospital, Department of Ophthalmology, Kırşehir, Türkiye

3- Uzm. Dr., Ankara Atatürk Training and Reserch Hospital, Ankara, Türkiye

4- Yrd. Doç. Dr., Kırıkkale University School of Medicine, Department of Gynecology and Obstetrics, Kırıkkale, Türkiye

Geliş Tarihi - Received: 24.05.2018

Kabul Tarihi - Accepted: 30.05.2018

Ret-Vit 2019; 28: 210-212

Yazışma Adresi / Correspondence Address:

Nurgül ÖRNEK

Kırıkkale University School of Medicine, Department of Ophthalmology, Kırıkkale, Türkiye

Phone: +90 318 444 4071

E-mail: nurgul_ornek@hotmail.com

ynamic parameters were normal and blood loss was estimated to be 150ml during the procedure. No vasoactive drug was administered. No intra-operative complications occurred and a healthy infant was delivered. Laboratory evaluations, including hematological and biochemical parameters were found to be normal.

In the early postoperative hours, at the same day post partum, the patient noticed decreased vision in both eyes. On ophthalmological examination, her visual acuities were 1/10 in both eyes. Extraocular motility testing was normal. Her

pupils were equally round and reactive, with no afferent pupillary defect. Anterior segment examination was unremarkable, however funduscopy revealed bilateral serous retinal detachments affecting predominantly the posterior pole and the peripapillary area. No vitreous cells, snowballs or snow banking were evident. Optical coherence tomography revealed a bullous serous retinal detachment of the macular area without vitreous traction. (Figure 1a-b)

As systemic investigations and medical history did not reveal any abnormalities, no treatment was initiated. Sponta-

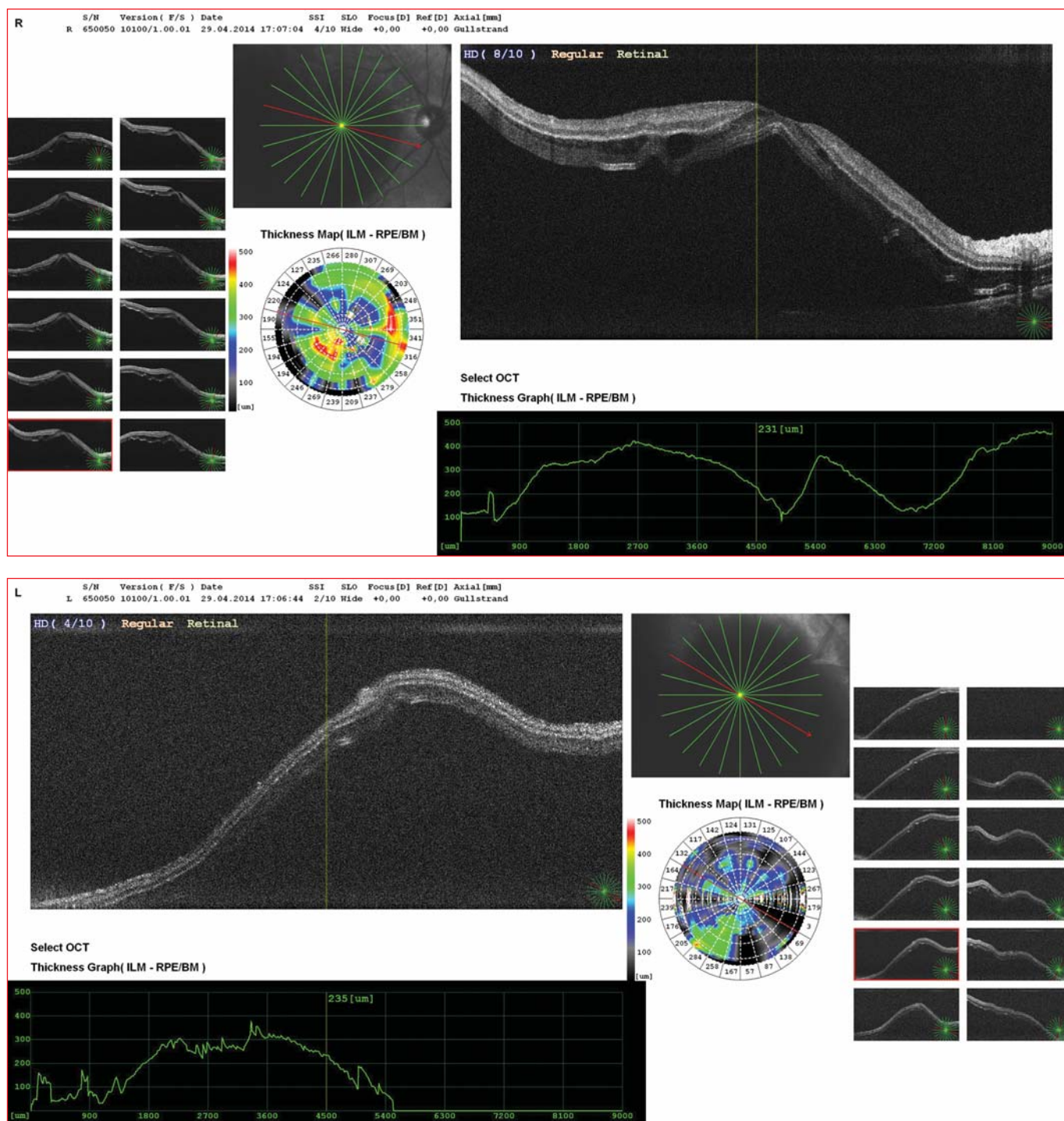


Figure 1a-b. Optical coherence tomography shows serous detachment of macula on both sides.

neous resorption of the subretinal fluid started promptly the following day after the delivery. Complete resolution of the retinal detachments occurred within five days in both eyes leaving mild pigment epithelial disturbances. The visual function returned to pre-detachment levels.

DISCUSSION

There is a broad spectrum in the differential diagnosis of serous RD, particularly if it is bilateral and a previous ocular trauma is lacking. It may occur as a result of fluid flow alterations and breakdown of the blood retinal barrier which could be observed in inflammatory, infectious and neoplastic disease states in addition to abnormal vasculature.^{5,6}

In hypertensive pregnant, RD is usually bilateral and serous and its pathogenesis is related to the choroidal ischemia. Ophthalmoscopy shows a serous detachment of the macula or late leakage and subretinal exudates can be observed. The choroidal vascular insufficiency can lead to lesions in retinal pigment epithelium (RPE), fluid transudation and focal retinal detachment with increasing severity. The management of serous RD is usually conservative and involves treating the underlying condition. Spontaneous resolution usually occurs within few weeks and visual prognosis is excellent. After delivery, the subretinal fluid is reabsorbed by the RPE and visual acuity could return to pre-detachment levels.^{3,4}

Oxytocin induced bilateral serous RD is a diagnosis of exclusion. Our case did not have any inflammatory reaction in the anterior chamber or vitreous. Furthermore, the absence of neurological and dermatological signs was not consistent with Harada's syndrome. There was no evidence of subretinal or choroidal masses. There was no clinical signs of hypertensive retinopathy and macular degeneration. In our case, serous RD developed within hours after the delivery and started to resolve at the first postoperative day, which may suggest a toxic effect. Also large amounts of hypotonic solution infusion could cause the serous detachment alone. In the light of the above data, we proposed that, serous RD in this case, could be associated with oxytocin toxicity or infusion of large amount of hypotonic solution or both.

Oxytocin is a hormone used to begin or continue labor and to control bleeding after delivery. Gombos et al⁷ reported

the only case of bilateral retinal detachment occurring in the immediate postpartum period after oxytocin administration. The patient recovered within two weeks and no systemic and ocular association was found for the clinical condition. Commercially available oxytocin preparations contain preservatives which may induce hypertension when used at high doses. As oxytocin is structurally related to vasopressin (an anti-diuretic hormone), it has also anti-diuretic properties when given in higher doses. If prolonged high dose of oxytocin is administered with large volumes of hypotonic solution, water retention (water intoxication) may take place in those patients.

To conclude, this case points out that oxytocin and/or large amount of hypotonic solution infusion should be included in the differential diagnosis of bilateral serous RD in cases of pregnancy. Both the ophthalmologists and obstetricians should be aware of the fact that serous RD may present in the absence of any ocular and systemic conditions. Additionally, the drug should be administered with adequate medical supervision and the patient should be informed about the favourable course of the condition to avoid unnecessary stress.

REFERENCES / KAYNAKLAR

1. Kawasaki A, Purvin V. Recovery of postoperative visual loss following treatment of severe anaemia. *Clin Experiment Ophthalmol.* 2006;34:497-9.
2. Liew G, Quin G, Gillies M, Fraser-Bell S. Central serous chorioretinopathy: A review of epidemiology and pathophysiology. *Clin Experiment Ophthalmol* 2013;41:201-14.
3. Sathish S, Arnold JJ. Bilateral choroidal ischaemia and serous retinal detachment in pre-eclampsia. *Clin Experiment Ophthalmol* 2000, 28, 387-90.
4. Chatwani A, Oyer R, Wong S. Postpartum retinal detachment. *Reprod Med*1989, 34, 842-4.
5. McGehee BE, Chaljub G, Shah RK, Oto A, Camacho AC, Tang RA. Bilateral retinal detachment in a patient with Vogt-Koyanagi-Harada syndrome. *Emerg Radiol.* 2005;11:366-71.
6. Elagouz M, Stanescu-Segall D, Jackson TL. Uveal effusion syndrome. *Surv Ophthalmol.* 2010;55:134-45.
7. Gombos GM, Howitt D, Chen S. Bilateral retinal detachment occurring in the immediate postpartum period after methylethylergonovine and oxytocin administration. *Eye Ear Nose Throat Mon.* 1969;48:680-2.