



## CASE REPORT

### ISOTRETINOIN INTOXICATION IN ATTEMPTED SUICIDE: A CASE REPORT

Turgut Deniz<sup>1</sup>, Can Emeksiz<sup>2</sup>

<sup>1</sup>Kirikkale University, School of Medicine, Department of Emergency Medicine, Kirikkale, Türkiye

<sup>2</sup>Kirikkale University, School of Medicine, Department of Dermatology, Kirikkale, Türkiye

#### ABSTRACT

We report a case of acute intoxication due to a massive overdose of isotretinoin. A 17 year-old male patient had ingested 16 capsules of isotretinoin (20 mg) with suicidal intentions. He presented with nausea, dizziness and myalgia on extremities. 2 hours after the attempt he was brought to our clinic. We administered gastric lavage and active charcoal treatment before taking him to the intensive care unit for observation. 24 hours later, cutaneous xerosis and desquamation of the face especially the nasolabial region occurred; cutaneous xerosis resolved spontaneously. The side-effects were only mild exacerbations of some common isotretinoin side-effects. There was a low toxicity of isotretinoin overdose. To date, few cases of isotretinoin overdoses have been reported. Being alert when using isotretinoin on a teenager may save life because this drug may exacerbate depression as a side effect.

**Keywords:** Isotretinoin, Intoxication, Suicide

### ÖZKIYIM AMAÇLI İSOTRETİNOİN İNTOKSİKASYONU

#### ÖZET

Yazımızda yüksek dozda isotretinoin alımına bağlı akut zehirlenme olgusunu rapor ettik. 17 yaşında erkek olgu özkıyım amaçlı olarak 16 kapsül(20 mg) almış. Sonrasında bulantı, baş dönmesi ve ekstremitelerde ağrı gelişmiş. Girişimden 2 saat sonra bizim kliniğimize başvurdu. Takip ve tedavi amaçlı olarak yoğun bakıma yatırılmadan önce acil serviste mide lavajı ve aktif kömür tedavileri uygulandı. 24 saat sonra kutanöz xerosis ve döküntüler gözlemlendi, kutanöz xerosisler kendiliğinden geriledi. Olgumuzdaki yan etkiler isotretinoin yan etkilerinin hafif artışı şeklindeydi. Bu doz hafif isotretinoin zehirlenmesiydi. Günümüze kadar isotretinoin zehirlenmesiyle ilgili çok az olgu rapor edilmiştir. İsoetretinoin kullanımı yan etki olarak depresyonun artırarak özellikle genç yaşta yaşamı tehdit eden girişimlere neden olabileceğinden çok dikkatli olarak kullanılmalıdır.

**Anahtar Kelimeler:** İsoetretinoin, İntoksikasyon, Özkıyım

#### INTRODUCTION

Isotretinoin is a drug resembling the chemical structure of vitamin A that is indicated for treatment of acne. Acne is a common disorder that may have a considerable psychologic impact

including anxiety and depression. Depression and suicide occur frequently in young adults. Isotretinoin use on depressed teenagers may save lives because this drug may exacerbate depression and its complications as a side effect. The objective of this report is to assess the clinical

#### İletişim Bilgileri:

Turgut Deniz, M.D.

Kirikkale University, School of Medicine, Department of Emergency Medicine, Kirikkale, Türkiye

e-mail: turgutdeniz@yahoo.com

Marmara Medical Journal 2008;21(3);269-272



effects, massive overdose of isotretinoin with suicidal intentions in a young patient.

### CASE REPORT

A 17 year-old male patient who had attempted suicide with a massive dosage of isotretinoin was admitted to the Emergency Department .

He had been using Isotretinoin (2x 20mg) for 6 days for the treatment of severe acne vulgaris.

His past medical history was unremarkable. He was not taking any other medications, and there was no family history of mental illness or past history of suicide attempt. At the 6<sup>th</sup> day of the treatment he took 16x20 mg capsules of isotretinoin (totally 320 mg) corresponding to 7 mg/kg/day or 8 times the prescribed dosage with suicidal intentions.

After the attempt, within 5-10 minutes, he had nausea, he felt dizziness, but did not vomit or faint. He described myalgia on his extremities within 1-2 hours. He applied to our service in the 2nd hour of the attempt.

He did not describe any back or headache. His general status was good, he was cooperative and orientated . His vital signs were: body temperature 36.7 °C, regular pulse rate of 74 beats per minute, blood pressure of 128/82 mm Hg, respiratory rate 18 breaths/min, and his neurological examination was normal.

In his physical examination he had no neurological, cardiovascular, respiratory or

ophthalmological findings. He had some acne on the face and upper back with papules and comedones. (Figure 1)

Gastric lavage, activated charcoal, intravenous hydration and electrocardiogram (ECG) monitoring were performed.

His complete blood count (CBC), biochemical and urine analysis values were all within normal range. The usual laboratory tests including liver function and serum lipids (cholesterol, triglycerides) were within normal limits.

Acute intoxication protocols were applied. Especially liver function tests were monitorized during approximately 36 hours. Liver functions, hemodynamical and vital values were stable during this period. He was referred to the psychiatry department and Fluoxetine liquid 1x1 was prescribed for depression. He was discharged from hospital after related departmental consultation.

7 days later he had a control visit. On this control visit his xerotic findings had disappeared completely spontaneously, also acne was mildly decreased although no other drug treatment had been used for the purpose. (Figure 2). His control blood values were all within normal range, as were the urinary test results.

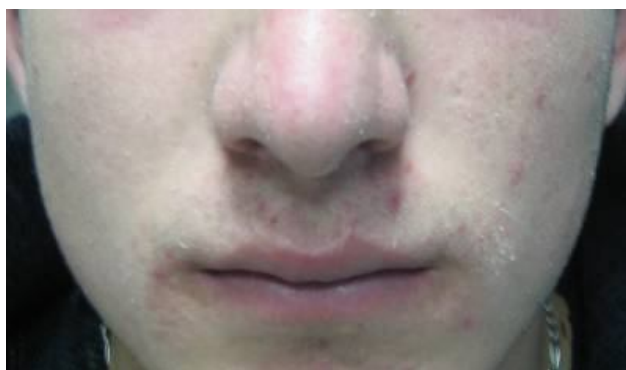


Figure 1:

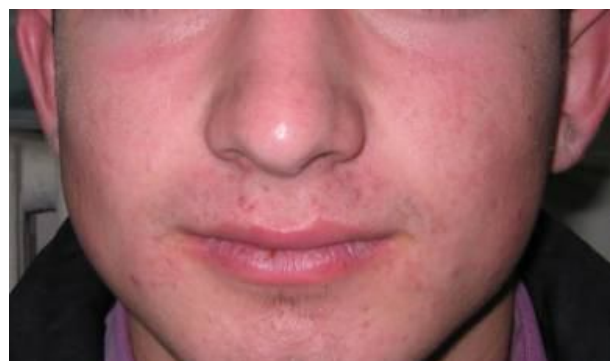

Figure 2:



## DISCUSSION:

He had no xerotic finding by the 6<sup>th</sup> day of this treatment. After the suicide attempt, he manifested clear cutaneous xerotic findings and tiny white scales on the nasolabial and malar regions, appearing within the 2<sup>nd</sup> hour of his attempt. Other early finding were myalgia and dizziness. He had no other isotretinoin side effect before then and the scales appeared just in the 2 hour-period after the attempt.(Figure 1)

The clinical findings were exacerbation of some common side effects. The mucocutaneous symptoms (cheilitis, xerosis, desquamation) are early components of intoxication<sup>1</sup> The facial acne decreased mildly in the days following the attempt. To date, there have been few cases of massive isotretinoin intoxication in the literature.

Sutton et al<sup>2</sup> reported a case (180 pound male) who used 80 mg of isotretinoin for nodulocystic acne daily for 6 weeks, then took 440 mg and 1600 mg in the following 2 days of his own accord to provide faster improvement.. He noted a headache, dryness and desquamation on his extremities and increased cheilitis.(Like our case except for the headache). All these resolved spontaneously, and laboratory tests were all within normal range.

Lindemary et al<sup>3</sup> reported a case (80 kg male) who used 60 mg of isotretinoin for nodulocystic acne daily for 8 weeks, then took 800 mg of isotretinoin (with 500mg of oxazepam, 450mg of doxepihydrochloride, 60 mg of 6-methylprednisolone and 5g erythromycin) in a suicide attempt.. He noted headache, itching, back pain and paraphasia within 8 hours. All these resolved spontaneously in one day and laboratory tests were all normal. Mild improvement of his acne was noticed over the following weeks. As in our case, mild improvement was detected. Also itching and paraphasia may somehow be secondary to dryness and cheilitis.

Hepburn et al<sup>4</sup> reported a case (15 year-old female) with severe acne intoxicated with 350 mg of isotretinoin. Gastric lavage was performed in 1.5 hours time. In 2 days, only abdominal discomfort was presented. Our case took 320mg in total, and did not vomit. We performed gastric lavage in the 2<sup>nd</sup> hour, but we think that at least 2 hours were enough time for the drug to pass into the circulation and have a toxic) Also our case did not complain of any abdominal discomfort.

Aubin et al<sup>1</sup> reported a case ( a 29 year-old male) with papulonodular acne on the body, intoxicated by 900 mg of isotretinoin. In a day he noted a mild headache and in 2 days, cheilitis, diffuse cutaneous xerosis and forehead and external auditory meatus desquamation (similar to the symptoms in our case except for the headache). Also 4-oxo isotretinoin (natural isotretinoin metabolite) was measured on the 4,5,6 and 11<sup>th</sup> days. It was concluded that resorption may differ interpersonally and enterohepatic circulation may influence the kinetics of the drug.

Acute vitamin A toxicity is characterized by drowsiness, irritability, blurred vision, abdominal pain, anorexia, nausea, vomiting, increased intracranial pressure, intense headache, and muscle weakness<sup>5</sup>. Isotretinoin toxicity is milder compared with other vitamin A derivatives. In our case, only mild cutaneous findings were present, such as xerosis, desquamation on the face and the beginning of cheilitis.

The evidence suggesting a relationship between isotretinoin and depression needs to be weighed against the increasing prevalence of depression among adolescents and young adults and the psychological impact of acne. The literature contains credible evidence that isotretinoin treatment may reduce the psychosocial impact of acne in some patients.<sup>6</sup> At the present time, there is no known pharmacological mechanism that would account for psychiatric symptomatology as a result of isotretinoin treatment; however, retinoid receptors are widely distributed in the brain and more



research is needed to ascertain whether they have a role in depression<sup>7</sup>. One must be careful when using this drug in depression, especially for teenagers. In our case, there had been no evident previous psychiatric problem. The patient was on the sixth day of the isotretinoin treatment. It is difficult to say that isotretinoin was the only cause but this drug is mostly used for adolescents as acne vulgaris is a common health problem; and depression often occurs at this age group. Being alert when using isotretinoin on a depressed teenager may save life, because this drug may exacerbate depression and its complications as a side effect. The causal relationship between isotretinoin therapy and depression has not been clearly established and needs further study.<sup>8</sup>

In conclusion, our case (320 mg total dose) confirms the low toxicity of isotretinoin overdose.

## REFERENCES

1. Aubin S, Lorette G, Muller C, Vaillant L. Massive isotretinoin intoxication. *Clin Exp Dermatol* 1995; 20:348-350.
2. Sutton JD. Overdose of isotretinoin. *J Am Acad Dermatol* 1983;9:600.
3. Lindemayer H. Isotretinoin intoxication in attempted suicide. *Acta Derm Venereol(Stockh)* 1986; 66:452-453
4. Hepburn NC. Deliberate self poisoning with isotretinoin. *Br J Dermatol* 1990;122:840-841
5. Bendich A, Langseth L. Safety of vitamin A. *Am J Clin Nutr* 1989;49:358-371.
6. Chia CY, Lane W, Chibnall J, Allen A, Siegfried E. Isotretinoin therapy and mood changes in adolescents with moderate to severe acne: a cohort study. *Arch Dermatol* 2005;141:557-560.
7. Hull PR, D'Arcy C. Isotretinoin use and subsequent depression and suicide: presenting the evidence. *Am J Clin Dermatol* 2003;4:493-505.
8. Ng CH, Schweitzer I. The association between depression and isotretinoin use in acne. *Aust N Z J Psychiatry* 2003;37:78-84.