

Comparison of the effect of contrast medium, air, and ozone on ischemia/reperfusion injury due to experimental intussusception model

Mine FEDAKAR ŞENYÜCEL¹, Ebru Şebnem AYVA², Mustafa Kemal ASLAN¹, Özlem BOYBEYİ¹,
Tutku SOYER^{1*}, Nurkan AKSOY³, Üçler KISA³, Ahmet Murat ÇAKMAK⁴

¹Department of Pediatric Surgery, Faculty of Medicine, Kırıkkale University, Kırıkkale, Turkey

²Department of Pathology, Faculty of Medicine, Başkent University, Ankara, Turkey

³Department of Biochemistry, Faculty of Medicine, Kırıkkale University, Kırıkkale, Turkey

⁴Department of Pediatric Surgery, Faculty of Medicine, Ankara University, Ankara, Turkey

Received: 22.06.2012

Accepted: 31.10.2012

Published Online: 29.07.2013

Printed: 19.08.2013

Aim: To compare effects of contrast medium, air, and ozone on ischemia/reperfusion injury due to intussusception.

Materials and methods: Thirty Wistar rats were allocated into five groups (n = 6). In the control group (CG), 2 cm of colonic segment, 5 cm distal to ileocecal valve, was removed. Intussusception was performed at 5 cm distal to the ileocecal valve by pushing a proximal intestinal segment distally by stilet in experimental groups. One hour later, in the sham-operated group (SG), manual reduction was performed. In the reduction groups, reduction of intussusception was performed by contrast medium (CMG, 1/1 diluted omnipaqueR, infusion rate 2 mL/min), by air (AG, Pmax = 60 mmHg), or by ozone (OG, 10 µg/mL, 0.5 mg/kg, Pmax = 60 mmHg). One hour after reduction, 2 cm of colonic segment was removed. Colonic tissues were evaluated for histopathological grades and oxidative injury markers (malondialdehyde [MDA], nitric oxide [NO], and total sulfhydryl [T-SH] values).

Results: Mucosal injury score was significantly higher in AG than in CG or SG (P < 0.05). There was no difference regarding mucosal injury between the other groups (P > 0.05). MDA levels were significantly higher and NO levels were significantly lower in CMG, OG, and AG than in CG (P < 0.05). There was no difference between OG and the other experimental groups in both MDA and NO levels (P > 0.05).

Conclusion: None of the reduction methods in intussusception have superiority over others in preventing ischemia/reperfusion injury.

Key words: Intussusception, ozone, intestine, ischemia-reperfusion, injury, experimental

1. Introduction

Intussusception (IN) is a clinical scenario described over 300 years ago, but it still remains incompletely understood. Recently, it has become clearly known that IN is the most common cause of acute small bowel obstruction in infants and preschool children (1,2). IN occurs by invagination of one part of the intestine to another. IN causes intense local edema, venous compression, congestion, and stasis in intussusceptum (1). If this process does not resolve, bowel congestion and pressure increases, resulting in ischemic changes in the bowel (1,3). The goal of treatment is either radiological or operative reduction without bowel resection (1,2). Therefore, both ischemic and reperfusion injury may occur after IN. Although diagnostic and therapeutic modalities of IN have been clearly identified, the ways of preventing ischemia and reperfusion (I/R) injury of the gut are not defined clearly.

Ischemia and consecutive perfusion cause oxidative stress that is characterized by imbalance between reactive oxygen species (ROS) and the antioxidative defense system (3). The reperfusion of ischemic tissue causes further cellular necrosis (4). The progressive necrosis may lead to functional impairment. Early after reperfusion, imbalance between the production of ROS and nitric oxide (NO) are observed. The inflammatory response due to this imbalance plays a crucial role in gut epithelial damage (4,5). Although many studies have been performed to evaluate intestinal I/R injury, I/R injury after reduction of IN was not evaluated previously.

Many antioxidant treatment modalities including hyperbaric oxygen administration were used to overcome I/R injury. Ozone was used successfully in ischemia, inflammation, and infection management (6,7). Ozone was also used in reduction of inflammation and oxidative

* Correspondence: soyer.tutku@gmail.com

stress in experimental colitis models as a mode of treatment (7). However, the effect of ozone on intestinal I/R injury occurring after reduction of IN has not been studied previously. Therefore, an experimental study was designed to compare the effects of contrast medium, air, and ozone on intestinal I/R injury due to IN.

2. Materials and methods

The experiments were performed with approval of the Ethics Committee of Kırıkkale University. Thirty Wistar albino rats, 6 months of age, weighing 300 ± 20 g, and of both sexes, were enrolled in the study. The rats were randomized into 5 groups. After being fasted overnight, the rats were anesthetized with intramuscular ketamine hydrochloride (80 mg kg^{-1} , Ketalar, Eczacıbaşı, İstanbul, Turkey). The first experimental group served as the control group (CG, $n = 6$) and 2 cm of intestinal segment, 5 cm distal to the ileocecal valve, was removed. IN was performed at 5 cm distal to the ileocecal valve by pushing the proximal intestinal segment distally by a stile in experimental groups (8,9). We produced the IN by pushing the proximal intestinal segment distally by a stile as described by Akman et al. (8). One hour later, in the sham-operated group (SG), manual reduction was performed. In experimental groups, reduction via the rectal route was performed 1 h after generating IN. Reduction was performed by contrast medium in the contrast medium group (CMG; 1/1 diluted omnipaque^R, Opakim, İstanbul, Turkey; infusion rate 2 mL/min), by air in the air group (AG; $P_{\text{max}} = 60 \text{ mmHg}$), and by ozone in the ozone group (OG; $10 \mu\text{g/mL}$, 0.5 mg/kg , $P_{\text{max}} = 60 \text{ mmHg}$). In all experimental groups, 1 h after reduction, 2 cm of colonic segment of IN was removed while the intestines were within the abdomen. In this way, all intestinal segments were removed after generating IN and the reduction of the related segment with 1 h of ischemia and 1 h of reperfusion time. All operations were performed while the intestinal segments were within the abdomen. Colonic samples were evaluated for histopathological grades and oxidative injury markers (malondialdehyde [MDA], nitric oxide [NO], and total sulfhydryl [T-SH] values).

The data obtained from the experiments were analyzed with the Kruskal–Wallis test and Mann–Whitney U test (SPSS 15.0). P-values lower than 0.05 were considered as significant.

2.1. Histopathological evaluations

Intestinal samples were inflated and fixed with 10% formalin. All segments were then embedded in paraffin. Tissues were sectioned into pieces of 4–5 μm and stained with routine hematoxylin and eosin stain. All specimens were examined under a light microscope (Leica, Germany) by the same pathologist, who was blind to the study. Histopathologic findings were graded according to the Chiu scoring system (10) (Table 1).

2.2. Determination of NO

Total nitrite/nitrate (NO) levels were measured by a spectrophotometric method as described by Miranda et al. (11). Nitrate was reduced to nitrite with vanadium(III) and then the nitrite level was measured by using Griess reagents. This reflects the total amount of nitrate and nitrite in the sample. Serial dilutions of Na nitrate (Merck, Germany) were used as standards. The results were expressed in $\mu\text{M/mg}$ protein.

2.3. Determination of T-SH

Tissue T-SH levels were determined by using the method of Sedlak and Lindsay (12). The calibration curve was prepared with glutathione standards with 5–0.3125 mmol/L dilutions. The results were calculated as nmol/mg protein.

2.4. Determination of MDA

All samples were put in a deep freezer ($-80 \text{ }^\circ\text{C}$). After washing with 0.9% NaCl, the tissue was homogenized (Labor Technique, Müllheim, Germany) with 1 mL of 0.9% NaCl solution in ice. The homogenized tissue was centrifuged at $1500 \times g$ for 10 min at $4 \text{ }^\circ\text{C}$. Supernatants were used for protein and MDA determinations. The protein level was measured using the method of Lowry et al. (13). MDA levels, indicating lipid peroxidation, were measured by the method described by Armstrong and Al-Awadi (14), which was modified from the Yagi method. The calibration curve was prepared with

Table 1. Histopathologic grades of colonic tissue (Chiu scoring system (10)).

Grade	Histopathologic finding
0	Normal mucosal villi
I	Development of a subepithelial space, usually at the tip of the villus, with capillary congestion
II	Extension of the subepithelial space with moderate lifting of the epithelial layer
III	Massive epithelial lifting down the sides of villi
IV	Denuded villi with lamina propria, dilated capillaries exposed, increased cellularity of the lamina propria
V	Digestion and disintegration of the lamina propria, hemorrhage, and ulceration

1,1,3,3-tetraethoxypropane (Sigma, St Louis, MO, USA) standards of 1- to 25-nmol/L dilutions.

3. Results

The histopathologic grades encountered in the groups are listed in Table 2. Histopathologic evaluations revealed that the mucosal injury score was significantly higher in AG when compared to CG and SG ($P < 0.05$). There was no difference regarding mucosal injury between the other groups ($P > 0.05$).

The mean values of NO, T-SH, and MDA in the groups are listed in Table 3. Biochemical analysis showed that MDA levels were significantly higher in CMG, OG, and AG than in CG ($P < 0.05$). NO levels were significantly lower in CMG, OG, and AG than in CG ($P < 0.05$) (Figure). There was no difference between OG and CMG in both MDA and NO levels ($P > 0.05$). There was also no difference between OG and AG in both MDA and NO levels ($P > 0.05$). There was no difference between all experimental groups in T-SH levels ($P > 0.05$).

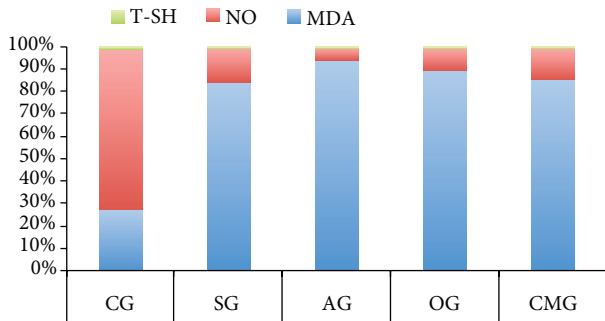


Figure. Comparison of groups for MDA, NO, and T-SH levels. *: MDA, $P < 0.05$; β : NO, $P < 0.05$.

4. Discussion

IN is a well-known entity with well-known diagnostic and therapeutic modalities. However, the ways of preventing I/R injury of the intestine after IN and reduction of IN are not defined clearly. We therefore conducted an experimental study to compare the effects of contrast medium, air, and ozone on intestinal I/R injury due to IN. We produced the IN by pushing the proximal intestinal segment distally by a stile as described by Akman et al. (8). One hour later, reduction was performed in the experimental groups, and after 1 h of reperfusion time colonic samples were taken for evaluation of histopathological changes and oxidative injury markers. However, we could not detect any superiority among the reduction methods in preventing I/R injury.

Since previous experimental models of IN were obtained by lipopolysaccharide administration, it not possible to evaluate the intestinal I/R injury in IN. After Akman et al. defined the first surgical model of IN, the effects of several antioxidants on intestinal I/R injury became the focus of interest for several authors (8). In this experimental study, we used ozone as an agent for reduction of IN and compared the results of ozone reduction with other methods such as contrast medium and air. Histopathologic alterations in the colonic mucosa and biochemical markers for oxidative stress were evaluated. This is the first study in which ozone was proposed as a reducing agent in IN.

Histopathologic evaluations of colonic samples revealed various grades of mucosal injury due to IN. AG had higher grades of colonic injury when compared to CG and SG. However, a similar difference was not detected between the other reduction groups (CMG and OG). It was shown that the duration of I/R directly affects the gastrointestinal injury (5). In the present study, there was no time and no pressure difference in reduction of the groups. However, AG had higher grades of injury. Therefore, no

Table 2. Distribution and median of histopathological grades in groups.

Groups	Grade 0	Grade I	Grade II	Grade III	Grade IV	Grade V	Median (IQR)*
CG	2	4	-	-	-	-	0 (0-1) *
SG	1	4	1	-	-	-	1 (0.75-1.25) β
AG	-	-	1	-	1	4	4 (3.5-4.25) * β
OG	3	1	1	-	1	-	1 (0-3.5)
CMG	1	1	1	1	2	-	2.5 (0.75-4)

IQR: interquartile range, *: $P = 0.01$, β : $P = 0.03$.

Table 3. Mean values of NO, MDA, and T-SH levels in groups.

	MDA (nmol/mg protein)	NO (μ mol/mg)	T-SH (nmol/mg)
CG	0.35 (0.1–2.12) * β γ	0.92 (0.74–1.19) \ddagger ϵ $\bar{\cup}$	0.01 (0.008–0.018)
SG	2.98 (1.4–4.22)	0.5 (0.36–0.83)	0.003 (0.002–0.023)
AG	4.17 (1.8–5.19) *	0.25 (0.18–0.58) \ddagger	0.007 (0.006–0.013)
OG	3.55 (1.51–5.03) β	0.4 (0.34–0.7) ϵ	0.008 (0.006–0.012)
CMG	3.53 (1.07–4.19) γ	0.59 (0.49–0.75) $\bar{\cup}$	0.01 (0.007–0.013)

*: P = 0.025, β : P = 0.016, γ : P = 0.014, \ddagger : P = 0.025, ϵ : P = 0.010, $\bar{\cup}$: P = 0.014.

clear explanation can be attributed to this histopathologic finding. The histological alterations detected in OG also did not show any significant difference. Therefore, we suggest that histopathological changes in colonic tissues after IN may be related to the severity of ischemia, and not related to the type of reduction.

The inflammatory response caused by reperfusion of ischemic tissues may lead to further cellular necrosis. The production of reactive oxygen metabolites is increased and the production of NO is decreased early after reperfusion (4). Altered balance between NO and ROS results in endothelial cell dysfunction of microcirculation (4). Significantly decreased levels of NO in CMG, OG, and AG in the present study indicate profound I/R injury after reduction. The absence of difference between the groups in regards to NO levels reveals that I/R injury occurs after reduction of IN, regardless of the method used.

Tissue lipid peroxidation was measured by MDA levels, which is an indicator of oxidative damage induced by I/R (6). It has been shown that I/R causes a significant increase in MDA levels. We found increased levels of MDA in all the treatment groups, revealing oxidative damage. Junior et al. evaluated the alterations in MDA and NO levels 60 min after ischemia followed by a reperfusion period of 30 min (15). In that study, no alteration was detected in MDA and NO levels between the groups and this was attributed to insufficient reperfusion time (15). On the other hand, MDA levels were not different in the sham group and the control group. This result can be related to the method of the IN model. However, it has been shown that oxidative damage occurred after IN was performed with the same method before (8). Absence of difference between SG and CG regarding MDA levels does not mean that oxidative stress has not occurred after IN in the present study. It can be explained by the small number of animals that were used in this study because of ethical concern.

Although ozone is known as an oxidant agent in chemistry, it was used to prevent ischemia, inflammation, and infection in several previous studies. The powerful oxidant capacity of ozone was thought to be related to its efficacy. It has also been shown to attenuate I/R injury, in contrast to the idea that ozone is an oxidant (6). Koca et al. produced preconditioning with ozone and hyperbaric oxygen, by which cellular antioxidant systems involving glutathione, superoxide dismutase, catalase, and enzymatic reactions were stimulated and prepared the host to face pathophysiological conditions mediated by oxidative/nitrosative stress (6). Koca et al. stated that ozone-induced preconditioning had protective effects on I/R injury rather than the ozone being an antioxidant (6). Koca et al. (6) performed ozone application 72 h before ischemia and continued until the ischemia started. They concluded that ozone can prepare tissues by reducing nitric oxide synthase expression when used as a preconditioning agent. However, in the present study we performed ozone application just after ischemia occurred. The reason why we could not detect the antioxidant effect of ozone might be insufficient time to prepare the tissues for ischemic injury.

In addition, ozone has postconditioning effects, as well (16). Iglesias et al. applied ozone therapy after I/R injury, which is called postconditioning, and concluded that ozone postconditioning reduces histopathological changes due to I/R injury (16). In contrast, we used ozone as a reduction agent; ozone was used after ischemia and before reperfusion. Therefore, we could not detect an antioxidant effect of ozone in I/R injury after IN. On the contrary, we found increased MDA and decreased NO levels after reduction with ozone when compared to the control group. Therefore, we suggest that ozone therapy has an oxidant effect on colonic tissues, rather than antioxidant activity. This discrepancy can be explained by several methodological differences. First, the antioxidant

efficacy of ozone can be detected when it is used before ischemia via preconditioning, preconditioning, or postconditioning. The other reason for the oxidant effect of ozone can be explained by the dose-dependent efficacy. If we could prove the antioxidant activity of ozone, we would gain further knowledge regarding the mechanism of ozone activity. We suggest that these points should be the subject of future studies.

Although this is the first study in which ozone was proposed as a reducing agent in IN, our study has some limitations. In this study, IN was generated surgically and did not exactly simulate the IN that occurs in children. However, histopathologic findings of intestinal injury confirmed that intestinal injury after our experiments showed similar histopathologic findings to those encountered in children. Different reperfusion periods with difference reduction methods should also be

evaluated in order to have firm conclusions about the use of ozone in IN reduction by future studies with larger number of samples.

In conclusion, it has been demonstrated that none of the reduction methods in IN have superiority over the others in preventing I/R injury. The results obtained from OG have conversely shown that ozone has an oxidant effect rather than an antioxidant activity. This result can be explained by the dose-dependent efficacy of ozone therapy, administration method of ozone, and/or insufficient reperfusion time.

Acknowledgment

This study was presented at the 29th National Congress of Turkish Pediatric Surgeons, in 2011 in İstanbul, Turkey, and was supported by the Kırıkkale University Scientific Research Council.

References

1. Young DG. Intussusception. In: O'Neil JA, Rowe MI, Grosfeld JL, Fonkalsrud EW, Coran AG, editors.. *Pediatric Surgery*, 5th ed. St Louis (MO): Mosby; 1998. p.1185-98.
2. Loukas M, Pellerin M, Kimball Z, de la Garza-Jordan J, Tubbs RS, Jordan R. Intussusception: an anatomical perspective with review of the literature. *Clin Anat* 2011; 24: 552-61.
3. Karnak I, Senocak ME, Kale G, Akçören Z, Büyükpamukçu N, Hiçsönmez A. A previously unmentioned surgical observation in the treatment of intussusception. *Surg Today* 1999; 29: 979-82.
4. Carden DL, Granger DN. Pathophysiology of ischaemia-reperfusion injury. *J Pathol* 2000; 190: 255-66.
5. Çağlayan F, Şahin A, Günel E, Çakmak M, Çağlayan O. The effect of ischemia reperfusion on intestinal contractility regulated by the nitrergic system. *Turk J Vet Anim Sci* 2004; 28: 845-50.
6. Koca K, Yurttaş Y, Yıldız C, Çaycı T, Uysal B, Korkmaz A. Effect of hyperbaric oxygen and ozone preconditioning on oxidative/nitrosative stress induced by tourniquet ischemia/reperfusion in rat skeletal muscle. *Acta Orthop Traumatol Turc* 2010; 44: 476-83.
7. Altinel O, Demirbas S, Cakir E, Yaman H, Ozerhan IH, Duran E et al. Comparison of hyperbaric oxygen and medical ozone therapies in a rat model of experimental distal colitis. *Scand J Clin Lab Invest* 2011; 71: 185-92.
8. Akman H, Somuncu S, Dikmen G, Ayva Ş, Soyer T, Doğan P et al. Protective effect of selenium on intussusception-induced ischemia/reperfusion intestinal oxidative injury in rats. *Turk J Med Sci* 2010; 40: 391-97.
9. Çakmak M, Soyer T, Ayva Ş, Dikmen G, Akman H. İnvajinasyonun oluşturduğu intestinal hasar üzerine trapidilin koruyucu etkileri. *Çocuk Cerrahisi Dergisi* 2009; 23: 12-6 (article in Turkish).
10. Chiu CJ, McArdle AH, Brown R, Scott HJ, Gurd FN. Intestinal mucosal lesion in low-flow states. *Arch Surg* 1970; 101: 478-83.
11. Miranda KM, Espey MG, Wink DA. A rapid simple spectrophotometric method for simultaneous detection of nitrate and nitrite. *Nitric Oxide* 2001; 5: 62-71.
12. Sedlak J, Lindsay RH. Estimation of total, protein-bound, and nonprotein sulfhydryl groups in tissue with Ellman's reagent. *Anal Biochem* 1968; 25: 192-205.
13. Lowry OH, Rosebrough NJ, Farr AL, Randall RJ. Protein measurement with Folin phenol reagent. *J Biol Chem* 1951; 193: 265-75.
14. Armstrong D, Al-Awadi F. Lipid peroxidation and retinopathy in streptozotocin-induced diabetes. *Free Radic Biol Med* 1991; 11: 433-6.
15. Ciscato JG Jr, Capellini VK, Celotto AC, Baldo CE, Joviliano EE, Evora PR, Dalio MB, Piccinato CE. Vascular relaxation of canine visceral arteries after ischemia by means of supraceliac aortic cross-clamping followed by reperfusion. *Scand J Trau Resus Emerg Med* 2010; 18: 41.
16. Iglesias AF, Núñez LG, Fernández JLC, Salgueiro SR, Febles ES. Ozone postconditioning in renal ischaemia-reperfusion model. Functional and morphological evidences. *Nefrologia* 2011; 31: 464-70.