



Contents lists available at ScienceDirect

International Journal of Surgery Case Reports

journal homepage: www.casereports.com

Esthesioneuroblastoma located in the thoracic extradural space: Case report



Mehmet Hüseyin Akgul (MD) (Assistant Professor)^{a,*}, Ferruh Gezen (PhD,MD)^b,
Ali Kemal Uzunlar (PhD,MD)^c

^a Kırıkkale University Medical Faculty, Department of Neurosurgery, Kırıkkale, Turkey

^b Medeniyet University Medical Faculty Department of Neurosurgery, Istanbul, Turkey

^c Düzce University Medical Faculty, Department of Pathology, Düzce, Turkey

ARTICLE INFO

Article history:

Received 5 April 2016

Received in revised form 26 May 2016

Accepted 8 June 2016

Available online 30 July 2016

Keywords:

Esthesioneuroblastoma

Methastasis

Thoracic vertebrae

ABSTRACT

OBJECTIVE: Esthesioneuroblastoma accounted for only 6% of the malignant nasal cavity neoplasms (ENB) is a rare tumor which originates from the olfactory epithelium. ENB's are locally aggressive and can metastasize by lymphatic and hematogenous routes. A patient with the mass on the nasal dorsum was reported in this article.

CASE HISTORY: A 52-year-old man admitted to the hospital with a 3 months history of progressive nasal obstruction, epistaxis and mass on the nasal dorsum. On rhinoscopy, a polypoid mass was seen in the both nasal cavity and intranasal biopsy with local anesthesia was performed. Histopathologic diagnosis of the tumor was Kadish stage B esthesioneuroblastoma. Tumor was excised by using bilateral endoscopic endonasal resection and lateral rhinotomy approach and paranasal radiotherapy performed postoperatively. Ten months after surgery, neck metastasis was occurred and patient was underwent neck dissection. Twentieth months after initial treatment, distant metastasis was identified on the T 10 vertebra and following the cranial and spinal radiotherapy to the neck he was free of local recurrence at follow up 13 months after surgery.

CONCLUSION: It has been known that the metastasis of the ENB to the spinal cord is an uncommon event, and it occurs often years after initial diagnosis. MRI scan is helpful for making the diagnosis, and surgery is the treatment of choice for obtaining diagnostic tissue and debulking the tumor. Radiotherapy is also a mainstay of postoperative treatment.

© 2016 Published by Elsevier Ltd on behalf of IJS Publishing Group Ltd. This is an open access article under the CC BY-NC-ND license (<http://creativecommons.org/licenses/by-nc-nd/4.0/>).

1. Introduction

Esthesioneuroblastoma (ENB) accounted for only 6% of the malignant nasal cavity neoplasms (ENB) is a rare tumor which originates from the olfactory epithelium [1]. Although these tumors have a bimodal age distribution occurring second and sixth decades of life, it can be seen all age groups [2]. ENBs are locally aggressive and can metastasize by lymphatic and hematogenous routes. The cervical lymph nodes are the most common site of metastasis. It can spread submucosally in all directions, involving the paranasal sinuses, nasal cavities and cross the cribriform plate and involving brain. Because of non specific symptoms such as nasal obstruction, epistaxis, headache, diagnosis frequently delayed. In this article we reported a case of diagnosis delayed patient attended our clinic after occur the mass on the nasal dorsum.

2. Case report

A 52-year-old man admitted to the Ear-Nose-Throat clinic with history of progressive nasal obstruction, and epistaxis during 3 months. On rhinoscopy, a painless polypoid mass in 3 × 3 cm diameters was seen in the both nasal cavity and the nasal dorsum without palpable mass on the neck. His vision and eye movements were normal in both eyes. A paranasal computed tomography (CT) scan confirmed this mass filled both nasal cavity. Although this mass extended into the bilateral ethmoid and frontal sinuses and invaded left lamina papyrea, its intracranial extension was not seen on CT images. Intranasal biopsy with local anesthesia was performed to the mass, and histopathological diagnosis was ENB with kadish stage B. The mass was removed near total through the bilateral endoscopic endonasal approach and lateral rhinotomy approach. Whole paranasal radiotherapy was performed postoperatively. Uneventfully, neck metastasis of residual mass was identified ten months after surgery, and whole neck radiotherapy protocol was performed to the patient. After radiotherapy, he was

* Corresponding author.

E-mail addresses: dr_mhakgul@yahoo.com (M.H. Akgul), ferruhgezen@duzce.edu.tr (F. Gezen), alikemaluzunlar@gmail.com (A.K. Uzunlar).

<http://dx.doi.org/10.1016/j.ijscr.2016.06.015>

2210-2612/© 2016 Published by Elsevier Ltd on behalf of IJS Publishing Group Ltd. This is an open access article under the CC BY-NC-ND license (<http://creativecommons.org/licenses/by-nc-nd/4.0/>).

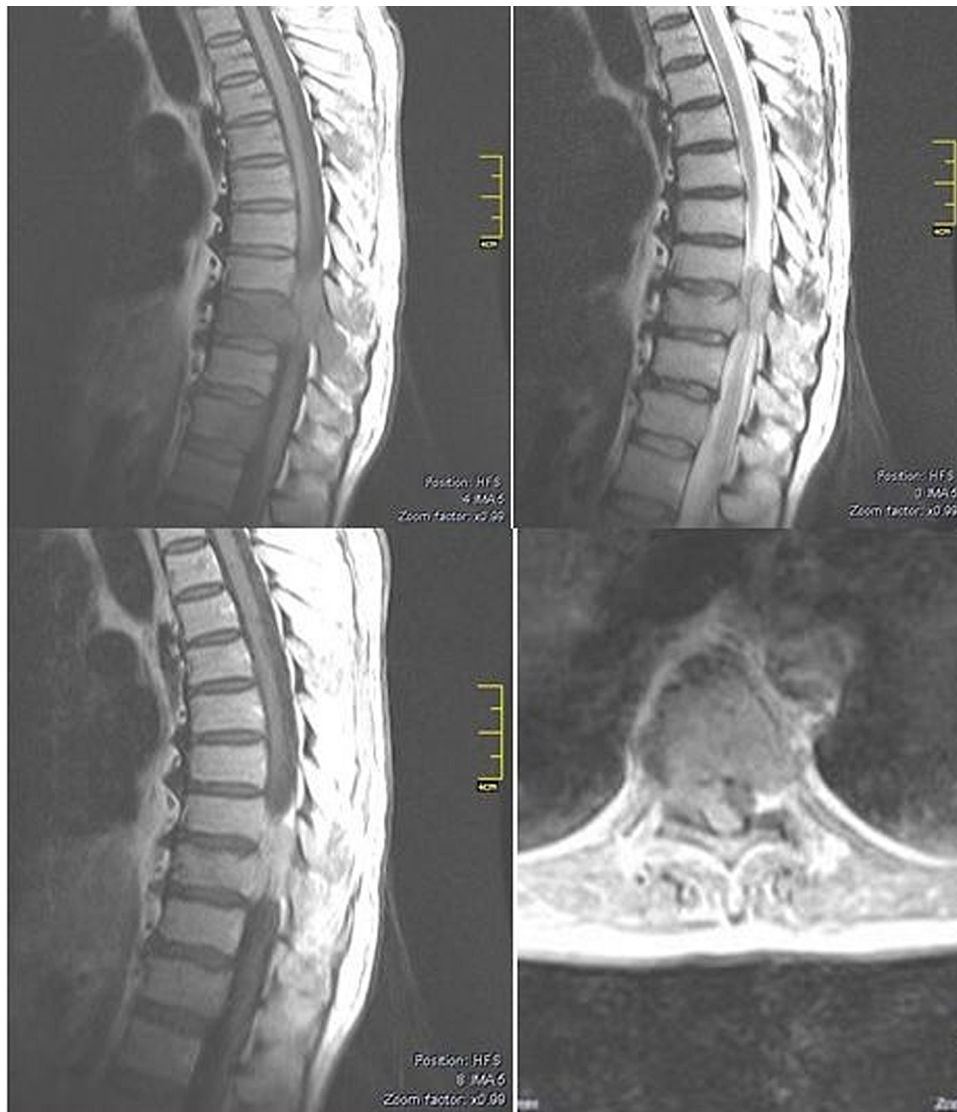

Fig. 1. A. T1 thoracic sagittal MRI shows epidural metastatic ENB in T9–10 level. B. T2 thoracic sagittal MRI shows epidural metastatic ENB in T9–10 level. C. T1 thoracic sagittal contrast-enhanced MRI showing intense homogeneous enhancement of epidural metastatic ENB in T9–10 level, and D. T1 thoracic sagittal contrast-enhanced MRI showing intense homogeneous enhancement of epidural metastatic ENB in the left side the T9–10 level of epidural space.

underwent to the extensive neck dissection surgery. histopathological diagnosis was same.

Two months after the second surgery, he was admitted to the hospital with acute paraplegia. Sensory exam was unfeeling to light touch and pin prick of lower dermatomes to T12 with areflexia. Babinski reflex was plantar extensor in right leg and flexor in left leg. Anal tonus was mild. His complete blood chemistry was within normal limits. An emergency thoracic magnetic resonance imaging (MRI) with gadolinium showed an enhancing extradural tumor which almost completely filled the spinal canal and thoracic 10 (T10) vertebrae body. Other organ metastasis was not found radiologically (Fig. 1). The patient was immediately taken to operation room. Total laminectomy was performed to the T10 vertebrae. Then, large extradural mass was removed subtotally. The histopathological diagnosis was ENB (Fig. 2). One week after laminectomy, T9 and T10 anterior corpectomy, T10–T11 discectomy and T9–T10–T11 cage-plate-screw-link stabilization through the right thoracotomy was performed to the patient to remove the tumoral mass gross totally and to protect him from the progressive kyphotic deformity. The postoperative period was uneventful, and his neurological examination was better than preoperative

period. He was discharged to home on 14th day postoperatively. He died of local recurrence at follow up 13 months after the last surgery.

3. Discussion

ENB is a rare malignant tumor of nasal cavity, and it arises from the olfactory neuroepithelium located in the nasal septum, cribriform plate and the middle and superior turbinates [3]. Commonly, ENB causes unilateral nasal obstruction and epistaxis. It also causes anosmia, headache, proptosis, diplopia and excessive lacrimation when tumor extends to the orbita. In present case, the patient complained of bilateral nasal obstruction, epistaxis due to the tumor located in the both nasal cavity and the nasal dorsum.

ENBs are staged clinically with Kadish system based on the spread of the tumor [2]. According to this system,

- stage A tumors are confined to the nasal cavity,
- stage B lesions involve the sinuses, and
- stage C masses involve the middle cranial fossa and the retrobulbar orbit [4].

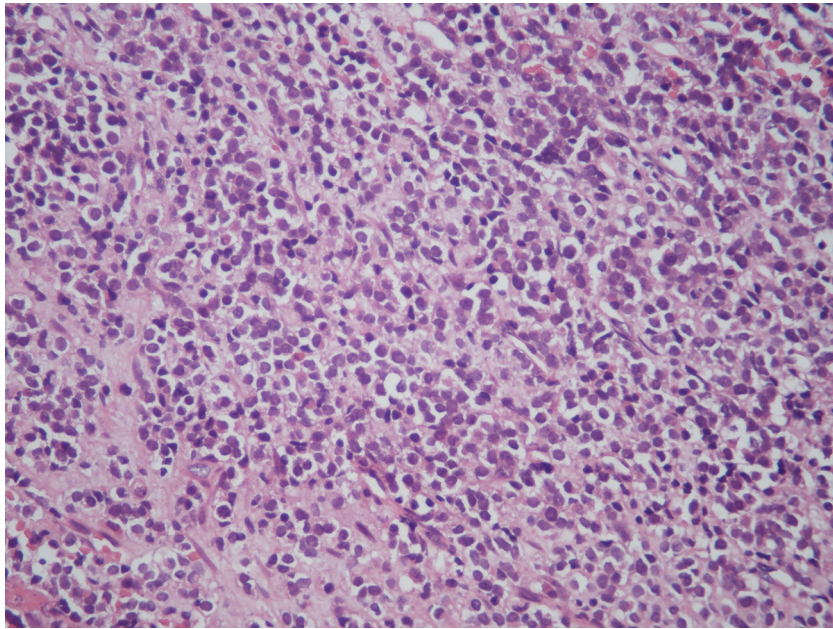


Fig. 2. Histologic sections of T9-10 preoperative lesion confirm the impression of a metastatic ENB. The tumor is cellular and is positive for markers of neuronal (neuron specific enolase). As well as of a sustentacular differentiation. Original magnification: $\times 200$.

Table 1

Cedars-Sinai classification system for metastatic esthesioneuroblastoma to the spine.

Stage	Anatomic location of lesion
CS0-leptomeningeal disease	Involvement of the CSF and leptomeninges (arachnoid and pia mater)
CS1a-one level disease	Involves one level of the spine or spinal cord: cervical, thoracic, lumbar, or sacral
CS1b-one level disease and leptomeningeal disease	Involves one level of the spine or spinal cord: cervical, thoracic, lumbar, or sacral; with involvement of the CSF and leptomeninges (arachnoid and pia mater)
CS2a-two level disease	Involves two levels of the spine or spinal cord: cervical, thoracic, lumbar, or sacral
CS2b-two level disease and leptomeningeal disease	Involves two levels of the spine or spinal cord: cervical, thoracic, lumbar, or sacral; with involvement of the CSF and leptomeninges (arachnoid and pia mater)
CS3a-three level disease	Involves three levels of the spine or spinal cord: cervical, thoracic, lumbar, or sacral
CS3b-three level disease and leptomeningeal disease	Involves three levels of the spine or spinal cord: cervical, thoracic, lumbar, or sacral; with involvement of the CSF and leptomeninges (arachnoid and pia mater)
CS4a-four level disease	Involves four levels of the spine or spinal cord: cervical, thoracic, lumbar, or sacral
CS4b-four level disease and leptomeningeal disease	Involves four levels of the spine or spinal cord: cervical, thoracic, lumbar, or sacral; with involvement of the CSF and leptomeninges (arachnoid and pia mater)

Diaz et al suggested that all the tumoral recurrences occur in patients with kadish stage C tumors [5]. On the other hand, many other authors reported in literature that the most frequent tumoral recurrence is local; and this high incidence of local recurrence is directly related to inadequate tumor resection margins [6]. It has been demonstrated in literature that surgery alone seems to be ineffective for local control of ENB, and many authors suggest postoperative radiotherapy to reduce the risk of local recurrence of the tumor. In the adjuvant or neo-adjuvant platinum-based chemotherapy in addition to radiotherapy has been often chosen for local control of recurrence or distant metastasis [13]. Although craniofacial resection combined with radiotherapy is considered the gold standard treatment in management of ENB today, some serious complications are represented after craniofacial resection in recent literature [7,8]. To avoid from these complications, recent reports have suggested to treat the ENB with minimally invasive surgery such as endoscopic approaches which could have some advantages such as short duration of surgery, short hospitalization and a better quality of life without anesthetic damage [6–8]. In present case, before the radiotherapy administration, bilateral endoscopic endonasal resection and lateral rhinotomy approach which could give enough surgical corridor to the surgeon to remove the tumor from the nasal dorsum was preferred and performed to the patient. Eleven months after surgery, no local

recurrence in nasal cavity and nasal dorsum was observed at follow up exams.

Neck metastasis can occur early in the disease or many years later. Neck dissection is indicated only in the presence of nodes, and elective dissection appears to be unnecessary. The incidence of distant metastasis (such as lung, brain, bone etc.) occur in 12%–25% of patients [10]. Additionally, metastasis to the spinal cord from ENB which is an uncommon event presents often years after initial diagnosis. The incidence of cervical metastasis of the ENB varies from 10% to 33% at the time of the diagnosis [9]. But thoracic metastasis of the ENB is very rare. In literature nearly 30 patients with vertebral drop metastases has been documented today. ENB is a locally aggressive tumors and its recurrence ratio is reported 10% to 60%. On the other hand, despite aggressive treatment it commonly could metastasize to the cervical lymph nodes or lungs beyond 1 month to 10 years in literature [11,12]. Drop metastasis to spine is classified by Cedars-Sinai (See Table 1) [13]. In addition to Mori and Zhang et al. described cauda equina metastases of the ENB treated with surgical resection and radiation therapy [12,14]. In present case, distant metastasis to the T10 vertebra 12 months after initial treatment and it could be diagnosed.

In conclusion, practitioners should suspect the drop metastases in their patients with ENB who suffers from the back and/or radiculopathic pain.

4. Conclusion

Spinal metastasis has been shown to occur in many different tumors, but intradural and cauda equina metastases are rare. Because of locoregional recurrences are common, patients must be followed carefully for locoregional and distant metastasis.

Conflict of interest

None.

References

- [1] (a) V. Svane-Knudsen, K.E. Jorgensen, O. Hansen, et al., Cancer of the nasal cavity and paranasal sinuses: a series of 115 patients, *Rhinology* 36 (1998) 12–14;
(b) P.J. Bradley, N.S. Jones, I. Robertson, Diagnosis and management of ENB, *Curr. Opin. Otolaryngol. Head Neck Surg.* 11 (2003) 112–118.
- [2] E.M. Diaz, R.H. Johnigan III, C. Pero, et al., Olfactory neuroblastoma: the 22 year experience at one comprehensive cancer center, *Head Neck* 27 (2005) 138–149.
- [3] S. Kadish, M. Goodman, C.C. Wang, Olfactory neuroblastoma A clinical analysis of 17 cases, *Cancer* 37 (1976) 1571–1576.
- [4] V.J. Lund, D. Howard, W. Wei, M. Spittle, Olfactory neuroblastoma: past, present, and future, *Laryngoscope* 113 (2003) 502–507.
- [5] C. Walch, H. Stammberger, W. Andrehuber, F. Unger, W. Kole, K. Feichtinger, The minimally invasive approach to olfactory neuroblastoma: combined endoscopic and stereotactic treatment, *Laryngoscope* 110 (2000) 635–640.
- [6] A. Morita, K.D. Ebersold, J.E. Lewis, L.M. Quast, ENB: prognosis and management, *Neurosurgery* 32 (1993) 706–715.
- [7] F. Unger, K. Haselberger, C. Walch, H. Stammberger, G. Papaefthymiou, Combined endoscopic surgery and radiosurgery as treatment modality for olfactory neuroblastoma, *Acta Neurochir.* 147 (2005) 595–602.
- [8] A. Rinaldo, A. Ferlito, A.R. Shaha, et al., Esthesioneuroblastoma and several lymph node metastases: clinical therapeutic implications, *Acta Otolaryngol.* 122 (2002) 215–221.
- [9] B.W. Eden, R.F. Debo, J.M. Lerner, et al., ENB: long term outcome and pattern of failure the University of Virginia experience, *Cancer* 73 (1994) 2556–2562.
- [10] V.A. Resto, D.W. Eisele, A. Forastiere, M. Zahurak, D.J. Lee, W.H. Westra, ENB: the Johns Hopkins experience, *Head Neck* 22 (2000) 550–558.
- [11] H.D. Klepin, K.P. McMullen, G.J. Lesser, Esthesioneuroblastoma, *Curr. Treat. Options Oncol.* 6 (2005) 509–518.
- [12] R. Mori, H. Sakai, M. Kato, T. Hida, M. Nakajima, T. Fukuda, Olfactory neuroblastoma with spinal metastasis: case report, *No Shinkei Geka* 35 (2007) 503–508.
- [13] A.J. Rao, S.H. Gultekin, E.A. Neuwelt, H.R. Cintron-Colon, B.T. Ragel, Late occurrence of drop metastasis to the spine in a case of esthesioneuroblastoma, *J. Neurosurg. Spine* 15 (2011) 571–575.
- [14] L. Zhang, M. Zhang, J. Qi, et al., Management of intracranial invasive olfactory neuroblastoma, *Chin. Med. J.* 120 (2007) 224–227.

Open Access

This article is published Open Access at [sciencedirect.com](https://www.sciencedirect.com). It is distributed under the [IJSCR Supplemental terms and conditions](#), which permits unrestricted non commercial use, distribution, and reproduction in any medium, provided the original authors and source are credited.