

# Is epineurectomy necessary in the surgical management of carpal tunnel syndrome?

U Tiftikci, S Serbest

Department of Orthopaedics and Traumatology, Kirikkale University Medical Faculty, Yahsihan 71100, Kirikkale, Turkey

## Abstract

**Background:** In this study, it was aimed to determine whether median nerve epineurectomy is beneficial in the surgical management of carpal tunnel syndrome (CTS).

**Materials and Methods:** The study enrolled 72 patients including 34 patients without epineurectomy (Group A) and 38 patients with epineurectomy (Group B). Surgery was performed in patients with severe electrodiagnostic CTS findings, CTS duration >1 year and flattening along with hypervascularization in median nerve. All patients were assessed by visual analog scale, two-point discrimination test as well as subjective and objective findings at baseline and on the months 1, 3, and 6 after surgery.

**Results:** The mean age was 58.3 years (42–75 years) in 38 patients who underwent an epineurectomy, whereas it was 61.5 years (41–82 years) in 34 patients who did not have an epineurectomy. The groups were similar with regard to age, gender, duration of symptoms, and preoperative physical findings. Mean visual analog scale (VAS) scores were 1.7 in Group A and 1.8 in Group B. Again, these differences were not significant, on physical examination, the average two-point discrimination in the distribution of the median nerve was 4.9 mm (range: 3–11 mm) in Group A and 5.3 mm (range: 3–10 mm) in Group B. In postoperative evaluations, there was a better improvement in visual analog scale scores, two-point discrimination test and subjective symptoms including dysesthesia, pain and nocturnal pain within first 3 months; however, there was no marked difference in objective and subjective findings on the 6<sup>th</sup> month. No complication or recurrence was observed.

**Conclusion:** We believe that median nerve epineurectomy is unnecessary in the surgical management of primary CTS since it has no influence on the midterm outcomes.

**Key words:** Carpal tunnel syndrome, epineurectomy decompression, median nerve, surgical

**Date of Acceptance:** 29-Apr-2016

## Introduction

Carpal tunnel syndrome (CTS) is the most commonly seen entrapment neuropathy.<sup>[1]</sup> It occurs due to acute or

chronic compression of the median nerve while passing through the carpal tunnel. It is assumed that increased pressure in the carpal tunnel results in chronic ischemia in the median nerve and subsequent demyelination;<sup>[2,3]</sup> however, the pathophysiology of the underlying factors causing the increased pressure is unclear.<sup>[4]</sup> A number of authors have suggested that, in addition to operative release of the transverse carpal ligament, operative treatment should include adjuvant manipulation of the median nerve.

### Address for correspondence:

Dr. U Tiftikci,  
Department of Orthopaedics and Traumatology,  
Kirikkale University Medical Faculty, Kirikkale University Campus,  
Ankara Road, Yahsihan 71100, Kirikkale, Turkey.  
E-mail: ugurtiftkci@gmail.com

### Access this article online

#### Quick Response Code:



**Website:** www.njcponline.com

**DOI:** 10.4103/1119-3077.187312

This is an open access article distributed under the terms of the Creative Commons Attribution-NonCommercial-ShareAlike 3.0 License, which allows others to remix, tweak, and build upon the work non-commercially, as long as the author is credited and the new creations are licensed under the identical terms.

**For reprints contact:** reprints@medknow.com

**How to cite this article:** Tiftikci U, Serbest S. Is epineurectomy necessary in the surgical management of carpal tunnel syndrome?. *Niger J Clin Pract* 2017;20:211-4.

Surgical release of the tunnel reduces pressure, allows for restoration of the intraneuronal blood flow and physiological function, and is the treatment of choice in persistent/progressive cases.<sup>[3]</sup> Open-field and endoscopic techniques do not seem to differ in efficacy and patient satisfaction.<sup>[4]</sup> However, the open-field approach allows for manipulations that could additionally improve the outcomes. Long-lasting nerve compression may result in fibrotic changes generating further mechanical pressure and narrowing of the nerve. In such cases, longitudinal epineurotomy of the nerve has been suggested as an option that could convey a greater pressure release, a more prominent nerve volume recovery and better outcomes.<sup>[5-7]</sup> The purpose of this study was to evaluate the effect of epineurotomy and without epineurotomy of the median nerve on the outcome of operative treatment of median nerve compression in the carpal canal.

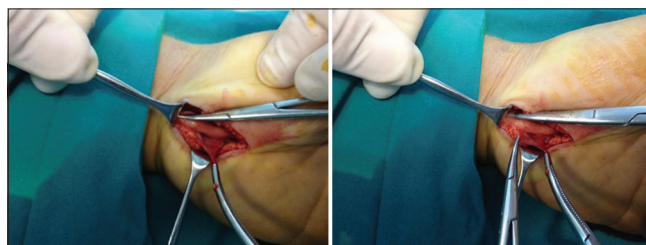
## Materials and Methods

All patients requiring operative treatment for CTS between January 2012 and January 2014 were enrolled in this study after they had given informed consent in Beypazarı State Hospital. All patients were retrospectively evaluated. Local ethical approval was gained (Ethical Committee of Kırıkkale University, Kırıkkale). The study included 72 patients, who were randomized into two groups: Group A had a release of the transverse carpal ligament alone, and Group B had a release and adjuvant epineurotomy of the median nerve. Surgery was performed in patients with severe electrodiagnostic CTS findings, CTS duration > 1 year and flattening along with hypervascularization in the median nerve. All surgical interventions were performed by one surgeon. In all patients, open CTS release was performed via a mini palmar incision with a tourniquet under regional anesthesia. During surgery, compression of the transverse carpal ligament on the median nerve and morphology, color, and vascularization of the median nerve outside of and within the tunnel were explored [Figure 1]. Then, the motor branch of the median nerve was released. Patients < 40 years of age, those with polyneuropathy, sudeck atrophy, rheumatoid arthritis, and those with a history of previous fractures in the wrist were excluded from the study. The patients were assessed at baseline and on the months 1, 2, 6, and 12 by subjective symptoms (pain, nocturnal pain, dysesthesia, and paresthesia) and physical examination findings (thenar atrophy, visual analog scale [VAS] score, two-point discrimination, Tinnel test, and Phalen maneuver). The classification of two-point-discrimination values advocated by the American Society for Surgery of the hand was used: Normal (0–6 mm), fair (7–10 mm), poor (11–15 mm), and protective sensation (> 15 mm). All statistical analyses were performed using SPSS version 16.0 software (SPSS Inc., Chicago, IL, USA). The data were analyzed statistically by an independent examiner, using Chi-square and *t*-tests.  $P < 0.05$  were accepted as statistically significant.

## Results

The mean age was 58.3 years (42–75 years) in 38 patients who underwent an epineurectomy, whereas it was 61.5 years (41–82 years) in 34 patients who did not have an epineurectomy. The groups were similar with regard to age, gender, duration of symptoms, and preoperative physical findings. The demographic characteristics of the patients are presented in Table 1. Subjective symptoms, including dysesthesia, pain and nocturnal pain disappeared rapidly during the postoperative period. Subjective symptoms, the 1<sup>st</sup> month after surgery, were found to be better in patients who had an epineurectomy when compared to those without an epineurectomy; however, no significant difference was detected between groups after the 1<sup>st</sup> month [Table 2,  $P > 0.05$ ]. Muscular atrophy was found to be less in the epineurectomy group than in the nonepineurectomy group in the 3<sup>rd</sup> month; however, no significant difference was detected between groups in the 6<sup>th</sup> month and beyond [Table 2,  $P > 0.05$ ]. On physical examination, the average two-point discrimination in the distribution of the median nerve was 4.9 mm (range: 3–11 mm) in Group A and 5.3 mm (range: 3–10 mm) in Group B. Two-point discrimination assessments were found to be better in patients who had an epineurectomy when compared to those without an epineurectomy in the 3<sup>rd</sup> month; however, no significant difference was found between groups after the 3<sup>rd</sup> month [Table 2,  $P > 0.05$ ]. Mean VAS scores were 1.7 in Group A and 1.8 in Group B. Again, these differences were not significant [Table 2,  $P > 0.05$ ].

No significant difference was found in the Tinnel's test and Phalen's maneuver between groups [Table 2,  $P > 0.05$ ]. No



**Figure 1:** Epineurectomy was performed in those with vascularization and severe flattening

**Table 1: Demographical characteristics of the patients**

	Group A (epineurectomy), (n=38)	Group B (no epineurectomy), (n=34)
Mean age (year)	58.3 (42-75)	61.5 (41-81)
Gender		
Male	18	15
Female	20	19
Side		
Right	29	27
Left	9	7

**Table 2: Clinical signs and findings in Groups A and B, preoperatively, 1 month, 3 months and 6 months postoperatively**

	Group A (epineurectomy) (n=38)				Group B (no epineurectomy) (n=34)			
	Preoperative	Postoperative (months)			Preoperative	Postoperative (months)		
		1	3	6		1	3	6
Pain (nocturnal pain)	n=38	n=2			n=34	n=4	n=2	
Hypoesthesia (hipoestezi)	n=38	n=6			n=34	n=8	n=2	n=1
Muscle atrophy (thenar atrophy)	n=36	n=31	n=17	n=7	n=32	n=27	n=19	n=8
Two-point discrimination	N (n=2)	N (n=10)	N (n=28)	N (n=34)	N (n=1)	N (n=4)	N (n=18)	N (n=28)
	F (n=8)	F (n=18)	F (n=8)	F (n=4)	F (n=10)	F (n=19)	F (n=10)	F (n=6)
	P (n=28)	P (n=10)	P (n=2)	P (n=0)	P (n=23)	P (n=11)	P (n=6)	P (n=0)
VAS (mean)	6.4	2.8	2.1	1.7	6.5	3.1	2.4	1.8
Phalen's maneuver	n=34	n=3	-	-	n=32	n=4	-	-
Tinel's test	n=37	n=24	n=8	n=2	n=34	n=26	n=12	n=2

N=Normal; F=Fair; P=Poor; VAS=Visual analog scale (1-10)

significant difference was detected in all subjective symptoms and clinical findings after the 3<sup>rd</sup> month [Table 2,  $P > 0.05$ ]. No recurrent CTS finding was detected in any patient.

## Discussion

Surgical management is indicated in CTS patient refractory to conservative therapy and in those with severe hypoesthesia, muscle atrophy, or loss of muscle strength. The goal of surgical management is to eliminate compression within the carpal tunnel by releasing the carpal ligament.<sup>[8,9]</sup> Outcomes are worse in patients presenting with muscle weakness and severe atrophy when compared to those without.<sup>[10]</sup> Surgery can be performed using open, endoscopic or minimally invasive techniques.<sup>[11]</sup> The open carpal tunnel release is the gold standard in CTS surgery; although, the endoscopic method has become more popular in recent years. Patients who undergo surgery via the endoscopic method return to daily life in a shorter time with less scar tissue formation; however, complication rates are higher when compared to open surgery.<sup>[12,13]</sup> In previous studies, complication rates, including incomplete decompression or tendon and neurovascular injuries, were found to be higher.<sup>[10]</sup> In addition to many methods, preserving the median nerve with the hypothenar fat flap is a simple and good alternative.<sup>[14]</sup> In this study, we released the median nerve via a 4–5 cm incision at the palmar region. Proximal and distal parts of the median nerve were explored and median nerve epineurectomy was made without causing iatrogenic injury to the median nerve and structures within the carpal tunnel.

In a study by Braun *et al.*, symptomatic recovery rate was found to be 100% in 17 patients who had surgery due to CTS.<sup>[15]</sup> In the studies, symptomatic recovery rate varied from 75% to 97.8%.<sup>[8,16]</sup> Median nerve compression via the release of transverse carpal ligament resulted in a clinical recovery in a vast majority of patients.<sup>[17]</sup> In all patients, subjective symptoms disappeared rapidly after surgery.

Epineurectomy didn't lead to a more rapid recovery in subjective symptoms.

In this study, a two-point discrimination test was used to assess sensorial functions. A two-point discrimination test can show recovery at the earliest postoperative period.<sup>[18]</sup> In this study, two-point discrimination assessments were found to be better in the 3<sup>rd</sup> month in patients who had an epineurectomy when compared to those without an epineurectomy; however, no significant difference was found between groups after the 3<sup>rd</sup> month [Table 2,  $P > 0.05$ ].

Electrophysiological evaluations are considered to be highly sensitive and specific in assessing nerve functions in patients with CTS.<sup>[19]</sup> In this study, CTS diagnosis was also confirmed by an electrophysiological test (EMG). Surgery was performed in patients with severe neuropathy on EMG. In some studies, there was no recovery in some EMG findings after surgery.<sup>[20]</sup> We did not perform EMG at the postoperative period in our study. Sonographic measurements of the median nerve can provide information about the severity of CTS. An electrodiagnostic test is an appropriate alternative as a first-line confirmatory test.<sup>[21,22]</sup> Magnetic resonance imaging (MRI) has the highest sensitivity and specificity in the diagnosis of CTS.<sup>[2,9]</sup> We think that pre- and post-operative sonography and MRI could be used in the follow-up for the patients with CTS in the future.

The most frequent causes of recurrence include incomplete resection of flexor retinaculum (1–11%), fibrous proliferation or scarring (0.5–1%), inflammatory flexor tenosynovitis (0.1–0.7%), reformation of flexor retinaculum, and entrapment of the palmar sensorial branch in the median nerve.<sup>[23-25]</sup> Epineurectomy and interfasciculotomy are recommended in the treatment of recurrent entrapment neuropathy.<sup>[26,27]</sup> Zieske *et al.* detected the insufficient release of flexor retinaculum and scar formation in median nerve tissues in all patients during recurrent CTS surgery.<sup>[28]</sup> In this study, no recurrence was detected at any patient.

In a previous study, it has been reported that epineurectomy is a safe and effective treatment in severe CTS.<sup>[29]</sup> However, in the study by Mackinnon *et al.*, it was reported that internal neurolysis is useless in models of primary CTS.<sup>[30]</sup> In addition, Lowry *et al.* concluded that internal neurolysis is found to be unsafe.<sup>[31]</sup>

In a study on the effectiveness of epineurectomy, Foulkes *et al.* assessed patients by using sensorial tests, motor tests, two-point discriminations tests, a Semmes-Weinstein monofilament test and grasping strength in months 6 and 12 after surgery. Authors reported complete recovery in sensorial tests at the postoperative period and found no significant difference between groups in months 6 and 12.<sup>[32]</sup> Leinberry *et al.* reported that epineurectomy had no advantage in long-term follow-up regarding objective findings and electrophysiological findings.<sup>[33]</sup> In our study, we found that the epineurectomy group achieved more rapid recovery in sensorial and subjective symptoms during the first 3 months. However, no significant difference was found in the assessment in the 6<sup>th</sup> month and beyond, as Foulkes *et al.* did.

## Conclusion

CTS is an important clinical problem. It has increasing incidence and its pathophysiology is still unclear. The physical findings and patient perceptions of outcome after surgery were similar. Furthermore, epineurectomy achieved earlier recovery in sensorial functions. It was concluded that the study data do not support the use of epineurotomy as an adjunctive procedure during carpal tunnel release.

**Financial support and sponsorship**  
Nil.

## Conflicts of interest

There are no conflicts of interest.

## References

- Katz JN, Simmons BP. Clinical practice. Carpal tunnel syndrome. *N Engl J Med* 2002;346:1807-12.
- Gelberman RH, Rydevik BL, Pess GM, Szabo RM, Lundborg G. Carpal tunnel syndrome. A scientific basis for clinical care. *Orthop Clin North Am* 1988;19:115-24.
- Diao E, Shao F, Liebenberg E, Rempel D, Lotz JC. Carpal tunnel pressure alters median nerve function in a dose-dependent manner: A rabbit model for carpal tunnel syndrome. *J Orthop Res* 2005;23:218-23.
- Uchiyama S, Itsubo T, Yasutomi T, Nakagawa H, Kamimura M, Kato H. Quantitative MRI of the wrist and nerve conduction studies in patients with idiopathic carpal tunnel syndrome. *J Neurol Neurosurg Psychiatry* 2005;76:1103-8.
- Muller M, Tsui D, Schnurr R, Biddulph-Deisroth L, Hard J, MacDermid JC. Effectiveness of hand therapy interventions in primary management of carpal tunnel syndrome: A systematic review. *J Hand Ther* 2004;17:210-28.
- Gupta SK, Benstead TJ. Symptoms experienced by patients with carpal tunnel syndrome. *Can J Neurol Sci* 1997;24:338-42.
- Atrosihi I, Johnsson R, Nouhan R, Crain G, McCabe SJ. Use of outcome

- instruments to compare workers' compensation and non-workers' compensation carpal tunnel syndrome. *J Hand Surg Am* 1997;22:882-8.
- Blend JD. Carpal tunnel syndrome. *Curr Opin Neurol* 2005;18:581-5.
- Bagatur AE, Zorer G, Oral B. The role of magnetic resonance imaging in carpal tunnel syndrome. Correlation of clinical, electrodiagnostic, and intraoperative findings and staging. *Acta Orthop Traumatol Turc* 2002;36:22-30.
- Schmelzer RE, Della Rocca GJ, Caplin DA. Endoscopic carpal tunnel release: A review of 753 cases in 486 patients. *Plast Reconstr Surg* 2006;117:177-85.
- Cokluk C, Senel A, Iyigün O, Celik F, Rakunt C. Open median nerve release using double mini skin incision in patients with carpal tunnel syndrome: Technique and clinical results. *Neurol Med Chir (Tokyo)* 2003;43:465-7.
- Agee JM, Peimer CA, Pyrek JD, Walsh WE. Endoscopic carpal tunnel release: A prospective study of complications and surgical experience. *J Hand Surg Am* 1995;20:165-71.
- Chow JC. Endoscopic release of the carpal ligament for carpal tunnel syndrome: 22-month clinical result. *Arthroscopy* 1990;6:288-96.
- Strickland JW, Idler RS, Lourie GM, Plancher KD. The hypothenar fat pad flap for management of recalcitrant carpal tunnel syndrome. *J Hand Surg Am* 1996;21:840-8.
- Braun RM, Davidson K, Doehr S. Provocative testing in the diagnosis of dynamic carpal tunnel syndrome. *J Hand Surg Am* 1989;14(2 Pt 1):195-7.
- Harris CM, Tanner E, Goldstein MN, Pettee DS. The surgical treatment of the carpal-tunnel syndrome correlated with preoperative nerve-conduction studies. *J Bone Joint Surg Am* 1979;61:93-8.
- Kulick RG. Carpal tunnel syndrome. *Orthop Clin North Am* 1996;27:345-54.
- Katz JN, Gelberman RH, Wright EA, Lew RA, Liang MH. Responsiveness of self-reported and objective measures of disease severity in carpal tunnel syndrome. *Med Care* 1994;32:1127-33.
- Gunnarsson LG, Amilon A, Hellstrand P, Leissner P, Philipson L. The diagnosis of carpal tunnel syndrome. Sensitivity and specificity of some clinical and electrophysiological tests. *J Hand Surg Br* 1997;22:34-7.
- Witt JC, Hentz JG, Stevens JC. Carpal tunnel syndrome with normal nerve conduction studies. *Muscle Nerve* 2004;29:515-22.
- Fowler JR, Gaughan JP, Ilyas AM. The sensitivity and specificity of ultrasound for the diagnosis of carpal tunnel syndrome: A meta-analysis. *Clin Orthop Relat Res* 2011;469:1089-94.
- Kim MK, Jeon HJ, Park SH, Park DS, Nam HS. Value of ultrasonography in the diagnosis of carpal tunnel syndrome: Correlation with electrophysiological abnormalities and clinical severity. *J Korean Neurosurg Soc* 2014;55:78-82.
- Steyers CM. Recurrent carpal tunnel syndrome. *Hand Clin* 2002;18:339-45.
- Bonél HM, Heuck A, Frei KA, Herrmann K, Scheidler J, Srivastav S, *et al.* Carpal tunnel syndrome: Assessment by turbo spin echo, spin echo, and magnetization transfer imaging applied in a low-field MR system. *J Comput Assist Tomogr* 2001;25:137-45.
- Lo SL, Raskin K, Lester H, Lester B. Carpal tunnel syndrome: A historical perspective. *Hand Clin* 2002;18:211-7, v.
- Jones NF, Ahn HC, Eo S. Revision surgery for persistent and recurrent carpal tunnel syndrome and for failed carpal tunnel release. *Plast Reconstr Surg* 2012;129:683-92.
- Zhang J, Cui Q, Dong Z, Wei H, Zhao L, Yang Z, *et al.* Clinical study on expansion of groove of ulnar nerve and interfascicular neurolysis in treating severe cubital tunnel syndrome. *Zhongguo Xiu Fu Chong Jian Wai Ke Za Zhi* 2008;22:1314-7.
- Zieske L, Ebersole GC, Davidge K, Fox I, Mackinnon SE. Revision carpal tunnel surgery: A 10-year review of intraoperative findings and outcomes. *J Hand Surg Am* 2013;38:1530-9.
- Rhoades CE, Mowery CA, Gelberman RH. Results of internal neurolysis of the median nerve for severe carpal-tunnel syndrome. *J Bone Joint Surg Am* 1985;67:253-6.
- Mackinnon SE, Dellon AL. Evaluation of microsurgical internal neurolysis in a primate median nerve model of chronic nerve compression. *J Hand Surg Am* 1988;13:345-51.
- Lowry WE Jr, Follender AB. Interfascicular neurolysis in the severe carpal tunnel syndrome. A prospective, randomized, double-blind, controlled study. *Clin Orthop Relat Res* 1988;227:251-4.
- Foulkes GD, Atkinson RE, Beuchel C, Doyle JR, Singer DI. Outcome following epineurotomy in carpal tunnel syndrome: A prospective, randomized clinical trial. *J Hand Surg Am* 1994;19:539-47.
- Leinberry CF, Hammond NL 3<sup>rd</sup>, Siegfried JW. The role of epineurotomy in the operative treatment of carpal tunnel syndrome. *J Bone Joint Surg Am* 1997;79:555-7.