

See discussions, stats, and author profiles for this publication at: <https://www.researchgate.net/publication/337711341>

Retention systems used in maxillofacial prostheses: A review

Article in *Nigerian Journal of Clinical Practice* · December 2019

DOI: 10.4103/njcp.njcp_92_19

CITATIONS

16

READS

1,457

3 authors, including:



Almira Ada Diken Türksayar
Biruni University

16 PUBLICATIONS 36 CITATIONS

[SEE PROFILE](#)



Ali Can Bulut
Ankara Yıldırım Beyazıt University

24 PUBLICATIONS 105 CITATIONS

[SEE PROFILE](#)

Some of the authors of this publication are also working on these related projects:



Baz Metal Alaşımlarından Yapılan İmplant Üstü Restorasyonların Kron Uyumlarının Araştırılması [View project](#)



Additive manufacturing in dentistry [View project](#)

Review Article

Retention Systems Used in Maxillofacial Prostheses: A Review

AA Diken Türksayar, SA Saglam, AC Bulut

Department of
Prosthodontics, Faculty of
Dentistry, University of
Kirikkale, Kirikkale, Turkey

Received:
12-Feb-2019;
Revision:
21-Mar-2019;
Accepted:
23-Apr-2019;
Published:
03-Dec-2019

ABSTRACT

Defects in the face area caused by trauma, accident, tumor or congenital defects are treated with special facial prostheses. Besides esthetics, the most common problem with these prostheses is the retention of prostheses. In the present article review, the methods used for the retention of prostheses from past to present were researched, and the advantages of adhesives and implants, which are the most commonly used current methods, were evaluated. Current techniques, new materials, treatment options, and implementation procedures are described. The success of maxillofacial prostheses in meeting the expectations of patients and dentist doctors is increasing day by day with the development of adhesive material science, the emergence of technical knowledge, and the development of implant technology. Increasing the retention provides both ease of use and acceptance by the patient. Therefore, the chosen method for retention has great importance in the long-term prognosis of the prosthesis.

KEYWORDS: *Adhesive, extraoral implants, facial prostheses, maxillofacial prostheses, maxillofacial prosthodontics, retention*

INTRODUCTION

Prosthetics are artificial materials that imitate an organ or an organ group lacking in an organism for functional or aesthetic purposes. Facial prostheses are also used in defects stemming from congenital reasons, trauma, accident or tumor, in the facial area. Facial defects are treated surgically or prosthetically to meet the necessary functions, to provide a more aesthetic appearance, to maintain soft and hard tissue continuity, and to compensate for the tissue loss that may have a negative psychological effect on the patient.^[1-3]

During archeological excavations, remnants of jaw facial prosthesis were found in many different civilizations, but the French surgeon Ambroise Pare prepared the first facial prosthesis according to official records. In his book, he offers a great amount of information about the use and construction of facial prosthesis and describes many examples of different designs, materials, and facial prostheses.^[4,5] Developments in facial dentures were accelerated during World War I. Until the 1930s, the most widely used vulcanite was replaced with plastic, methyl methacrylate, glass, and silica.

The most important factors affecting the success of the maxillofacial prosthesis are retention and appearance. With the introduction of silicone for the facial prostheses in 1946, the success of prosthetics has increased both in terms of aesthetics and functionality.^[4,5] Nowadays, the retention of facial dentures is still a major problem, and different methods have been developed to cope with this issue.

SEARCH STRATEGY

In the present article review, scientific articles in the English language published in MEDLINE database until October 2016 are included. The following search terms and their combinations were used: “facial prostheses,” “maxillofacial prostheses,” “maxillofacial prosthodontics,” “adhesives,” “retention,” and “extraoral implants.” Additional information was obtained from relevant journals and textbooks.

Address for correspondence: Dr. AC Bulut,
Department of Prosthodontics, University of Kirikkale,
Faculty of Dentistry, Yenisehir Mahallesi Celebi Sokak No:1
Yahsihan, Kirikkale, Turkey.
E-mail: alicanbulut@outlook.com

This is an open access journal, and articles are distributed under the terms of the Creative Commons Attribution-NonCommercial-ShareAlike 4.0 License, which allows others to remix, tweak, and build upon the work non-commercially, as long as appropriate credit is given and the new creations are licensed under the identical terms.

For reprints contact: reprints@medknow.com

How to cite this article: Diken Türksayar AA, Saglam SA, Bulut AC. Retention systems used in maxillofacial prostheses: A review. Niger J Clin Pract 2019;22:1629-34.

Access this article online	
Quick Response Code:	Website: www.njcponline.com
	DOI: 10.4103/njcp.njcp_92_19

RETENTION

In the retention of facial prostheses, mechanical factors such as adhesions, crowns, and magnets as well as anatomic factors such as hard and soft tissue residue in trauma or post-surgery defect, concavities and protrusions in auricular or orbital region, zygoma support, and external auditory pathway have been utilized. After evaluating the adjacent anatomical tissues, various methods have been tested depending on the shape and size of the defect, the systemic condition, and age of the patient. The most commonly used retention methods include adhesives and implants.^[6-8]

ADHESIVES

Medical adhesives are more often classified according to their use; double-sided tape, glue, sprayers, pastes, and liquid systems are classified according to the silicone substrate.^[9] Latex-based pastes and surgical cement cause odors and remain on the surface of the skin and prosthesis as they are difficult to remove. For this reason, they are not highly preferred. Double-sided tape is the most highly preferred type of adhesive due to its ease of application, easy removal, and renewability. However, this kind of tape has certain disadvantages such as low flexibility and the need for frequent reassembly due to the loss of stickiness. The type of adhesive to be used with the maxillofacial elastomer and the cleaning solution should be carefully selected. Adhesives and solvents may adversely affect the physical and optical properties of the maxillofacial elastomers.^[8] The properties of ideal adhesive materials are described in Table 1.^[8]

There are some disadvantages to using an adhesive. It can damage both the prosthesis surface and the skin during insertion and removal. They do not provide sufficient adhesion against gravity, sweating, and tissue movement. If adhesive systems used for a long time, they may cause contact dermatitis. The use of adhesives may cause a change in the color of the prosthesis. Adhesives can disrupt the prosthesis structure and abrade

the edges. All adhesive systems are inadequate to ensure the rigid fixation of facial prostheses. Thicker prosthetic margins are used in order to facilitate the application of adhesives increase both microorganism involvement and aesthetic damage due to the non-resetting of the marginal passage.^[6-13]

Types of adhesive materials

Facial prostheses are often used in adhesive systems such as acrylic resins, silicone adhesives, and pressure sensitive tapes. Acrylic resin adhesives are soluble in water and gain elasticity when water evaporates. These adhesives can be easily removed from all prosthetic materials except polyurethane. Hydrobond (Epithane 3) is an example of this system. Silicone adhesives are extremely resistant to moisture and absorb very little water. They are not affected by chemicals, oil, or sunlight. Room temperature vulcanizing (RTV) silicone adhesives are low molecular weight polymers ending with hydroxy. An example of this group is secure medical adhesive (SMA). Pressure sensitive tapes are another option. A market example of this type is 3M double-sided tape. These systems applied with finger pressure may be recommended for use with liquid adhesives to increase the bonding strength.^[8-14]

Tissue protectors may be used to reduce the side effects of adhesives and to increase the bonding strength. In a detailed study on Epithane 3 and SMA by Kint-amnuay and colleagues, it was reported that secure medical adhesives are more retentive than Epithane 3, the use of tissue protectors on both materials has a positive effect on binding, the effect of adhesives is reduced in about 8 h, and the combination of both materials increases the connectivity (when SMA was applied on the skin, on the E3 silicone prosthesis), and that repeated applications of SMA had a positive effect on the connection.^[7]

Adhesive use in facial prostheses is easily accepted by patients and families because of its cost-effectiveness, non-invasiveness, and lack of aggressive side effects. Patients should be told to remove the prosthesis once a day to clear the surrounding tissue. It is highly recommended that the prosthesis be removed before resting in order to decrease the risk of skin contact disorders and to allow the tissues to rest.^[15]

IMPLANT

The most significant problem in the placement of facial implants is insufficient bone volume. Bone thickness in the temporal and supraorbital regions, suitable places for implant placement, ranges between 2.5 and 6 mm; hence, extraoral implants were designed to be 3–4 mm long and 5 mm in diameter, unlike intraoral implants. However, longer implants may also be used where

Table 1: Ideal adhesive material properties

The material should be biocompatible, non-toxic, and should not cause irritation on the tissue	The adhesive should keep the prosthesis in place for at least 12 h a day
The material should be odorless and moisture-resistant	The prosthesis should not damage tissue during removal from the skin
The dried adhesive must have a porous structure to allow for the passage of secretions	The sticker should be presented in a portable package
The adhesive should be easy to apply	The material should dry quickly

bone mass, such as nasal and orbital bone, is adequate. Extraoral implants have wing extensions and holes to provide mechanical stability and retention.^[9-16] It has been reported that these wings may cause bacterial involvement, debris accumulation, and infection.^[17,18]

Originally, craniofacial implants were introduced by Nobel Pharma, then transferred to Nobel Biocare, Göteborg in the Swedish market. This implant system and the Branemarkosseointegration system were developed from the oral concept using the same drill and implant surface. This implant system has remained relatively unchanged for years. Today, they are all placed mainly on the original implant, with several other systems available using the other surfaces of the fixture (Conexao®, Otorix®, Straumann, ITI). Today, there are also original untreated surfaces.^[19]

Implant application area

Craniofacial osseointegration planning is multifaceted. Computed tomography (CT) scans or other radiographic evaluations of bone mass are important. CT scan records can be analyzed and used in the planning of an implant. Implant planning software allows for the assessment of bone volume and density.^[20]

Asar *et al.* interpreted the classification of the bone regions in which the facial implants made by Jensen and his colleagues^[21] could be placed as follows [Figure 1]:

a-bone regions: In these regions, which permit the use of dental implants as well as zygomatic implants, bone volume is 6 mm or more. The anterior aspect of maxillary, zygomatic arch, and zygoma are examples of these regions. These bone regions on the facial skeleton include the anterior maxillary, zygoma, and/or zygomatic arthritis. The lateral aspect of the periorbital bone was found to be mostly 6 or 7 mm in length.

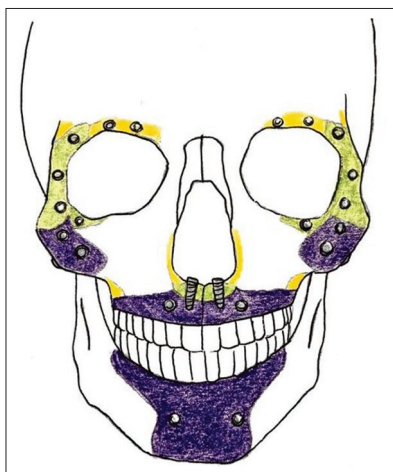


Figure 1: Implant placement of the facial prosthesis frontal view

b-bone zones: In 4-5 mm bone volumes, 4 mm craniofacial implants can be used. These bone regions are present in the greater part of the superior, lateral, and inferolateral orbital margins, and especially the mastoid margin of the zygoma and temporal bone.

c-bone zones: The margin areas are 3 mm or less in bone mass. Some parts of the temporal bone in the facial area are the pyriform edge, infraorbital margin, nasal bone, and zygomatic arch. They require the use of craniofacial implants of 3 mm or less.^[16]

Implants applied to maxillofacial prostheses should be placed according to some principles. In order to prevent any damage, the skin layers should be surgically thinned and this operation should be done 10 mm away from the abutments. The implants should be 1 cm apart from each other for hygienic purposes. The bars fixed between abutments should follow natural facial features and be designed to provide the necessary hygiene. Implants should be at least 7 mm away from the hairy scalp. If this is not possible, skin grafting should be performed.^[6,22,23]

Implant systems used in extraoral prostheses

Bar systems

In bar systems, there is a bar that connects the implants to each other and a retentive lock that sits in this bar. The bars used in these systems are gold alloys and are about 2 mm in diameter. These retention systems are especially preferred for auricular prosthesis. The construction technique of the bar systems is very fragile. Passive alignment between the bar and the implants should be ensured in order to achieve the force distribution. To hold the clips in the prosthesis, an acrylic plate is prepared. Leaving a distance of about 1.5 mm between the bar and the tissue is important to allow for the easy cleansing of this area. Bar systems, unlike magnet systems, do not rust when they come in contact with body fluids. However, it is difficult to clean the underside of the bar due to the pedestal portion of the prosthesis.^[16,18,24,25] Bar systems take up more space in the prosthesis; therefore, the silicone structure should be thick enough to hide the reflection of the grayish color of the substrate and prevent the silicone material from breaking.^[26]

Magnetic systems

Magnet systems consist of individual implant supports that do not require superstructure preparation and are not interconnected. These systems are used in the retention of a facial prosthesis, in regions with high muscle activity adjacent to the prosthesis; in cases where the ability to use the hand is inadequate, the bone is thin, and the implant is desired to reduce the forces applied to

the bone.^[16] Magnetic retention systems are preferred in orbital defects, even when the risk of corrosion is taken into account because the prostheses used by the magnet systems are easy to be placed by the patient.^[18]

Facial implant application principles

Auricular area

The location of the implants in the temporal region is very important for the aesthetics of auricular prosthesis. Implants should be placed at the anti-helix level because retention systems must remain within the limits of the auricular prosthesis. Two implants placed in the temporal region may provide retention of the auricular prosthesis. In such cases, the two implants should be 15 mm apart from each other and each of them should be approximately 18 mm away from the center of the auricular duct. An implant should be placed at 9 o'clock and 11 o'clock positions for the right ear and at 1 o'clock and 3 o'clock positions for the left ear [Figure 2]. These traditional suggestions should be regarded as a constant principle. The exact positions of the implants should be determined using a wax sample and a surgical stent.^[14,16] The advantages and disadvantages of implants used in the auricular area can be summarized in Table 2.^[27]

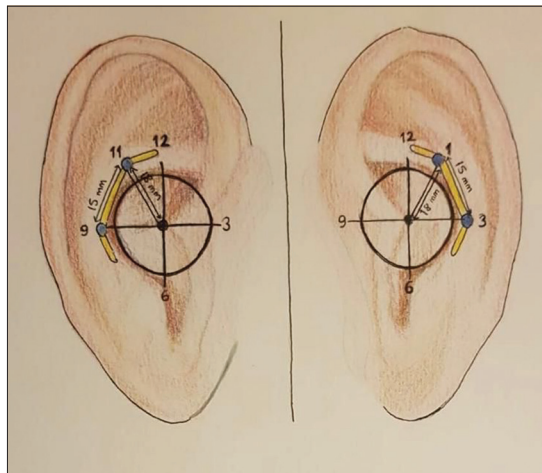


Figure 2: Implant placements and bar application in auricular prosthesis

Table 2: The advantages and disadvantages of implants used in the auricular area

Advantages	Disadvantages
Very good for complex anatomical structures	Not suitable for moving parts of the face
Optimal camouflage	Foreign body feeling
No donor site morbidity	Must be removed while sleeping
Predictable cosmetic results	Color matching is difficult
Simple and fast technique	Needs to be renewed every 2-3 years
Early detection of tumor recurrence	Needs to be frequently cleaned

Despite the complexity of preoperative planning for the placement of osseointegrated prosthetic implants in auricular site defects, technical simplicity and cosmetic results are superior to traditional reconstructive procedures. These implants can be combined with osseointegrated hearing implants, although the planning and surgical steps become more complex when tissue loss is accompanied by hearing loss.^[28]

Orbital and ocular area

Compared with auricular prostheses, in the orbital region, the disadvantage of using adhesives is more; therefore, implants are also needed frequently. Depending on the secretions, the humidity generated under the prosthesis lowers patient satisfaction, especially when adhesives are used. The easy removal of the implant prosthesis helps to protect the orbital area from airing and touching.^[18]

Ocular prostheses

Although ocular implants today are diversified with the use of different materials, there are two basic groups of structures:

- Integrated (porous) implants: These implants allow fibrous tissue formation through porous structures. Integral implants, usually fabricated in spheres of different sizes and containing hydroxyapatite, move the tissue bed. Thus, the prosthesis that is to be placed on the implant also provides movement
- Non-integrated implants: These implants have no direct mechanical connection to the eye prosthesis. They are usually covered with a mesh-like material that allows the rectum muscles to bind.^[29]

Orbital prostheses

Because of the osseous anatomy of the orbital bone, orbital implants must be placed radially into the orbital boundary to provide adequate bone thickness for retention. Due to the increase in bone thickness and quality, implant placement in the lateral walls is usually recommended. In most cases, the medial border is problematic due to the increased anatomical complexity resulting from the lacrimal fossa and the lack of adequate bone. Unfortunately, this means that the desired axial loading of the implants is impossible in this region, which is a less favorable biomechanical condition compared to other craniofacial implant sites. For this reason, it may be necessary to consider a rigorous technique for staged bone grafting for a successful implant-supported orbital prosthesis. Usually, three to four implants are placed in the lateral wall to provide denture stability. For prosthesis aesthetics, implants should be placed on the upper or side of the orbital wall so that it can be camouflaged by the prosthesis.^[29]

Nasal prostheses

Implant placement in the nasal region may be

technically challenging due to insufficient bone quality and thickness. The complex anatomy of the nasal cavity and adjacent tissues affects the success of the implant surgeon in this region. Especially in patients who have received radiotherapy, this situation may be even more challenging. Mean bone measurements up to the perineal area, pyriform edge (2.9 mm), glabella (12.8 mm), and the anterior aspect of the nasal fossa (10.2 mm) showed that optimal bone capacity was limited to the anterior nasal fossa.^[21] The implants are usually placed in a triangular plane. The nasal floor and the frontal face of the maxilla are ideal areas for implant placement. Occasionally, implant placement on glabella is considered, but studies have shown that implant success in this region is low. The implants should be inserted gently into the nasal cavity to reach adequate bone. Adequate prosthesis thickness should be provided as in the orbital reconstruction.^[30,31]

OTHER RETENTION METHODS

In cases where an implant or adhesive systems cannot be used for a variety of reasons, eyeglasses can be used effectively, especially for nasal prostheses. When eyeglasses have thick, opaque frames, they help to camouflage the prosthetic margins. A commonly used method is the permanent attachment of prostheses, in cases including mid-field face defects, to the glasses. In this case, however, the patient's prosthesis is removed when the eyeglasses are removed, an unacceptable situation. To overcome this problem, sensitive adhesive attachments may be placing on the frame of eyeglasses.^[32]

CONCLUSION

Facial prostheses increase the quality of life of the patients with congenital defects or trauma, accident or tumor caused defects in the facial region when plastic surgery is insufficient or impossible. Increasing the prostheses retention provides both ease of use and acceptance by the patient. The condition of the adjacent tissues, the patient's expectations, and the financial situation give the dentist the idea of which retention system to use. Although adhesive retention systems develop day by day, it is obvious that implant systems provide much higher retention. According to the area where the facial prosthesis will be applied, the presence of different implant systems with bar holders or magnetic holders provides maximum retention and comfort of use.

Financial support and sponsorship

Nil.

Conflicts of interest

There are no conflicts of interest.

REFERENCES

1. Taylor TD. Clinical Maxillofacial Prosthetics. Illinois: Quintessence Publishing Co. Inc.; 2000.
2. Johnson F, Cannavina G, Brook I, Watson J. Facial prosthetics: Techniques used in the retention of prostheses following ablative cancer surgery or trauma and for congenital defects. *Eur J Prosthodont Restor Dent* 2000;8:5-9.
3. Goulart DR, Sigua-Rodriguez EA, Alvarez-Pinzon N, Fernandes AUR, Queiroz E. Quality of life of patients with facial prostheses. *Rev Fac Odontol Univ Antioq* 2017;29:131-47.
4. Kurtoglu C, Uzel I. Facial prosthetic materials: Past to Present. *CÜ Diş Hek Fak Derg* 2008;11:140-4.
5. Controy B, Hulterstorm A. The history and development of facial prosthetics. *Dent Tech* 1978;3:11-2.
6. Mekayarajananonth T, LoCascio SJ, Winkler S, Salinas TJ, Guerra LR. Alternative retention for an implant-retained auricular prosthesis. *J Oral Implantol* 2002;28:117-21.
7. Kiat-amnuay S, Gettleman L, Khan Z, Goldsmith LJ. Effect of adhesive retention on maxillofacial prostheses. Part I: Skin dressings and solvent removers. *J Prosthet Dent* 2000;84:335-40.
8. Beumer J, Mark TM, Salvatore JE. Maxillofacial Rehabilitation: Prosthodontic and Surgical Management of Cancer-Related, Acquired, and Congenital Defects of the Head and Neck. 3rd ed. HanoverPark, IL: Quintessence Pub.; 2011.
9. Karatas MÖ, Özdemir D, Azak AN, Evlioglu G. Adhesives in maxillofacial prosthesis. *İÜ Diş Hek Fak Derg* 2005;39:1-2.
10. Cobein MV, Coto NP, Crivello Junior O, Lemos JB, Vieira LM, Pimentel ML, *et al.* Retention systems for extraoral maxillofacial prosthetic implants: A critical review. *Br J Oral Maxillofac Surg* 2017;55:763-9.
11. Kiat-Amnuay S, Gettleman L, Khan Z, Goldsmith LJ. Effect of adhesive retention of maxillofacial prostheses. Part 2: Time and reapplication effects. *J Prosthet Dent* 2001;85:438-41.
12. Kiat-Amnuay S, Gettleman L, Goldsmith LJ. Effect of multi-adhesive layering on retention of extraoral maxillofacial silicone prostheses *in vivo*. *J Prosthet Dent* 2004;92:294-8.
13. Pekkan G, Tuna SH, Oghan F. Extraoral prostheses using extraoral implants. *Int J Oral Maxillofac Surg* 2011;40:378-83.
14. McKinstry RE, Fundamentals of Facial Prosthetics. 1st ed. Arlington: ABI Professional Publications; 1995.
15. Negahdari R, Pournasrollah A, Bohlouli S, SighariDeljavan A. Rehabilitation of a partial nasal defect with facial prosthesis: A case report. *J Dent Res Dent Clin Dent Prospects* 2014;8:256-9.
16. Asar NV, Yazıcıoğlu H, Yaluğ S, Yılmaz C. Implant supported facial prostheses. *GÜ Diş Hek Fak Derg* 2008;25:41-9.
17. Westin T, Tjellstrom A, Hammerlid E, Bergstrom K, Rangert B. Long-term study of quality and safety of osseointegration for the retention of auricular prostheses. *Otolaryngol Head Neck Surg* 1999;121:133-43.
18. Pehlivan N, KarakocaNemli S, Karacaer Ö. Maxillofacial prosthesis and extraoral implants. *Gazi Üni Diş Hek Fak Der* 2011;28:123-9.
19. Granstöröm G. Craniofacial osseointegration. *Oral Diseases* 2007;13:261-9.
20. Wolfaardt J, Gehl G, Farmand M, Wilkes G. Indications and methods of care for aspects of extraoralosseointegration. *Int. J. Oral Maxillofac Surg* 2003;32:124-31.
21. Jensen OT, Brown C, Blacker J. Nasofacial prostheses supported by osseointegrated implants. *Int J Oral Maxillofac Implants* 1992;7:203-11.
22. Jacobson M, Tjellstrom A, Fine L, Jansson K. An evaluation of auricular prosthesis using osseointegrated implants. *Clin*

- Otolaryngol Allied Sci 1992;17:482-6.
23. Atay A. Overview of Maxillofacial Prosthetics. New York: Nova Science Publishers; 2013.
 24. Nishimura RD, Roumanas E, Moy PK, Sugai T, Freymiller EG. Osseointegrated implants and orbital defects: U.C.L.A. experience. *J Prosthet Dent* 1998;79:304-9.
 25. Arcuri MR, Rubenstein JT. Facial implants. *Dent Clin North Am* 1998;42:161-75.
 26. Visser A, Vechiato Filho AJ, Raghoebar GM, Brandao TB. A simple technique for placing extraoral implants at an optimal position in orbital defects. *J Prosthodont* 2016;27:784-5.
 27. Federspil PA. The role of auricular prostheses (epitheses) in ear reconstruction. *Facial Plast Surg* 2015;31:626-32.
 28. Rocke DJ, Tucci DL, Marcus J, McClennen J, Kaylie D. Osseointegrated implants for auricular defects: Operative techniques and complication management. *Otol Neurotol* 2014;35:1609-14.
 29. Yeshwante B, Choudhary N, Baig N. Ocular prosthesis-a review. *J Dent Med Sci* 2015;14:63-7.
 30. Miles BA, Sinn DP, Gion GG. Experience with cranial implant-based prosthetic reconstruction. *J Craniofac Surg* 2006;17:889-97.
 31. Flood TR, Russell K. Reconstruction of nasal defects with implant-retained nasal prostheses. *Br J Oral Maxillofac Surg* 1998;36:341-5.
 32. Karakoca S, Ersu B. Attaching a midfacial prosthesis to eyeglass frames using a precision attachment. *J Prosthet Dent* 2009;102:264-5.