

## A Rare Case of “Double Teeth” in Permanent Dentition

### Daimi Dişlenmede Nadir Görülen Bir İkiz Diş Olgusu

Merve MUTLUAY,<sup>a</sup>  
Işıl SAROĞLU SÖNMEZ,<sup>b</sup>  
Volkan ARIKAN<sup>a</sup>

<sup>a</sup>Department of Pediatric Dentistry,  
Kırıkkale University Faculty of Dentistry,  
Kırıkkale

<sup>b</sup>Department of Pediatric Dentistry,  
Adnan Menderes University  
Faculty of Dentistry,  
Aydın

Geliş Tarihi/Received: 12.12.2016  
Kabul Tarihi/Accepted: 27.02.2017

Yazışma Adresi/Correspondence:  
Merve MUTLUAY  
Kırıkkale University Faculty of Dentistry,  
Department of Pediatric Dentistry,  
Kırıkkale,  
TURKEY/TÜRKİYE  
mervkrts@hotmail.com

**ABSTRACT** It is difficult to establish a definite differential diagnosis between fused teeth and bigeminal teeth. For this reason, the term “double teeth” has been coined to refer to developmental abnormalities such as fusion and gemination. Double teeth anomalies influence tooth alignment and interdigitation, arch symmetry, appearance, and associated periodontal tissues. After a careful diagnosis, it is important to make appropriate treatment management and regular follow-up. In this paper, we present a rare case of double teeth in a mandibular permanent premolar with no clinical manifestation. Reported case is the first reported double teeth in permanent dentition which cannot be observed clinically. Our experience implies the importance of radiographic examination in diagnosing dental anomalies.

**Keywords:** Cone-beam computed tomography; tooth abnormalities

**ÖZET** Füzyon ve bigeminal dişler arasında kesin bir ayırım yapmak oldukça zordur. Bu sebeple, "İkiz diş" terimi füzyon, geminasyon gibi gelişimsel anomalileri tanımlamak için kullanılmaktadır. İkiz diş anomalisi; diş dizilimi ve ilişkilerini, ark simetrisini, görünümü ve periodontal dokuları etkilemektedir. Dikkatli bir muayeneyi takiben, uygun bir tedavi planı ve düzenli kontrollerin yapılması önemlidir. Bu makalede, alt daimi premolar dişte klinik olarak gözlemlenmeyen nadir bir ikiz diş anomalisi sunulmuştur. Sunulan olgu, sürekli dentisyonda klinik olarak gözlemlenmeyen ilk ikiz diş olgusudur. Gözlemlerimiz, dental anomalilerin teşhisinde dikkatli bir radyografik muayenenin önemini vurgulamaktadır.

**Anahtar Kelimeler:** Konik ışınlı bilgisayarlı tomografi; diş anomalileri

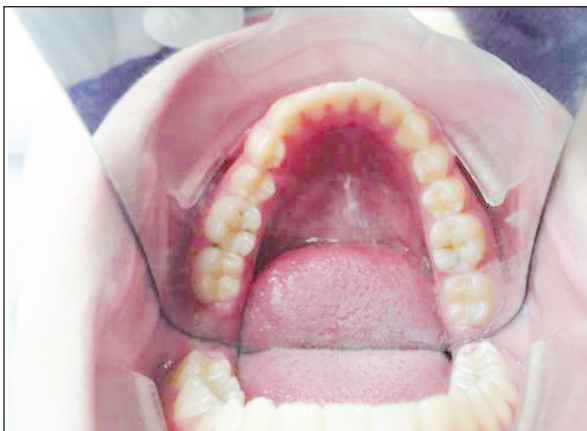Fusion and gemination are irregularities in tooth development.<sup>1</sup> They result from alterations in the embryologic development of the teeth. As the clinicians are not able to directly visualize the embryological course, the exact etiology and pathogenesis of these defects are unknown.<sup>2</sup> It is difficult to establish a differential diagnosis between fused teeth and bigeminal teeth, particularly when they are associated with supernumerary teeth. For this reason, many authors prefer to use the term “double teeth” because of the uncertainty regarding the embryologic cause underlying the junction defect.<sup>3</sup>

Double teeth anomalies generally influence tooth alignment and interdigitation, arch symmetry, appearance, and associated periodontal tissues.<sup>4</sup> However, in this case report, we present a rare case of “double teeth” in a mandibular permanent premolar which was not observed clinically.

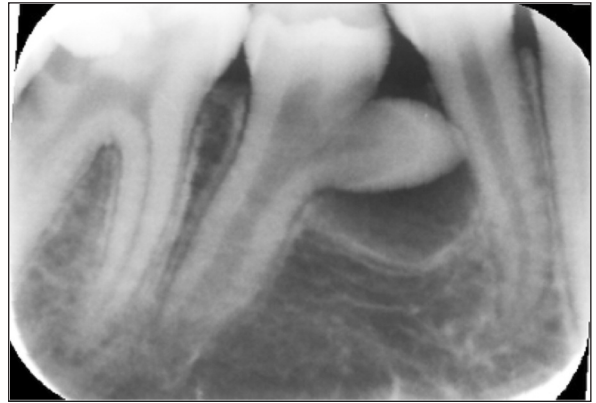
## CASE REPORT

A 12-year-old female patient complaining of spontaneous pain in her right permanent mandibular first molar referred to our clinic. Her personal and familial medical history was noncontributory. Clinical and radiographic examination revealed a composite restoration with secondary decay in the right permanent mandibular first molar. The tooth responded negatively to electrical stimuli and was tender to percussion. All remaining permanent teeth were fully erupted and normal in size and morphology (Figure 1).

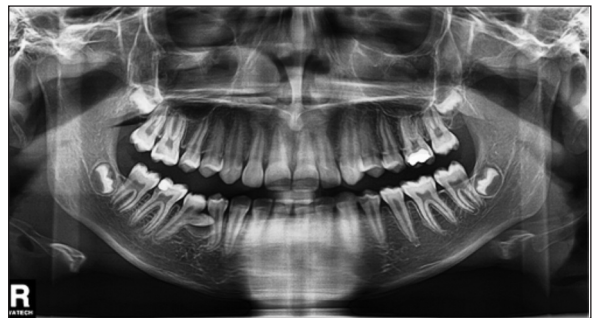
During radiographic evaluation of the right permanent mandibular first molar, double teeth abnormality which was not clinically observable was detected at the right permanent mandibular second premolar. It had two separate crowns with a deep oblique groove and only one root (Figure 2). The tooth was asymptomatic; no periapical radiolucency was associated with this tooth and the lamina dura was intact. Panoramic radiographic evaluation showed no other dental anomalies (Figure 3). To ascertain the correlation of double teeth with anatomical structures, a cone beam computed tomography (CBCT) scan was taken. CBCT image showed no relationship between the crowns of the right permanent mandibular first and second premolars (Figures 4 a-c). No invasive treatment was planned to the right permanent mandibular sec-



**FIGURE 1:** Clinical appearance showing all teeth in normal morphology and size.



**FIGURE 2:** Double teeth in the right permanent mandibular second premolar.



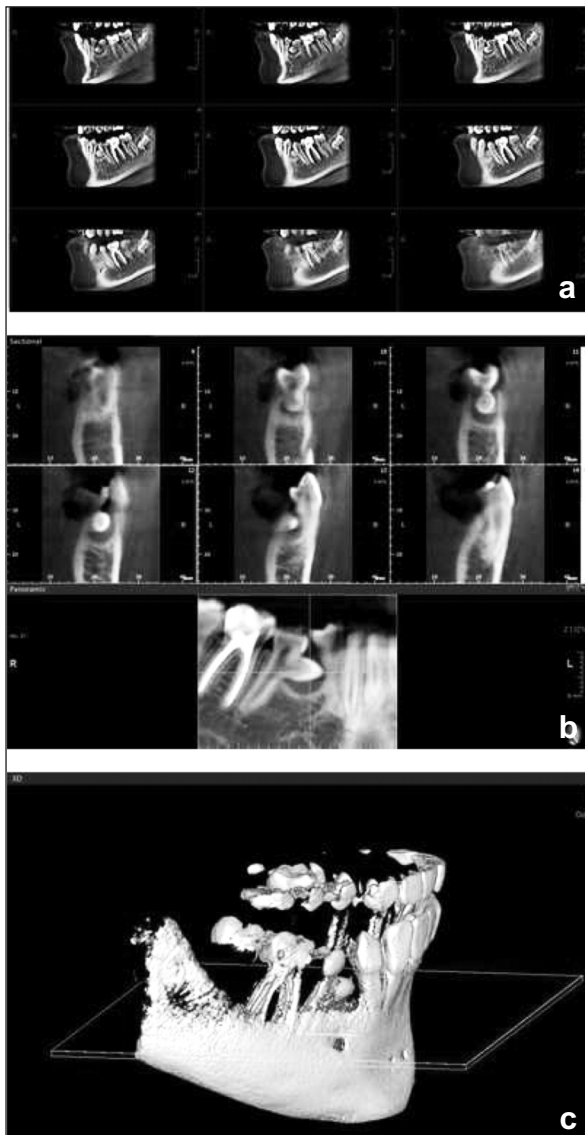
**FIGURE 3:** Panoramic radiograph.

ond premolar because the twinning part of the tooth remained stuck inside the gum tissue and had no clinically observable manifestation. Also, the patient had no functional, periodontal, or esthetic problems. Routine endodontic treatment was carried out with right permanent mandibular first molar. Oral hygiene instructions were provided.

At the year 1, 2, and 3 of clinical and radiographic follow-up, double teeth continued to maintain vitality without any signs or symptoms of pathology (Figures 5, 6 and 7).

## DISCUSSION

The prevalence of dental anomalies in the primary dentition is 1.8.<sup>5</sup> “Double teeth” is an uncommon dental defect which may arise both in primary and permanent dentition. In contrast to other dental anomalies, it occurs more frequently in the primary dentition than in the permanent dentition, with a

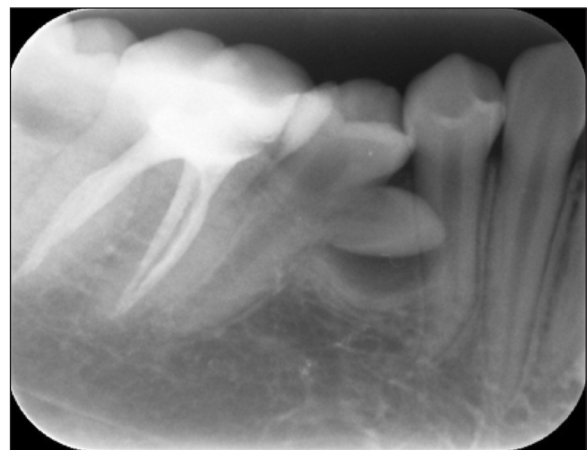

**FIGURE 4:** Various CBCT views of the right permanent mandibular second premolar, a) CBCT stated that the teeth has two separate crown and they co-joined at the cervical third of apex, b-c) CBCT image has shown that there was no relationship between the right permanent mandibular first and second premolar's crowns

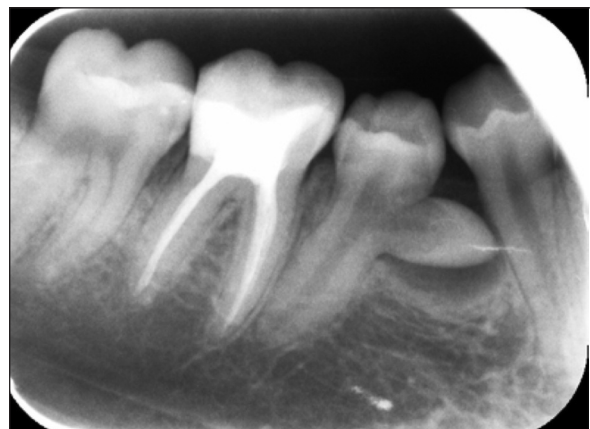prevalence in Caucasian patients of 0.72% and 0.1%, respectively.<sup>3,6,7</sup> Double teeth predominantly involve the anterior region, most frequently affecting the incisors and canines.<sup>8</sup> Kapdan et al. surveyed dental anomalies in the primary dentition of Turkish children and reported its prevalence as 1.3%.<sup>9</sup> In the same study, double teeth were the most frequent (1.3%) abnormality, followed by 0.3% of supernumerary teeth, 0.3% of microdontia, and 0.2% of hypodontia.

The exact etiology is unknown, but it is believed to be due to the impact of some physical forces on the developing tooth germs and subsequent union of enamel organ and the dental papilla resulting in fusion or germination of teeth. Hereditary factors, excess intake of vitamin A, viral infections, and using thalidomide during pregnancy are other possible factors.<sup>10-14</sup> Mitsiadis et al. demonstrated an essential role of Jagged 2 gene-mediated Notch signaling in tooth development and teeth fusion.<sup>15</sup> Our patient's medical and familial history was noncontributory; there was no previous story of trauma, nutritional deficiencies or use of medication during pregnancy.

Double teeth anomalies are generally asymptomatic. However, affected teeth may cause problems such as caries in the groove between



**FIGURE 5:** Periapical radiograph taken after 1 year follow-up.



**FIGURE 6:** Periapical radiograph taken after 2 year follow-up

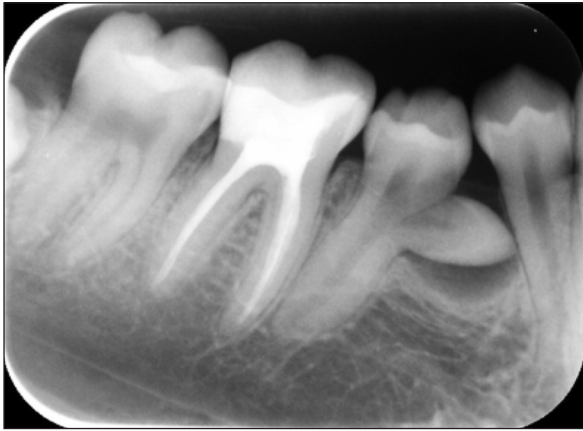

FIGURE 7: Periapical radiograph taken after 3 year follow-up.

conjoining parts, poor esthetics, and periodontal destruction.<sup>16</sup> In the case presented none of these complications were present, as the twinning part was underneath the gum tissue. Another concern to take into account would be the relationship between anomalies of the permanent and primary teeth. Double primary teeth may cause spacing or crowding problems leading to deficiency of facial profile or midline deviation in permanent dentition. The early detection of these anomalies is essential in terms of preventing such problems.<sup>5</sup>

Radiographic examination is essential in diagnosing double teeth anomalies. Because of superimposition and geometric distortion of the anatomical structures, conventional radiographic methods reveal only limited aspects.<sup>17-19</sup> A way to overcome such limitations is cone beam-computed tomography imaging technique which produces accurate 3-D images of the teeth and the surrounding dentoalveolar structures.<sup>20,21</sup> According to Shah et al., double teeth assessment should include the use of cone beam computed tomography as an imaging technique.<sup>22</sup> Three-dimensional dental CBCT has been shown to achieve good imaging quality with a lower radiation exposure than that of conventional CT. Three-dimensional imaging allows evaluation of the anatomical relationship of the double teeth to anatomical structures in any plane the clinician wishes to view.<sup>23</sup>

There have been only four case reports in which CT was used in the imaging of double teeth. Ballal et al., to ascertain root canal morphology of double teeth, planned dental imaging with the help of a spiral computed tomography (SCT).<sup>24</sup> Lucey et al. made radiographic diagnosis and assessment of double teeth by CBCT before surgery.<sup>25</sup> Rudagi et al. confirmed the complicated morphology of the root canal system of the double teeth with the SCT imaging prior to root canal treatment.<sup>26</sup> Keys et al. used CBCT imaging in order to plan surgical and endodontic treatment of double teeth.<sup>27</sup> The authors stated that CBCT images enhanced the pre-treatment information by allowing visualization of root canal morphology and adjacent anatomical structures.

In the case presented, we confirmed utilizing CBCT that there was no relationship between the crowns of the right permanent mandibular first and second premolars. As there was no gingival recession, no pathological periodontal pocket formation, no loss of bone margin and no evidence of root resorption through follow-up period, no invasive treatment was carried out. Minimal intervention technique and regular follow-up for the management of double teeth have also been advocated in the literature.<sup>28</sup>

To our knowledge, this case is the first reported double teeth in permanent dentition which cannot be observed to have any clinical manifestation. In consequence, this experience implies the importance of radiographic examination in diagnosing dental anomalies.

#### **Conflict of Interest**

*Authors declared no conflict of interest or financial support.*

#### **Authorship Contributions**

*Merve S. Mutluay made literature research and dental treatment of patient. Işıl Saroğlu Sönmez designed the study. Merve S. Mutluay and Işıl Saroğlu Sönmez wrote the article. Volkan Arıkan promoted the study and revised the article.*

## REFERENCES

- Duncan WK, Helpin ML. Bilateral fusion and gemination: a literature analysis and case report. *Oral Surg Oral Med Oral Pathol* 1987;64(1):82-7.
- Killian CM, Croll TP. Dental twinning anomalies: the nomenclature enigma. *Quintessence Int* 1990;21(7):571-6.
- Brook AH, Winter GB. Double teeth. A retrospective study of 'geminated' and 'fused' teeth in children. *Br Dent J* 1970;129(3):123-30.
- Chaudhry SI, Sprawson NJ, Howe L, Nairn RI. Dental twinning. *Br Dent J* 1997;182(5):185-8.
- Gomes RR, Fonseca JA, Paula LM, Acevedo AC, Mestrinho HD. Dental anomalies in primary dentition and their corresponding permanent teeth. *Clin Oral Investig* 2014;18(4):1361-7.
- Knezević A, Travan S, Tarle Z, Sutalo J, Janković B, Ciglar I. Double tooth. *Coll Antropol* 2002;26(2):667-72.
- Wu CW, Lin YT, Lin YT. Double primary teeth in children under 17 years old and their correlation with permanent successors. *Chang Gung Med J* 2010;33(2):188-93.
- Schuurs AH, van Loveren C. Double teeth: review of the literature. *ASDC J Dent Child* 2000;67(5):313-25.
- Kapdan A, Kustarci A, Buldur B, Arslan D, Kapdan A. Dental anomalies in the primary dentition of Turkish children. *Eur J Dent* 2012;6(2):178-83.
- Roa A. Synodontia of deciduous maxillary central and lateral incisors with a supernumerary tooth. *J Indian Soc Pedo Prev Dent* 2000;18(2):71-4.
- Moody E, Montgomery B. Hereditary tendencies in tooth formation. *J Am Dent Assoc* 1934;21(10):1774-6.
- Goenka P, Dutta S. "Tooth triplet": a rare case report. *J Oral Health Comm Dent* 2009;3(1):15-7.
- Prasad Rao VA, Reddy NV, Krishnakumar R, Sugumaran DK, Mohan G, Eagappan Senthil AR. Primary double tooth with partial anodontia of permanent dentition-a case report. *J Clin Exp Dent* 2010;2(2):e78-81.
- Babaji P, Prasanth MA, Gowda AR, Ajith S, D'Souza H, Ashok KP. Triple teeth: report of an unusual case. *Case Rep Dent* 2012;2012:735925.
- Mitsiadis TA, Regaudiat L, Gridley T. Role of the Notch signalling pathway in tooth morphogenesis. *Arch Oral Biol* 2005;50(2):137-40.
- Grover PS, Lorton L. Gemination and twinning in the permanent dentition. *Oral Surg Oral Med Oral Pathol* 1985;59(3):313-8.
- Gröndahl HG, Huumonen S. Radiographic manifestations of periapical inflammatory lesions. *Endod Topics* 2004;8(1):55-67.
- Cotton TP, Geisler TM, Holden DT, Schwartz SA, Schindler WG. Endodontic applications of cone-beam volumetric tomography. *J Endod* 2007;33(9):1121-32.
- Patel S, Dawood A, Ford TP, Whites E. The potential applications of cone beam computed tomography in the management of endodontic problems. *Int Endod J* 2007;40(10):818-30.
- Scarfe WC, Levin MD, Gane D, Farman AG. Use of cone beam computed tomography in endodontics. *Int J Dent* 2009;1-20.
- Tyndall DA, Kohltharber H. Application of cone beam volumetric tomography in endodontics. *Aus Dent J* 2012;57 Suppl 1:72-81.
- Shah P, Chander JM, Noar J, Ashley PF. Management of 'double teeth' in children and adolescents. *Int J Paediatr Dent* 2012;22(6):419-26.
- Patel S. New dimensions in endodontic imaging: part 2. Cone beam computed tomography. *Int Endod J* 2009;42(6):463-75.
- Ballal S, Sachdeva GS, Kandaswamy D. Endodontic management of a fused mandibular second molar and paramolar with the aid of spiral computed tomography: a case report. *J Endod* 2007;33(10):1247-51.
- Lucey S, Heath N, Welbury RR, Wright G. Case report: cone-beam ct imaging in the management of a double tooth. *Eur Arch Paediatr Dent* 2009;10 Suppl 1:49-53.
- Rudagi K, Rudagi BM, Metgud S, Wagle R. Endodontic management of mandibular second molar fused to a supernumerary tooth, using spiral computed tomography as a diagnostic aid: a case report. *Case Rep Dent* 2012;2012:614129.
- Keys WF, Keightley AJ, Welbury RR. Sectioning of a double tooth aided by cone-beam computed tomography. *Eur Arch Paediatr Dent* 2013;14(3):167-71.
- Prabhu RV, Chatra L, Shenai P, Prabhu V. Bilateral fusion in primary mandibular teeth. *Indian J Dent Res* 2013;24(2):277-80.