

Unusual Brain and Temporal Bone Metastases of a Botryoid Type of Embryonal Nasopharyngeal Rhabdomyosarcoma

Mustafa KAZKAYASI*, Fulya KÖYBAŞOĞLU**

* Kırıkkale University Hospital, Department of Otorhinolaryngology, KIRIKKALE

** Ankara Yıldırım Beyazıt Education Hospital, Department of Pathology, ANKARA

ABSTRACT

We present a 2 year-old boy with a botryoid type of embryonal nasopharyngeal rhabdomyosarcoma with an unusual outcome. Temporal bone metastasis with brain invasion was detected one year after therapy had been completed. Despite multidisciplinary therapeutic approach, distant metastases occurred in the mastoid and squamous portions of the temporal bone with invasion of the temporal lobe. We review the clinical features of head and neck rhabdomyosarcoma and emphasize the importance of distant tumor metastasis. We believe that this tumor may spread to distant sites by different ways, and its biological course is typically fatal, particularly if recognized in advanced stages.

Key Words: Embryonal rhabdomyosarcoma, Botryoid type, Nasopharynx, Distant metastasis, Temporal bone

ÖZET

Botriyoid Tip Embriyonal Nazofaringeal Rabdomyosarkomunun Olağandışı Beyin ve Temporal Kemik Metastazı

Olağan dışı klinik seyir gösteren botriyoid tip embriyonal nazofaringeal rabdomyosarkomu bulunan 2 yaşındaki hasta sunulmuştur. Tedavi tamamlandıktan bir yıl sonra beyin invazyonu ve temporal kemik metastazı bulundu. Multi-disipliner terapötik yaklaşıma rağmen, hastada temporal kemiğin skuamöz ve mastoid parçası ve temporal lobda uzak metastaz gelişti. Baş boyun rabdomyosarkomları hakkında literatür gözden geçirildi ve uzak metastazların önemini vurgulandı. Bu tümör farklı yollarla uzak metastaz yayılımını yapabilmekte ve özellikle ileri evrelerde belirlendiğinde biyolojik seyri tipik olarak ölümcül olmaktadır.

Anahtar Kelimeler: Embriyonal rabdomyosarkoma, Botriyoid tip, Nazofarinks, Uzak metastaz, Temporal kemik

INTRODUCTION

Rhabdomyosarcoma (RMS) which is the most common soft tissue sarcoma in childhood (1) accounts for 5-8% of all childhood solid tumors (2). The tumor can arise in different sites, typically involving the soft tissues of head and neck, extremities, and genitourinary tract (1,3). RMS is noted as the most common type of head and neck cancer between 2-5 years of age (4,5), and 40-50% of pediatric RMS develop in the head and neck region (3,6-8). Approximately 80% of all newly diagnosed cases of RMS are embryonal (ERMS, 60%) or alveolar (ARMS, 20%) types (3,9). Although the overall prognosis has improved recently with the multidisciplinary treatment the survival rates vary in different series (2,7,8,10,11).

In this article, a case of botryoid type of embryonal nasopharyngeal rhabdomyosarcoma with temporal bone metastasis and brain invasion is presented and the mechanisms of metastasis besides the importance of distant tumor spread via a hematogenous or a perineural pathways are emphasized.

CASE REPORT

A 2 year-old boy was referred to outpatient polyclinics with a 6-month history of nasal obstruction and bleeding. On admission, the patient had a botryoid mass in the right nare. Nasal airway was obstructed and there was a serosanguineous discharge from the nose. The soft palate was pushed towards the oropharynx by the tumoral mass. There was no cervical lymphadenopathy. Further laboratory investigations [lumbar puncture, bone scan and computed tomography (CT) of the chest] and physical examination were normal. Nasal-paranasal sinus and nasopharyngeal CT scans revealed a tumor mass totally obliterating both the right nasal cavity and nasopharynx, advancing to the oropharynx and pushing the soft palate towards the oral cavity. Although the lesion was homogenous and there was no bone destruction, but invasion to the right infratemporal fossa and parapharyngeal space was evident (Figure 1). Histopathologic examination confirmed a botryoid type of embryonal nasopharyngeal RMS. The tumor was composed of undifferentiated round

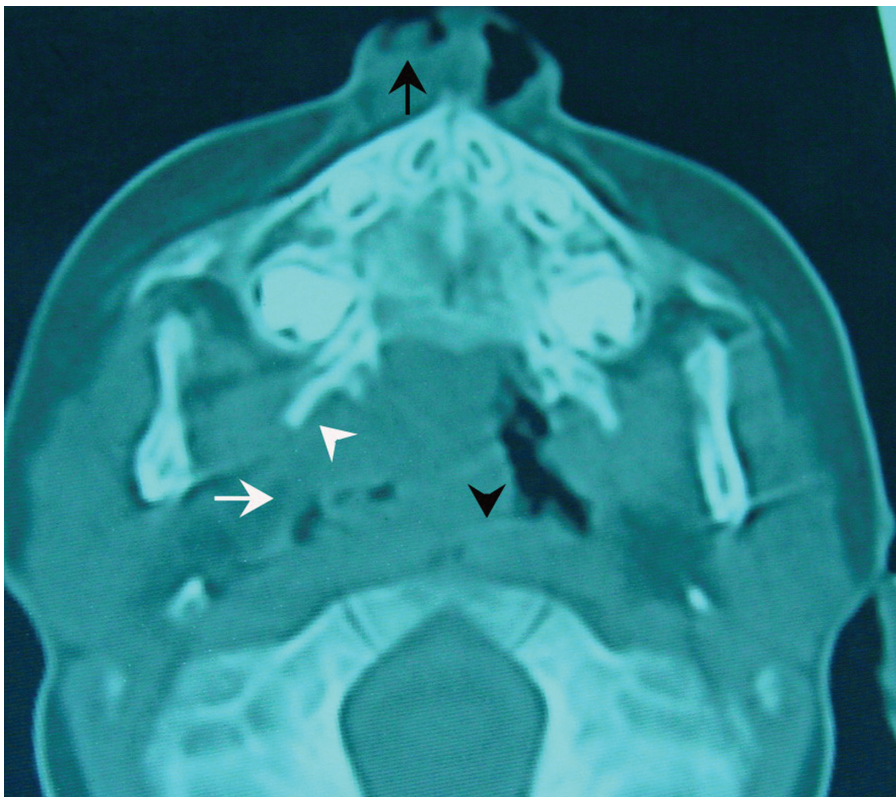


Figure 1. Axial CT scan demonstrates a tumor mass obliterating the right nasal cavity (arrow) and nasopharynx (arrowhead). Note the tumor invasion into the infratemporal fossa (white arrowhead) and parapharyngeal space (white arrow).

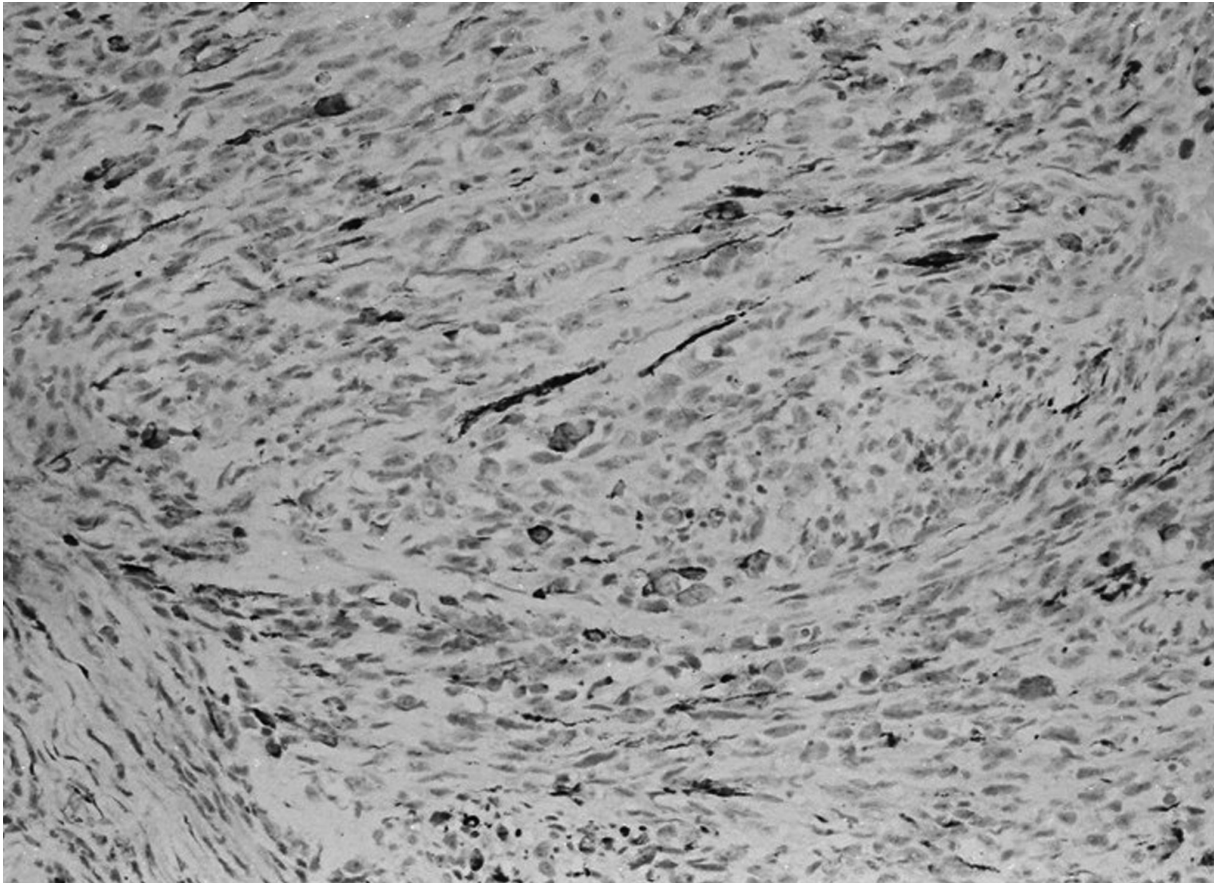


Figure 2. An embryonal RMS composed of undifferentiated round and spindle cells showing Desmin positivity with immunohistochemical staining (IHC x 200).

and spindle cells with a few scattered rhabdomyoblasts. Immunohistochemical analysis revealed a positive immunostaining for Desmin and Vimentin (Figure 2). The tumor was classified as Stage 1 according to the Intergroup of Rhabdomyosarcoma Study (IRS) criteria (11). The patient was treated with a combined regimen of chemotherapy, including vincristin, actinomycine-D and ifosfamide (VAI). After the fourth course of chemotherapy, facial and bilateral neck irradiation (total irradiation dose of 42 Gy) was performed. At the end of therapy, the tumoral mass completely disappeared and there was no evidence of disease on examination. At that time, neither cerebral nor nasal-paranasal sinus CT scans demonstrated any evidence of residual pathology.

One year after the diagnosis, on routine control examination he was found to have a right postauricular swelling and induration, and the auricle was

pushed forward resembling subperiosteal abscess of the mastoid. External auditory canal, tympanic membrane, and tympanum were all intact on otologic examination by microscope. While nasal-paranasal sinus and nasopharyngeal CT scans were normal, contrast enhanced CT scan of the temporal bone demonstrated a tumor mass (38x25 mm) in the temporal bone with subsequent bone destructions in mastoid and squamous portions. The lesion was homogenous, but expansion to the temporal lobe was evident (Figure 3). During mastoidectomy, performed to drain the abscess, gross tumor involvement of the temporal bone was noticed. Histopathologic examination again was consistent with a botryoid type of embryonal nasopharyngeal RMS. Intrathecal and systemic chemotherapy were administered, however, the patient died probably by intracranial involvement two months after recognition of relaps.

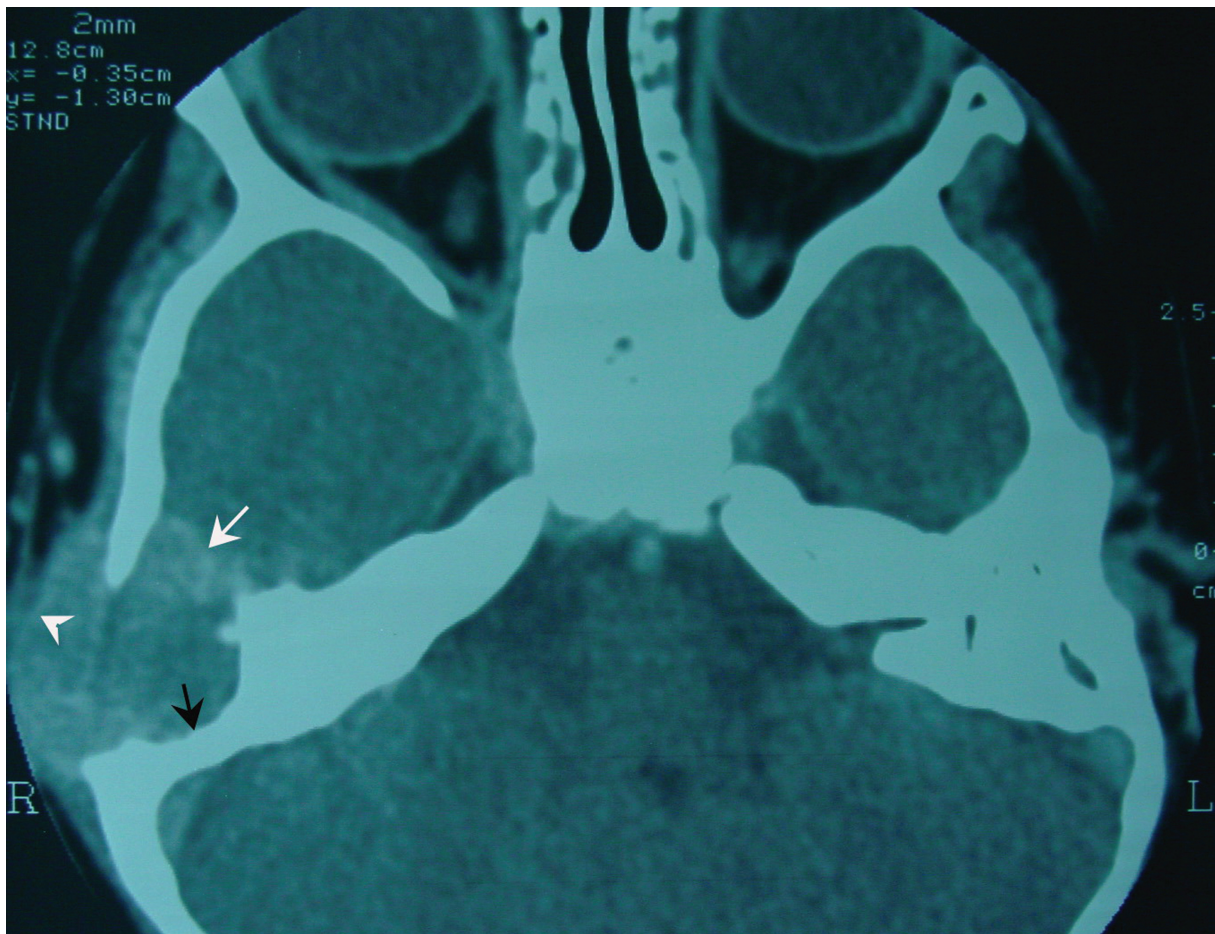


Figure 3. Axial CT scan demonstrates a tumor mass (38x25 mm.) in the temporal bone with destruction (black arrow). Note the expansion into the temporal lobe (white arrow) and to the subcutaneous tissue (arrow head).

DISCUSSION

Anatomical site, tumor size, invasiveness, nodal and distant metastasis, and finally the stage of tumor were noted as determinants of survival for rhabdomyosarcoma arising in the head and neck region (3,7,10). Tumors arising in the parameningeal sites of the head and neck region have been associated with intermediate survival. Patients with advanced stage disease normally require the most aggressive therapy in spite of the greatest risk for failure (7). In the past, most children with metastatic tumor were reported to have an ultimately fatal course (2,6,11). Maurer et al. (11) noted disease-free survival for stage I, II, III and IV as 77%, 65%, 41% and 15% respectively. Although overall 5-year survival rate was reported as 55% in many articles (2,6,11), a higher figure of 74% (ranging 64-84)

was recently published by Krause et al. (7). Improved chemotherapeutic agents and radiation therapy have reduced the local and systemic recurrences (1,12,13). Hence, there has been a striking progress in the treatment of RMS during the past 30 years. Recently, Baker et al. (12) announced the survival rate of RMS as 90% for patients with group I and II embryonal tumors. However, the risk for micrometastatic disease even in patients with stage 1 and 2 tumors may be high at the time of diagnosis (3). Although clinical and radiological examinations revealed no pathological findings, the present case developed unfortunate bone and brain metastases one year after the completion of therapy. Goto et al. (10) noted that RMS is a very aggressive tumor, and death often occurs by intracranial spread or by distant metastasis. The clinical history of our pati-

ent supported this observation. Despite the brain generally remains an infrequent site for initial metastatic lesion and intracranial involvement usually results from direct extension of the extracranial tumor, (1,14) our case appears to be an exception. It has been reported that bone does not constitute an effective barrier to growth of the tumor and particularly RMS in the head and neck region frequently invade adjacent bony structures such as sinuses, the temporal and mastoid bones, and the base of the skull. This specialty of these tumors may prove fatal because of extensive meningeal spread (3), as it probably happened in our case.

The patients with parameningeal primary tumors in the nasopharynx, paranasal sinuses, middle ear and temporal bone have been reported to have less favorable survival rates due to the high risk of tumor spreading to the central nervous system (3,10). Nasopharyngeal RMS tend to grow rapidly and invade adjacent structures by hematogenous or lymphatic spread (4,5,8,15,16). The former is noted as a common occurrence in childhood nasopharyngeal tumors (13). Tumor metastasis to the temporal bone by diffuse local invasion might normally be expected, although this did not appear to be the mechanism of spread in our case. Since nasopharyngeal tumors may remain silent for months before developing any signs or symptoms, tumor extension, especially into the skull base, has been accepted usually a late diagnosis (16). In our case, after a year of remission, bone and brain metastases surprised us, since the period was too short. As the anatomic boundaries to prevent tumor extension are absent in nasopharyngeal tumors, they might extend directly into the meninges. It has been stated that these tumors might extend to the middle cranial fossa as a result of perineural spread, and the Vidian and especially mandibular nerve serve as pathways to spread to the cranium (17). Tumor extension into the pterygopalatine fossa (PPF) through the sphenopalatine foramen may take place following invasion of the nasal fossa and this situation places the maxillary nerve at risk (17). In our case, there were tumor extensions into the PPF and infratemporal fossa which might be considered as a potential cause of perineural spread. The hematogenous pathway could be the mechanism of cranial invasion in the present case as there was absolutely no invasion of the eustachian tube. If diffuse local inva-

sion was the cause of cerebral metastasis, the tumor should have invaded the middle ear, tympanic membrane, and ear drainage must have been present (4,5,8,18). RMS of the middle ear or mastoid is a rare condition and direct meningeal extension from the temporal bone was reported to have a poor prognosis, even with intensive treatment (4,8).

In conclusion, RMS of the head and neck remains a challenging disease in childhood and could have poor prognosis despite intensive multimodal treatment. Parameningeal RMS may spread via different ways, predominantly by direct extension to neighbouring anatomical sites. The present case suggests that the tumor might spread via a hematogenous route or perineural way in spite of intensive combined therapy and points out to the heterogenous nature of head and neck RMS during childhood.

REFERENCES

1. Ito F, Watanabe Y, Harada T, Horibe K. Cerebral metastasis of alveolar rhabdomyosarcoma in an infant with multiple skin nodules. *J Pediatr Hematol Oncol* 19: 466-469, 1997.
2. Pappo AS, Bowman LC, Furman WL, et al. A phase II trial of high-dose methotrexate in previously untreated children and adolescents with high-risk unresectable or metastatic rhabdomyosarcoma. *J Pediatr Hematol Oncol* 19: 438-442, 1997.
3. Weiss SW, Goldblum JR. Rhabdomyosarcoma. In: Enzinger and Weiss's Soft Tissue Tumors. 4th ed. Missouri, Mosby, 2001: 785-835.
4. Cemiloglu R, Tekalan SA, Patiroglu T, Unlu Y. Rhabdomyosarcoma of the temporal bone: clinical report. *Arch Otorhinolaryngol* 244: 195-197, 1987.
5. Wells SC. Embryonal rhabdomyosarcoma of the ear: A review of the literature and case history. *J Laryngol Otol* 98: 1261-1266, 1984.
6. R. Corbett, J. Pritchard, P.N. Plowman. Sarcomas of the head and neck. Tumours of the head and neck, In: Scott-Brown's Otolaryngology. Kerr AG, Adams DA, Cinnamon MJ (eds). 6th ed. Oxford, Butterworth-Heinemann, Vol.6, Chp.31, 1997: 6-9.
7. Kraus DH, Saenz NC, Gollamudi S, et al. Pediatric rhabdomyosarcoma of the head and neck. *Am J Surg* 174: 556-560, 1997.
8. Said H, Phang KS, Razi A, et al. Rhabdomyosarcoma of the middle ear and mastoid in children. *J Laryngol Otol* 102: 614-619, 1988.

9. Newton WA Jr, Gehan EA, Webber BL, et al. Classification of rhabdomyosarcomas and related sarcomas: pathologic aspects and proposal for a new classification- an Intergroup Rhabdomyosarcoma Study. *Cancer* 76: 1073-1085, 1995.
10. Goto TK, Yoshiura K, Tanaka T, et al. A follow-up of rhabdomyosarcoma of the infratemporal fossa region in adults based on the magnetic resonance imaging findings. Case reports. *Oral Surg Oral Med Oral Pathol Oral Radiol Endod* 86: 616-625, 1998.
11. Maurer HM, Beltangady M, Gehan EA, et al. The Intergroup Rhabdomyosarcoma Study-1: a final report. *Cancer* 61: 209-220, 1988.
12. Baker KS, Anderson JR, Link MP, et al. Benefit of intensified therapy for patients with local or regional embryonal rhabdomyosarcoma: results from the Intergroup Rhabdomyosarcoma Study IV. *J Clin Oncol* 18: 2427-2434, 2000.
13. DelBalso AM, Weinstein ZR, Deal JL, et al. Nasopharyngeal rhabdomyosarcoma in an adult with intracranial and intraorbital extension. *Ear Nose Throat J* 65: 420-423, 1986.
14. Shimada H, Newton WA Jr, Soule EH, et al. Pathology of fatal rhabdomyosarcoma. Report from Intergroup Rhabdomyosarcoma Study (IRS-I and IRS-II). *Cancer* 59: 459-465, 1987.
15. Bleichner JC, Ragsdale B, Hartmann DP, Merida M. Nasopharyngeal malignancies in children. *Ear Nose Throat J* 66: 148-152, 1987.
16. Tom LWC, Anderson GJ, Womer RB, et al. Nasopharyngeal malignancies in children. *Laryngoscope* 102: 509-514, 1992.
17. Chong VFH, Fan YF. Pterygopalatine fossa and maxillary nerve infiltration in nasopharyngeal carcinoma. *Head Neck* 19: 121-125, 1997.
18. Mena JC, Borne JA. Temporal bone rhabdomyosarcoma. *AJR* 171: 877-879, 1998.

Correspondence

Dr. Mustafa KAZKAYASI

8. Cad. 84. Sk. No: 4/11

Emek 06510

ANKARA

e-mail: mkazkayasi@yahoo.com