

See discussions, stats, and author profiles for this publication at: <https://www.researchgate.net/publication/273754829>

Cadmium Induced Changes on Growth Performance, Some Biochemical Parameters and Tissue in Broilers: Effects of Vitamin C and Vitamin E

Article in *Asian Journal of Animal and Veterinary Advances* · September 2011

DOI: 10.3923/ajava.2011.923.934

CITATIONS

20

READS

83

6 authors, including:



Miyase Cinar

Kirikkale University

21 PUBLICATIONS 204 CITATIONS

[SEE PROFILE](#)



Ayse Arzu Yigit

Kirikkale University

50 PUBLICATIONS 203 CITATIONS

[SEE PROFILE](#)



İlkay Yalcinkaya

Kirikkale University

19 PUBLICATIONS 235 CITATIONS

[SEE PROFILE](#)



Ertan Oruç

Selcuk University

55 PUBLICATIONS 545 CITATIONS

[SEE PROFILE](#)

Some of the authors of this publication are also working on these related projects:



Investigation of the Effects of Endocrine Disrupting Compounds on Progesterone Secretion by Cultured Bovine Luteal Cells [View project](#)



in vitro and in vivo effects of acetylcholinesterase activity [View project](#)

Cadmium Induced Changes on Growth Performance, Some Biochemical Parameters and Tissue in Broilers: Effects of Vitamin C and Vitamin E

¹Miyase Cinar, ²A. Arzu Yigit, ³İlkay Yalcinkaya, ⁴Ertan Oruc, ¹Ozkan Duru and ⁵Metin Arslan

¹Department of Biochemistry, ²Department of Physiology, ³Department of Animal Nutrition and Nutritional Diseases, Faculty of Veterinary Medicine, Kirikkale University, Yahsihan, 71451 Kirikkale, Turkey

⁴Department of Pathology, Faculty of Veterinary Medicine, Ataturk University, 25240, Erzurum, Turkey

⁵Department of Chemistry and Chemical Processing Technologies, Kirikkale Vocational High School, Kirikkale University, 71451 Kirikkale, Turkey

Corresponding Author: Miyase Cinar, Department of Biochemistry, Faculty of Veterinary Medicine, Kirikkale University, Yahsihan, 71451 Kirikkale, Turkey

ABSTRACT

This study was performed to determine the effects of vitamin C (vit C) and vitamin E (vit E) on growth performance, some biochemical parameters and tissue changes in broiler chickens exposed to cadmium (Cd). One hundred twenty, 1-day-old, Ross broiler chicks were divided into 4 groups with 3 replicates and fed with a basal diet (control) or the basal diet supplemented with 60 mg kg⁻¹ Cd, 60 mg kg⁻¹ Cd+400 mg kg⁻¹ vit C, or 60 mg kg⁻¹ Cd+250 mg kg⁻¹ vit E for 42 days. Body weight (BW), Body Weight Gain (BWG) and Feed Consumption (FC) were recorded and feed conversion ratio (FCR) was calculated. Plasma were analysed for aspartate transaminase (AST), alanine transaminase (ALT), gamma glutamyltransferase (GGT) activities and total protein, total cholesterol and creatinine levels. Cadmium significantly decreased the BW (p<0.001), BWG (p<0.001), FC (p<0.001) and FCR (p<0.05) compared with the control group. Regarding the same groups plasma and kidney Cd (p<0.001) and AST (p<0.05) and GGT activities (p<0.01) were increased. While growth performance were not affected in vit C and vit E supplemented group compared with the Cd-only group, these treatments reduced plasma Cd and GGT activities. Furthermore vit C was more effective in reducing Cd accumulation in kidneys and liver.

Key words: Biochemical parameters, cadmium, performance, tissue accumulation, vitamin C, vitamin E

INTRODUCTION

Cadmium is a very toxic metal, also an environmental and industrial pollutant which is present in soil, water, air and food (Al-Khedhairi *et al.*, 2001; Cinar, 2003; Al-Attar, 2005; Eriyamremu *et al.*, 2006; Kaplan *et al.*, 2011). This metal enters surface water from the industrial wastes and found in soil by leaching of sewage sludge through soil (Joshi and Bose, 2002). So, the population can be affected by Cd through food consumption, drinking water and incidental ingestion of soil contaminated by Cd (Hardej and Trombetta, 2004). Cadmium, which is taken with

food, is absorbed poorly. After absorption, Cd transported in the plasma, bound to albumin and accumulated mainly in kidneys and liver. This metal causes variety of toxic effects on various body tissues of both human and animals (Kaya *et al.*, 2002).

Cadmium is known to cause reproductive processes, renal dysfunction, hepatic toxicity, osteomalacia, neurological impairment, pancreatic activity changes (Hooser, 2007). Chronic Cd toxicity caused an oxidative stress throughout lipid peroxidation and consumption of some antioxidant systems in broilers (Cinar *et al.*, 2010). It also affects various structures and metabolic processes, such as nucleic acids, carbohydrates, energy metabolism, protein synthesis and enzyme systems (Cinar, 2003). In several reports administration of antioxidants as zinc (Uyanik *et al.*, 2001), selenium (Li *et al.*, 2010), diallyl tetrasulfide (Pari and Murugavel, 2005) and quercetin (Morales *et al.*, 2006) have been shown to have protective effect against Cd toxicity.

Vitamin C and vitamin E are recognized as an essential nutrients for all species of animal (McDowell, 2000). These vitamins have been shown to have protective effect against metal induced toxicity (Appenroth *et al.*, 2001; Rao and Sharma, 2001; Wershana, 2001; Jiraungkoorskul *et al.*, 2007). Also, vitamin C (Erdogan *et al.*, 2005; Cinar *et al.*, 2010) and vit E (Ognjanovic *et al.*, 2003; Cinar *et al.*, 2010) have a protective role on the lipid peroxidation induced by the toxic effects of Cd.

Several studies (Uyanik *et al.*, 2001; Erdogan *et al.*, 2005; Herzig *et al.*, 2007) have been found about growth performance, tissues and plasma Cd levels and biochemical parameters in Cd exposed broilers. But there are limited studies (Erdogan *et al.*, 2005) about the effect of vit C on Cd induced performance and blood changes in broilers, in addition there are no studies about the effects of vit E on Cd induced performance, blood and tissue changes in broilers. Therefore, the objective of the present study was to investigate the effects of vit C and E on growth performance, plasma, liver and kidneys Cd levels and some biochemical parameters, pathological changes in these tissues of broilers exposed to Cd.

MATERIALS AND METHODS

Animals and experimental design: One hundred twenty, day old Ross broiler chicks of both sexes were used in this study. Broilers were weighed to equal BW of the chicks in all groups and evenly distributed to 4 groups. There were 3 replicates with 10 chicks for each dietary treatment and placed individually in metabolic cages (33 cm×33 cm×40 cm). Group 1 was the control group in which birds were fed basal diet (Table 1); group 2, 3 and 4 received the basal diets supplemented with Cd (as CdCl₂×H₂O) 60 mg kg⁻¹; however group 3 and 4 were also supplemented with 400 mg kg⁻¹ vit C (L-Ascorbic Acid) and 250 mg kg⁻¹ vit E (dl α-tocopherol acetate), respectively. The chicks were fed with a starter diet for 15 days and they received a grower finisher diet until the day 42. Experimental diets were formulated as recommended by the NRC (1994) Chemical analyses of the experimental rations were determined by the AOAC method (AOAC, 2006). The metabolizable energy values of the rations were calculated based on the chemical composition (Anonymous, 1991). Levels of Cd were found in starter, grower broiler diets and tap water as 0.1 ppm, 0.057 ppm and 29.3 µg L⁻¹ according to AOAC (2006), respectively. Initially the room temperature was 32°C and gradually decreased to 25°C and allowed *ad libitum* access food and water. This study was conducted in University of Kirikkale, Faculty of Veterinary Medicine, Department of Animal Nutrition and Nutritional Disease. The animal care and use protocol was reviewed and approved by the Ethics Committee of the Faculty of Veterinary Medicine, Kirikkale University (03. 02. 2005-05/01).

Table 1: Ingredients and chemical composition of the basal diet to broilers (%)

Ingredients	Starter	Grower
Corn	36.00	49.00
Wheat	15.35	8.00
Soybean meal	25.00	20.00
Full fat soy bean	14.15	15.00
Fish meal	3.15	1.65
Vegetable oil	3.00	3.00
Limestone	1.50	1.50
Dicalcium phosphate	1.00	1.00
Salt	0.25	0.25
Vitamin premix ¹	0.25	0.25
Mineral premix ²	0.15	0.15
DL-methionine	0.02	0.20
Analyzed		
Crude protein	23.40	20.30
Ether extract	8.70	10.10
Calculated		
Metabolizable energy (kcal kg ⁻¹)	3110.00	3215.00

¹The vitamin premix (Rovimix 124-F) supplemented to 2.5 kg of feed had the following amounts of vitamins: vitamin A-15 000 000 IU, Vitamin D3-1 500 000 IU, Vitamin E-50 000 mg, Vitamin K3-5 000 mg, Vitamin B1-3 000 mg, Vitamin B2-6 000 mg, Niasin-25 000 mg, Kalsiyum- D Pantotenat-120 000 mg, Vitamin B6-5 000 mg, Vitamin B12-30 mg, Folic acid-1 000 mg, D-Biotin-125 mg, L-Lysin-300 000 mg. ²The mineral premix (Remineral 1) supplemented to 1 kg of feed had the following amounts of minerals: Mn-80 000 mg, Fe-30 000 mg, Zn-60 000 mg, Cu-5 000 mg, Co-500 mg, I-2 000 mg, CaCO₃-235 680 mg

Measurements of performance: The BW, BWG of chicken and FC were recorded at weekly intervals. Feed conversion ratio was calculated by dividing weekly FC by body weight gain (BWG).

Sample collection and analysis: At the end of the experimental period, 12 broilers (4 chick per each replicate) were randomly selected in each group. Blood samples were collected into heparinized test tubes from vena cephalicus for biochemical analysis. Plasma were separated by centrifugation at 1600×g, 4°C, 10 min and stored at -30°C until the analysis. Aspartate aminotransferase (EC 2.6.1.1), ALT (EC 2.6.1.2), GGT (EC 2.3.2.2) activities, total protein, creatinine (DDS, Germany) and total cholesterol (AMD, Austria) levels were determined by a Shimadzu UV, 1700 spectrophotometer (Japan) with diagnostic kits.

Nine birds from each group were killed by neck dislocation and liver and kidney samples were collected. Parts of the tissue samples were frozen individually in polypropylene bags for metal analysis. Plasma (Perkin Elmer Corporation, 2000), liver and kidneys Cd levels were determined by flame atomic absorption spectrophotometer (Perkin Elmer Analyst 400 model flame atomic absorption). Dry ashing procedure was used for the metal analysis in tissues (AOAC, 2006).

Remaining parts of liver and kidney samples were fixed in 10% neutral formalin solution for histopathological processing. Tissue samples were embedded in paraffin wax, sectioned in 5 micron. All sections were stained with Hematoxylin and Eosine (H-E) and examined under light microscope (Luna, 1968). Histopathological changes were semiquantitatively assessed under the light microscope with an ocular grid and 4X, 10X, 40X objective, respectively. A total of 10 high-power fields were randomly chosen. Changes in the histopathological parameters for liver and kidney

tissues were graded as follows: (-) no changes, (+), (++) and (+++) indicating mild, moderate and severe histopathological changes, respectively.

Statistical analysis: Statistical analyses of data were performed by SPSS 10.0 version for Windows (SPSS Inc, Chicago II, USA). One-way analysis of variance was used for the differences between groups. When the F values significant, Duncan's multiple range test was performed. All data were expressed as means±SEM. Differences were considered as significant when the p-value was less than 0.05.

RESULTS

As shown in Table 2, while BW, BWG and FC were decreased (p<0.001), FCR was increased significantly (p<0.05) in Cd group compared with the control group. There was no significant change in performance parameters among Cd, Cd+vit C and Cd+vit E groups.

Although liver Cd level increased insignificantly (p>0.05) plasma and kidney Cd level were increased significantly (p<0.001) in Cd group compared with the control group. While the plasma, liver and kidney Cd level (p<0.001) was reduced by vit C supplementation, only plasma Cd level was decreased by vit E supplementation compared with the Cd group (p<0.001) (Table 3).

While plasma AST (p<0.05) and GGT (p<0.01) activities were increased in Cd-only group compared with the control group, addition of vit C and vit E to this group reduced the plasma GGT activity. Cadmium did not cause significant changes in the ALT activities and total protein, total cholesterol, creatinine levels (Table 4).

In histopathological examinations specific lesions were not observed in control group (Fig. 1). Prominent changes were observed in kidney and liver tissue of Cd treated group. Severe hydropic

Table 2: Growth performance of broiler chicks affected by Cd, vit C and vit E supplementation at the end of the experiment

Parameters	Control (min-max)	Cd (min-max)	Cd+vit C (min-max)	Cd+vitE (min-max)	p-value
BW (g)	2393.05±56.79 ^a (2009.80-2629.80)	1828.75±40.11 ^b (1622.25-1936.00)	1852.33±56.30 ^b (1765.86-1982.40)	1780.00±23.21 ^b (1622.00-1893.00)	***
BWG (g)	2284.74±56.79 ^a (1899.00-2616.72)	1750.54±40.11 ^b (1067.90-2202.04)	1799.38±54.07 ^b (1360.66-2120.05)	1818.71±23.21 ^b (1265.21-2154.50)	***
FC (g)	3769.89±42.14 ^a (3740.67-3811.50)	3236.15±69.59 ^b (3186.83-3296.00)	3304.29±40.50 ^b (3223.67-3344.50)	3331.72±30.9 ^b (3259.17-3403.67)	***
FCR (FC/BWG)	1.65±0.08 ^b (1.63-1.66)	1.85±0.05 ^a (1.82-1.88)	1.84±0.04 ^a (1.74-2.02)	1.84±0.06 ^a (1.76-1.91)	*

a,b: Means within row with different superscripts are significantly different. *: p<0.05; ***:p<0.001, BW: Body weight, BWG: Body weight gain, FC: Feed consumption FCR: Feed conversion ratio

Table 3: Cadmium concentrations in the liver, kidney (wet weight), plasma samples of broilers

Tissue (n = 9)	Control (min-max)	Cd (min-max)	Cd+Vit C (min-max)	Cd+VitE (min-max)	p-value
Liver (mg kg ⁻¹)	2.64±0.48 ^a (0.81-4.95)	3.30±0.20 ^a (2.40-4.28)	1.05±0.21 ^b (0.58-2.62)	3.23±0.41 ^a (0.76-4.65)	***
Kidney (mg kg ⁻¹)	3.66±0.29 ^b (2.20-4.66)	5.10±0.54 ^a (2.05-6.90)	2.54±0.42 ^b (0.69-3.96)	4.95±0.32 ^a (3.79-6.00)	***
Plasma (mg L ⁻¹)	0.11±0.01 ^c (0.01-0.15)	0.20±0.01 ^a (0.15-0.25)	0.16±0.01 ^b (0.13-0.19)	0.11±0.01 ^c (0.08-0.14)	***

a,b,c: Mean values within the same row with different superscripts are significantly different. ***: p<0.001

Table 4: The effects of Cd, vit C and vit E on some plasma biochemical parameters of broilers

Parameters (n = 12)	Control (min-max)	Cd (min-max)	Cd+vit C (min-max)	Cd + vit E (min-max)	p-value
AST (IU L ⁻¹)	179.49±3.74 ^b (154.35-195.40)	198.34±5.51 ^a (157.93-230.86)	198.95 ± 6.72 ^a (142.19-226.77)	206.39±7.61 ^a (160.02-244.01)	*
ALT (IU L ⁻¹)	9.29±0.81 (5.34-13.74)	10.47±1.12 (4.71-16.93)	10.29±1.05 (2.28-16.02)	10.36±0.81 (6.17-14.78)	NS
GGT (IU L ⁻¹)	26.64±1.58 ^b (14.76-35.58)	34.11±1.30 ^a (26.43-41.19)	29.42±1.94 ^b (21.73-43.75)	26.45±1.42 ^b (20.16-37.45)	**
Total protein (g dL ⁻¹)	3.23±0.84 (2.57-3.61)	2.90±0.15 (2.20-3.92)	3.26±0.14 (1.95-3.70)	3.15±0.15 (2.09-3.87)	NS
Total cholesterol (mmol L ⁻¹)	2.39±0.12 (1.61-2.89)	2.44±0.09 (2.07-3.23)	2.40±0.04 (1.96-2.76)	2.39±0.07 (1.93-2.84)	NS
Creatinine (mmol L ⁻¹)	52.16±1.77 (43.32-63.65)	53.92±2.65 (43.32-70.72)	59.23±1.50 (47.74-70.72)	54.81±0.26 (43.32-70.72)	NS

^{a,b}: Mean values within the same row with different superscripts are significantly different. NS: Not significant, p>0.05; *: p<0.05; **: p<0.01

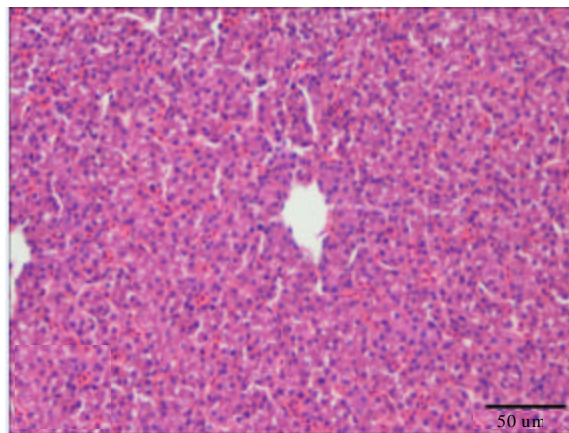


Fig. 1: Liver tissue from control group. There was no specific lesions except limited hyperemia. H-E

degeneration was observed in liver tissue in Cd group (Fig. 2). In kidney, histopathological changes were seen in glomeruli, tubuli and interstitial tissue. There was thickening of the glomerular basement membranes and hypercellularity (Fig. 3). Epithelial degeneration of the tubules and intracytoplasmic hyaline droplets were detected in many tubules. Basement thickening was also seen in tubular basement membranes. In addition, hyaline casts were detected within the some tubules (Fig. 4). Some degenerative and necrotic changes, especially, picnosis, were observed in kidney in Cd+vit C group (Fig. 5). In liver, hydropic degeneration was also detected. Similar changes with Cd group were observed in Cd+vit E group. There was hypercellularity and thickening of the basement membrane of some glomeruli. Picnosis was marked in the nuclei of the tubular epithelial cells (Fig. 6). Hydropic degeneration of the hepatocytes in the liver was seen also in this group. The severity of histopathological changes in liver and kidney tissues of experimental groups were presented at Table 5. Prominent difference in histopathological changes between the experimental groups was not detected in this study. However, there was a slight decrease in hepatocyte degeneration when compared the other treatment groups.

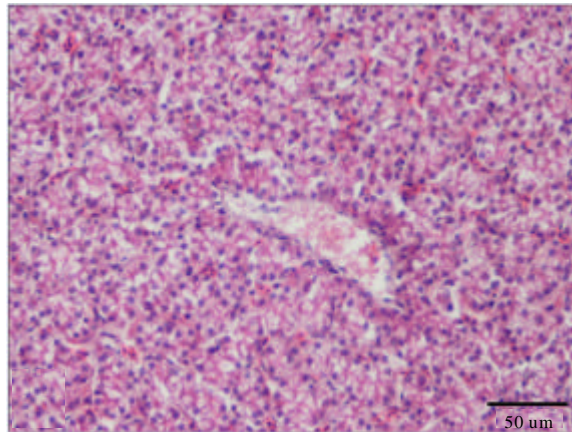


Fig. 2: Liver tissue from Cd group. Hydropic degeneration in the liver. H-E

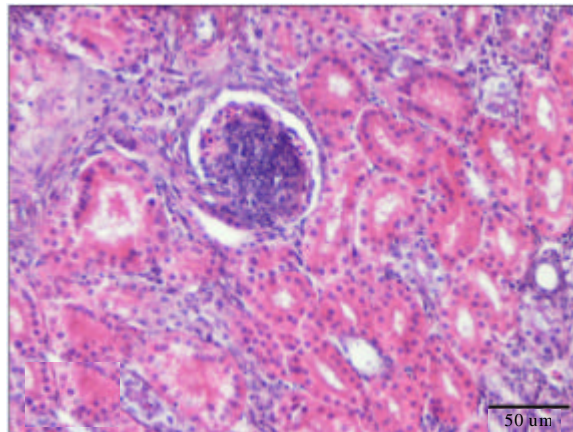


Fig. 3: Kidney tissue from Cd group. Thickening of the basement membrane of the glomerulus. H-E

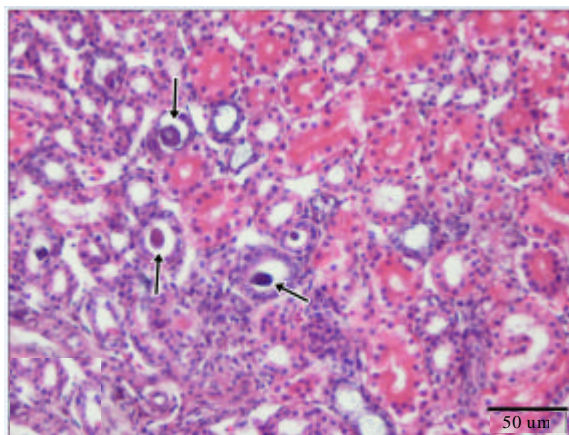


Fig. 4: Kidney tissue from Cd group. Hyaline casts in the lumens

Table 5: The comparison of histopathological changes in liver and kidney tissues in control and experimental groups

Histopathological finding	Control	Cd	Cd+vitC	Cd+vitE
Liver				
Hepatocyte degeneration	-	+++	++	+++
Kidney				
Thickening of the basement membrane	-	++	++	++
Hyaline droplet or cylinders	-	+	+	+
Epithelial degeneration	-	++	++	++
Pycnosis	-	++	++	++

:- Absent, +: Moderate, ++: High, +++: Very high

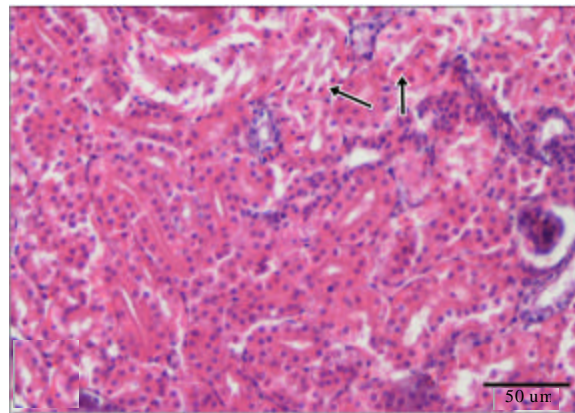


Fig. 5: Kidney tissue from Cd+vit C group Pycnosis in some nuclei (arrows). H-E

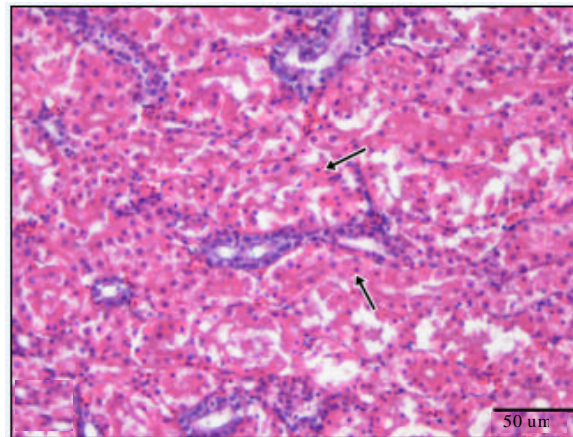


Fig. 6: Kidney tissue from Cd+vit E group. Epithelial degeneration and pyknosis in many nuclei (arrows). H-E

DISCUSSION

In this study, Cd administration significantly decreased the BW. Vitamin C and vit E addition to the diet did not recover the depressive effect of Cd on BW, BWG and FC. Uyanik *et al.* (2001) showed that prolonged dietary Cd (50, 75, 100 mg kg⁻¹) exposure resulted in a significantly decrease in BW. Vodela *et al.* (1997) and Erdogan *et al.* (2005) observed that drinking water with

Cd decreased the FC and BWG of broilers. Also, Erdogan *et al.* (2005) reported that prolonged Cd administration to the drinking water (25 mg L^{-1}) decreased the BW of broilers and ascorbic acid (200 mg kg^{-1}) did not alleviate these negative effects of Cd. In this study, the performance results are in agreement with these findings. Grosicki (2004) indicated that supplemented with 1.5 mg dL^{-1} ascorbic acid to the diet including 10 mg kg^{-1} Cd, improved the growth rate in rats. This result conflicts with our result. Vitamin C precursor is synthesized in the body of rats so this discrepancy is may be due to the different species used in this study. In the present study, the observed reduction in BW in experimental groups could have been due to the decrease in FC of broilers (Uyanik *et al.*, 2001) or due to the toxic effects of Cd on virtually every systems in animal body (Erdogan *et al.*, 2005). Also, Akyolcu *et al.* (2003) showed that administration of Cd decreased the BWG of affected broiler chickens, because of the accumulation of Cd in several organs (e.g., liver, kidney) was also observed. These results are in agreement with our study.

Metallothioneins, a metal binding protein, from complexes with heavy metal (Markant and Pallauf, 1996). In the body, large quantities of metallothionein are induced primarily in the liver and kidneys (Bobillier-Chaumont *et al.*, 2006). Cadmium mainly accumulates in the liver and kidneys. Deposition of Cd in these tissues may be result from the binding of Cd to metallothionein (Hardej and Trombetta, 2004). While Herzig *et al.* (2007) reported that Cd accumulation had been seen primarily in the liver, the others (Bilal and Ercag, 2003; Erdogan *et al.*, 2005) indicated that Cd accumulation is higher in the kidneys of broilers. However, Uyanik *et al.* (2001) observed that Cd accumulation had been seen both in kidneys and liver. In the present study, the kidney Cd accumulation was prominent. Although the increase was not statistically significant, liver Cd level was raised in Cd-only group compared with the control group. These results were compatible with findings Herzig *et al.* (2007) who reported the elevated Cd in the liver. Yamano *et al.* (2000) showed that liver injury caused by exposure to Cd is associated with activation of Kupffer cells. While, Nordberg *et al.* (1992) reported that a $10\text{-}300 \text{ }\mu\text{g g}^{-1}$ Cd in kidney can induced nephrotoxicity. In present study the Cd level in kidney was about 5 mg kg^{-1} (lower than 10 mg kg^{-1}), so no biochemical changes in kidney parameters had been seen in the plasma of Cd induced broilers. This is in agreement with Erdogan *et al.* (2005) who observed that 10 mg kg^{-1} Cd accumulation in kidney caused no biochemical changes in kidney parameters in blood.

Vitamin C is one of the most effective factor in reducing enhanced renal and hepatic Cd levels (Kapl *et al.*, 1994). In this study, the addition of vit C to the diet with Cd, prevented the accumulation of this metal in the analyzed tissues and plasma. This result is in agreement with the findings of Rambeck and Guillot (1996) who showed that $1 \text{ g Vit C kg}^{-1}$ feed lowered Cd accumulation in the kidney and liver. Kadrabova *et al.* (1992) in guinea pig and Fox *et al.* (1980) in Japanese quail reported that ascorbic acid could be effective in decreasing Cd accumulation in the kidney. Vitamin C produces complexes with heavy metal cations (McDowell, 2000). The decrease of Cd in Cd+vit C group as Kadrabova *et al.* (1992) suggested that vit C decreases the toxic effect of Cd by producing complexes with heavy metal cations which facilitates its elimination from the organism, also it probably reduces the absorption of Cd from the gastrointestinal tract.

Tandon *et al.* (1992) and Kim *et al.* (2003) and indicated that the accumulation of Cd in rat liver, kidney and blood was reduced by vit E supplementation. Vitamin E supplementation to the diet prevented Cd accumulation in only plasma in this study. This reduced accumulation of Cd in blood under the influence of vit E might be due to the excretion of Cd via urine and feces. The decrease of Cd in liver and kidneys by the supplementation of vit E may be due to the higher dose of vit E used in this study.

Cadmium is one of the heavy metals which induce membrane damage (Girault *et al.*, 1998). In several organs, cell damage is followed by release of a number of cytoplasmic enzymes to the blood, this provides the basis for clinical diagnosis (Sundberg *et al.*, 1994). In present study, the increase in plasma AST and GGT activities were in concurred with the results of Uyanik *et al.* (2001) and Pari and Murugavel (2005) in broilers and Tandon *et al.* (1992) in rats who reported elevated these enzymes. Our results demonstrated that exposure to Cd caused liver damage as supported by the pathological finding, characterised by hepatocyte degeneration in liver. The increases in plasma AST and ALT activities is attributable to the outflow of these enzymes from the liver cytosol to the blood (Navarro *et al.*, 1993). This may be result from hepatotoxic effect of Cd (El-Demerdash *et al.*, 2004). In several reports, administration of antioxidants like vit E, β -carotene (El-Demerdash *et al.*, 2004) and diallyl tetrasulfide (Pari and Murugavel, 2005) to diet with Cd significantly decreased the plasma activities of AST, ALT (El-Demerdash *et al.*, 2004; Pari and Murugavel, 2005) and GGT (Pari and Murugavel, 2005). These antioxidants may stabilize the hepatic cellular membrane and protect the hepatocytes against toxic effects of Cd which may decrease the leakage of the enzymes into blood stream (Pari and Murugavel, 2005). In this study, while GGT activities decreased in both vitamin supplemented groups. Although Nemmiche *et al.* (2007) reported that the activities of AST and ALT in serum were significantly elevated after Cd exposure and these values were decreased by the administration of 100 mg/kg/bw/day vit E in rats, there were no changes in AST and ALT enzymes by the addition of vit C and E in this study. Like Nemmiche *et al.* (2007), similar results have been reported by Tandon *et al.* (1992). This difference may be because of the vit E dose used in this study. According to Rana *et al.* (1996) antioxidants succeeded in restricting the efflux of transaminases from liver to blood. This observation confirm with our results. The GGT activity was higher in Cd exposed group than other experimental groups. Gamma glutamyl transpeptidase may also induced the generation of free radicals in the presence of iron and other transition metals (Lee *et al.*, 2004). The increase in the activity of GGT in Cd group may be due to the oxidative effect. The lower activity of GGT in Cd+vit C and Cd+vit E groups may be attributed to the antioxidant effects of vit C and E.

Histopathological changes at this study are in agreement with previous reports (Yilmaz *et al.*, 1999; Uyanik *et al.*, 2001; Gubrelay *et al.*, 2004). These lesions were hepatocyte degeneration in liver, thickening of the glomerular and tubular basement membranes, hypercellularity of the glomeruli and pyknotic changes of the tubular epithelium in kidney. Prominent difference in histopathological changes between the experimental groups was not detected in this study. The reason for this can be applied in high doses for a long time. Nevertheless, there was a slight decrease in hepatocyte degeneration when compared the other treatment groups.

CONCLUSION

In this study, administration of 60 mg kg⁻¹ Cd in diet resulted in suppression of performance, increased plasma Cd levels induced Cd accumulation in the liver and kidneys. In these reason there was some pathological changes of them. While vit C (400 mg kg⁻¹) and vit E (250 mg kg⁻¹) supplementation to the diet did not prevent the adverse effects of Cd on performance and tissue changes, vit C decreased the plasma, liver and kidney Cd accumulation. However, vit E had no beneficial effects against liver and kidney tissues. It has been suggested that vit C is more effective than vit E against Cd intoxication in broilers.

ACKNOWLEDGMENTS

This study was supported by the Kirikkale University Research Fund, Project No: 2005/10. Some part of the data of this article was presented as an abstract at the 3rd Veterinary Biochemistry and Clinic Biochemistry Congress. Konya, Turkey.

REFERENCES

- AOAC., 2006. Official Methods of Analysis. 18th Edn., Association of Official Analytical Chemists Inc., Arlington, TX., USA.
- Akyolcu M.C., D. Ozcelik, S. Dursun, S. Toplan and R. Kahraman, 2003. Accumulation of cadmium in tissue and its effect on live performance. *J. Phys.*, 107: 33-36.
- Al-Attar, A.M., 2005. Biochemical effects of short-term cadmium exposure on the freshwater fish, *Oreochromis niloticus*. *J. Biological Sci.*, 5: 260-265.
- Al-Khedhairy, A.A., S.A. Al-Rokayan and F.A. Al-Misned, 2001. Cadmium toxicity and cell stress response. *J. Medical Sci.*, 1: 39-43.
- Anonymous, 1991. Animal feeds determination of metabolisable energy (Chemical method). Turkish Standart Institute (TSE). Publ. No. 9610, pp: 1-3.
- Appenroth, D., E. Karge, G. Kiesling, W.J. Wechter, K. Winnefeldand and C. Fleck, 2001. LLU- α , an endogenous metabolite of α -tocopherol, is more effective against metal nephrotoxicity in rats than α -tocopherol. *Toxicol. Lett.*, 122: 255-265.
- Bilal, T. and E. Ercag, 2003. Retention of cadmium in the tissues of broiler chicks by dietary supplemental microbial phytase. *Vet. Med-Czech*, 48: 199-205.
- Bobillier-Chaumont, S., V. Maupoil and A. Berthelot, 2006. Metallothionein induction in the liver, kidney, heart and aorta of cadmium and isoproterenol treated rats. *J. Appl. Toxicol.* 26: 47-55.
- Cinar, M., 2003. Cadmium and effects at biological system. *Veterinarium*, 14: 79-84.
- Cinar, M., A.A. Yigit and G. Eraslan, 2010. Effects of vitamin C or vitamin E supplementation on cadmium induced oxidative stress and anaemia in broilers. *Revue. Med. Vet.*, 161: 449-454.
- El-Demerdash, F.M., M.I. Yousaf, S.K. Fatma and H.B. Hoda, 2004. Cadmium-induced changes in lipid peroxidation, blood hematology, biochemical parameters and semen quality of male rats: Protective role of vitamin E and-carotene. *Food Chem. Toxicol.*, 42: 1563-1571.
- Erdogan, Z., S. Erdogan, S. Celik and V. Unlu, 2005. Effects of ascorbic acid on cadmium-induced oxidative stress and performance of broilers. *Biol. Trace Elem. Res.*, 104: 19-31.
- Eriyamremu, G.E., M.A. Adaikpoh and F.O. Obi, 2006. Pretreatment of Rats with α -tocopherol alter liver and kidney protein, alkaline phosphatase activity and phospholipid profile after 24 h intoxication with cadmium. *J. Medical Sci.*, 6: 615-620.
- Fox, M.R.S., M.J. Richard, R.M. Jacobs, A.O.L. Jones and B.E. Fry, 1980. Effects of vitamin C and iron on cadmium metabolism. *Ann. N.Y. Acad. Sci.* 355: 249-261.
- Girault, L., A. Boudou and E.J. Dufourc, 1998. ¹¹³Cd-, ³¹P-NMR and fluorescence polarization studies of cadmium (II) interactions with phospholipids in model membranes. *Biochim. Biophys. Acta*, 1414: 140-154.
- Grosicki, A., 2004. Influence of Vitamin C on cadmium absorption and distribution in rats. *J. Trace Elem. Med. Biol.*, 18: 183-187.
- Gubrelay, U., A. Mehta, M. Singh and S. Flora, 2004. Comparative hepatic and renal toxicity of cadmium in male and female rats. *J. Environ. Biol.*, 25: 65-73.
- Hardej, D. and L.D. Trombetta, 2004. Metals. In: *Clinical Toxicology Principles and Mechanism*, Barile, F.A. (Ed.). CRC Press, USA., pp: 295-317.

- Herzig, I., M. Navratilova, P. Suchy, V. Vecerek and J. Totusek, 2007. Model trial investigating retention in selected tissues using broiler chicken fed cadmium and humic acid. *Vet. Medicina*, 52: 162-168.
- Hooser, S.B., 2007. Cadmium. In: *Veterinary Toxicology*, Gupta, R.C. (Ed.). Macmillan Company, USA., pp: 422-427.
- Jiraungkoorskul, W., S. Sahaphong, P. Kosai and M.H. Kim, 2007. The effect of ascorbic acid on cadmium exposure in the gills of *Puntius altus*. *Int. J. Zool. Res.*, 3: 77-85.
- Joshi, P.K. and M. Bose, 2002. Toxicity of cadmium: A comparative study in the air breathing fish, *Clarias batrachus* and in non-air breathing one, *Ctenopharyngodon idellus*. *Proceedings of the Symposium on Aquatic Toxicology: Mechanism and Consequences, (ATMC'02)*, The Applied Linguistics Association of Korea (ALAK), Korea, pp: 109-118.
- Kadrabova, J., A. Madaric and E. Ginter, 1992. The effect of ascorbic acid on cadmium accumulation in guinea pig tissues. *Experientia*, 48: 989-991.
- Kapl, D., H. Weiser and W.A. Rambeck, 1994. The influence of vitamin C on cadmium retention in pigs. *Rev. Med. Vet.*, 145: 291-297.
- Kaplan, O., N.C. Yildirim, N. Yildirim and M. Cimen, 2011. Toxic elements in animal products and environmental health. *Asian J. Anim. Vet. Adv.*, 6: 228-232.
- Kaya, S., I. Pirincci, B. Tras, A. Unsal and A. Bilgili *et al.*, 2002. Metals, Other Inorganic ve Radyoactive Agents. In: *Toxicology in Veterinary Medicine*, Kaya, S., I. Pirincci and A. Bilgili (Eds.). 2nd Edn., Medisan Press, Ankara, pp: 207-250.
- Kim, M.J., J.H. Hong, S.J. Rhee, 2003. Effect of vitamin E on cadmium accumulation and excretion in chronic cadmium poisoned rats. *Korean J. Nutr.*, 36: 691-698.
- Lee, D.H., R. Blomhoff and D.R. Jr. Jacobs, 2004. Is serum gamma glutamyltransferase a marker of oxidative stress. *Free Radic. Res.*, 38: 535-539.
- Li, J.L., R. Gao, S. Li, J.T. Wang, Z.X. Tang and S.W. Yu, 2010. Testicular toxicity induced by dietary cadmium in cocks and ameliorative effect by selenium. *Biometals*, 23: 695-705.
- Luna, L.G., 1968. *Manual of Histologic Staining Methods of the Armed Forces Institute of Pathology*. 3rd Edn., McGraw-Hill Book Company, New York, USA., pp: 32-39.
- Markant, A. and J. Pallauf, 1996. Metallothionein and zinc as potential antioxidants in radical-induced lipid peroxidation in cultured hepatocytes. *J. Trace Elem. Med. Biol.*, 10: 88-95.
- McDowell, L.R., 2000. *Vitamins in Animal and Human Nutrition*. 2nd Edn., Iowa State University Press, Ames, Iowa.
- Morales, A.I., C. Vicente-Sánchez, J.M. Sandoval, J. Egido and P. Mayoral *et al.*, 2006. Protective effect of quercetin on experimental chronic cadmium nephrotoxicity in rats is based on its antioxidant properties. *Food Chem. Toxicol.*, 44: 2092-2100.
- NRC, 1994. *Nutrient Requirements of Poultry*. 9th Edn., National Academy Press, Washington, DC. USA., ISBN-13: 978-0-309-04892-7.
- Navarro, C.M., P.M. Montilla, A. Martin, J. Jimenez and P.M. Utrilla, 1993. Free radicals scavenger and antihepatotoxic activity of rosmarinus. *Plant Med.*, 59: 312-314.
- Nemmiche, S., D. Chabane-Sari and P. Guiraud, 2007. Role of α -tocopherol in cadmium-induced oxidative stress in Wistar rat's blood, liver and brain. *Chem. Biol. Interac.*, 170: 221-230.
- Nordberg, M., T. Jin and G.F. Nordberg, 1992. Cadmium metallothionein and renal tubular toxicity. *IARC Sci.Publ.*, 118: 293-297.
- Ognjanovic, B.I., S.Z. Pavlovic, S.D. Maletic, R.V. Zikic and A.S. Stajn *et al.*, 2003. Protective influence of vitamin E on antioxidant defense system in the blood of rats treated with cadmium. *Physiol. Res.*, 52: 563-570.

- Pari, L. and P. Murugavel, 2005. Role of diallyl tetrasulfide in ameliorating the cadmium induced biochemical changes in rats. *Environ. Toxicol. Pharmacol.*, 20: 493-500.
- Perkin Elmer Corporation, 2000. *Analytical Methods for Atomic Absorption Spectrophotometer*. Norwalk, CT.
- Rambeck, W.A. and I. Guillot, 1996. Bioavailability of cadmium: effect of vitamin C and phytase in broiler chickens. *Tierarzt Praxis*. 24: 467-470.
- Rana, S.V., R. Singh and S. Verma, 1996. Protective effects of few antioxidants on liver function in rat treated with cadmium and mercury. *Indian J. Exp. Biol.*, 34: 177-179.
- Rao, M.V. and P.S. Sharma, 2001. Protective effect of vitamin E against mercuric chloride reproductive toxicity in male mice. *Reprod. Toxicol.*, 15: 705-712.
- Sundberg, A., E.L. Appelkwist, G. Dallner and R. Nilsson, 1994. Glutathione transferase in urine: Sensitive methods for detection of kidney damage induced by nephrotoxic agents in human. *Environ. Health Perspect.*, 102: 293-296.
- Tandon, S.K., S. Singh and M. Dhawan, 1992. Preventive effect of Vitamin E in cadmium intoxication. *Biomed. Environ. Sci.*, 5: 39-45.
- Uyanik, F., M. Eren, A. Atasever, G. Tuncoku and A.H. Kolsuz, 2001. Changes in some biochemical parameters and organs of broilers exposed to cadmium and effect of Zinc on cadmium induced alteration. *Isc. J. Vet. Med., Assoc.* 56: 128-134.
- Vodela, J.K., S.D. Lenz, J.A. Rendenr, W.H. Mcelhenney and B.W. Kemppainen, 1997. Drinking water contaminants (arsenic, cadmium, lead, benzene and trichloroethylene). 1. Interaction of contaminants with nutritional status on general performance and immune function in broiler chickens. *Poult. Sci.*, 76: 1474-1492.
- Wershana, K.Z., 2001. Cadmium induced toxicity on pregnant mice and their offspring: Protection by magnesium or vitamin E. *J. Medical Sci.*, 1: 179-186.
- Yamano, T., L.A. Decicco and L.E. Rikans, 2000. Attenuation of cadmium-induced liver injury in senescent male Fisher 344 rats: role of Kupffer cells and inflammatory cytokines. *Toxicol. Applied Pharmacol.* 162: 68-75.
- Yilmaz, F., G. Ozturk and H. Ozer, 1999. Pathological examination of experimentally-induced cadmium toxication in mice. *Fyrat Univ. Med. J. Health Sci.*, 13: 271-276.