



REVISTA BRASILEIRA DE ANESTESIOLOGIA

Official Publication of the Brazilian Society of Anesthesiology
www.sba.com.br



CLINICAL INFORMATION

Anesthesia for a child with Walker–Warburg syndrome

Emine Arzu Kose^{a,*}, Bulent Bakar^b, Gokay Ates^a, Didem Aliefendioglu^c, Alpaslan Apan^a

^a Department of Anesthesiology and Reanimation, School of Medicine, Kirikkale University, Kirikkale, Turkey

^b Department of Neurosurgery, School of Medicine, Kirikkale University, Kirikkale, Turkey

^c Department of Neonatology, School of Medicine, Kirikkale University, Kirikkale, Turkey

Received 30 October 2012; accepted 19 December 2012

Available online 11 October 2013

KEYWORDS

Walker–Warburg Syndrome;
Congenital muscular dystrophy;
General anesthesia

Abstract

Background and objectives: Walker–Warburg Syndrome is a rare, autosomal recessive congenital muscular dystrophy manifested by central nervous system, eye malformations and possible multisystem involvement. The diagnosis is established by the presence of four criteria: congenital muscular dystrophy, type II lissencephaly, cerebellar malformation, and retinal malformation. Most of the syndromic children die in the first three years of life because of respiratory failure, pneumonia, seizures, hyperthermia and ventricular fibrillation.

Case report: The anesthetic management of a two-months-old male child listed for elective ventriculo-peritoneal shunt operation was discussed.

Conclusions: A careful anesthetic management is necessary due to the multisystem involvement. We reported anesthetic management of a two-months-old male child with Walker–Warburg Syndrome who was listed for elective ventriculo-peritoneal shunt operation.

© 2013 Sociedade Brasileira de Anestesiologia. Published by Elsevier Editora Ltda.

Este é um artigo Open Access sob a licença de [CC BY-NC-ND](http://creativecommons.org/licenses/by-nc-nd/3.0/)

Introduction

Walker–Warburg Syndrome (WWS) is a rare, autosomal recessive congenital muscular dystrophy (CMD).¹ The diagnosis is generally depends on clinical manifestations, genetic diagnosis has been made by DNA analysis only in 10–20% of the cases. The diagnosis is established by the presence of four criteria: CMD, type II lissencephaly, cerebellar malformation, and retinal malformation.² The other frequently

observed abnormalities are ventricular dilatation with or without hydrocephalus, anterior chamber malformation of eye, congenital macrocephaly, Dandy–Walker malformation. Congenital microcephaly, microphthalmia, ocular coloboma, congenital cataract, urogenital anomalies, cleft lip and cleft palate are the less frequently observed abnormalities. Differential diagnosis with Fukuyama CMD, muscle-eye-brain disease, cerebro-ocular-cerebral syndrome is depend on the severity of the clinical manifestations and radiological findings.^{2,3} Clinical manifestation are present at birth or or appears after in a short period. Most of the syndromic children dies in the first three years of life because of respiratory failure, pneumonia, seizures, hyperthermia and

* Corresponding author.

E-mail: arzuhct@hotmail.com (E.A. Kose).

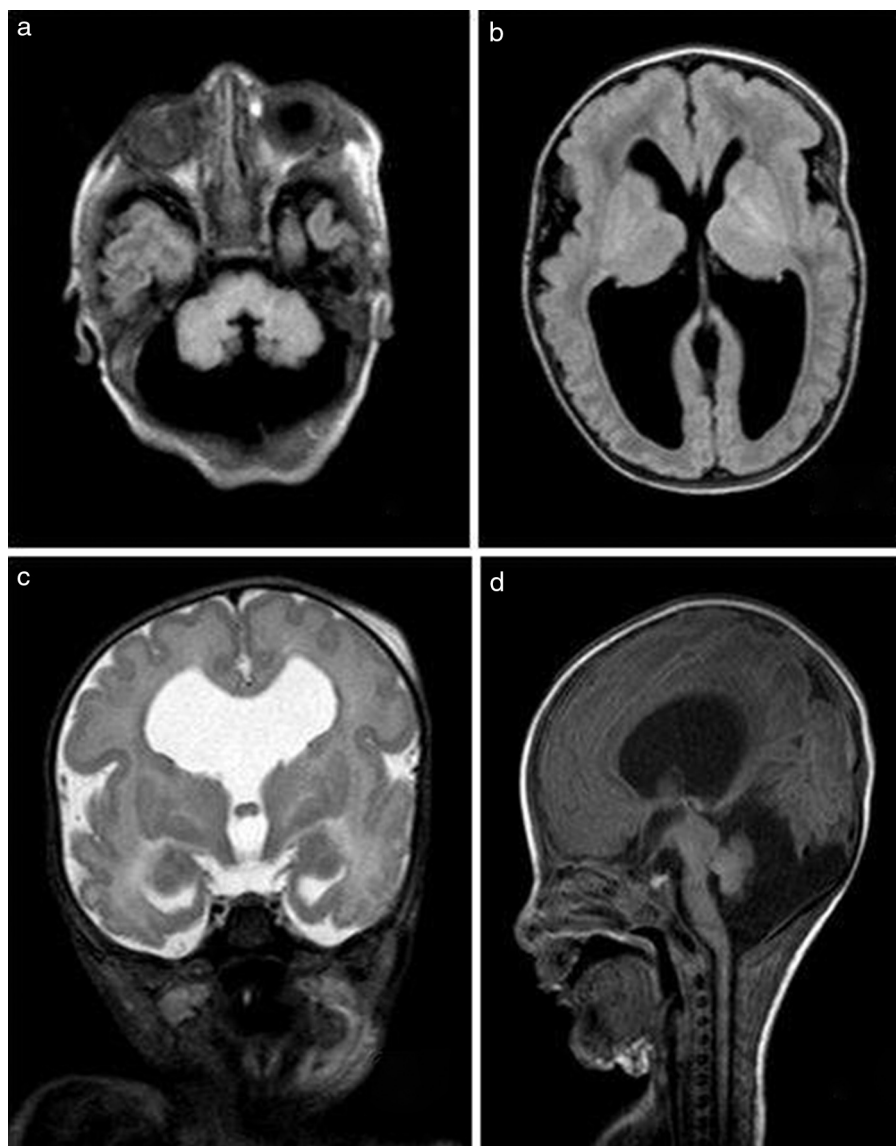


Figure 1 FLAIR MR scan images demonstrating Dandy–Walker abnormality (A and D); and lissencephaly with hydrocephalus (B). T2 WI MR scan image demonstrating septum pellucidum dysgenesis (C).

ventricular fibrillation. Prenatal diagnosis is possible and the risk of having another child with this syndrome is 25% in the families with one affected child.⁴

Case report

A two-months-old male child weighing 3.3 kg was listed for elective ventriculo-peritoneal shunt operation. Delivery had been by cesarean section at the 38th weeks of gestation. The mother's previous gestation had been ended by medical abortus due to determined hydrocephalus by ultrasonographic evaluations and the parents were relative. The patient was admitted to intensive care unit of newborn because of hydrocephalus and respiratory distress. Macrocephalia, low nasal bridge, frontal bulging of the forehead, micrognathia, receding mandible, moderate hypotonia, and bilateral retinal detachment were determined by physical

examination. Creatine phosphokinase (CPK) levels were measured as 4226 u L^{-1} (normal $24\text{--}195 \text{ u L}^{-1}$). Magnetic resonance imaging (MRI) was revealed type II lissencephaly, hypomyelination of white matter, dilated ventricles, bilateral cerebellar hypoplasia, agenesis of septum pellucidum, Dandy–Walker malformation, bilateral hyperplasia of vitreous and buphthalmus (Fig. 1).

After obtaining written informed parental consent, the patient was fasted for 3 h. The probability of difficult intubation was thought and equipment was prepared. Following the monitorization of pulse oxymetry, noninvasive blood pressure, electrocardiography, body temperature, anesthesia induction was made with sevoflurane and nitrous oxide in oxygen. An intravenous cannula was inserted and laryngoscopy was performed during spontaneous ventilation. The intubation attempts performed using traditional midline approach with anterior cervical pressure and increased extension of head were failed, view was evaluated as grade

4. Therefore, the patient's head was slightly turned to left and Miller size zero straight blade was introduced extreme right side of the mouth. The tip of the epiglottis visualized by the aid of the external manipulation of the larynx and blind intubation was performed by using a 3.5 mm uncuffed endotracheal tube. The endotracheal tube placement was confirmed with capnography and auscultation of lungs. The endotracheal tube was fixed and an oropharyngeal throat pack was inserted. Anesthesia was maintained with sevoflurane 2% with oxygen and nitrous oxide mixture in the ratio of 50:50. Neither neuromuscular blocker agents nor opioids were used during the surgery. Fluid management was made intravenous administration of balanced electrolyte solution regarding the calculation of the perioperative fluid deficits and basal requirement of the child. At the end of the surgery, the throat pack was removed, and the trachea was extubated when the patient was full-awake. Postoperative analgesia was provided with paracetamol 25 mg kg⁻¹. After a uneventful recovery period, the patient was taken into the intensive care unit.

Discussion

A careful anesthetic management is necessary due to the multisystem involvement. Difficult airway should always keep in mind because of short neck, micrognathia, receding mandible and sometimes accompanied cleft lip and/or cleft palate. After the difficult intubation preparation, we preferred inhalation induction with sevoflurane without suppression of spontan ventilation. Due to the intrusion possibility of a curved blade into the view line, Miller size zero straight blade was used but visualization of larynx could not be provided by the traditional midline approach. Therefore, paraglossal straight blade laryngoscopy described in difficult tracheal intubation was used and blind intubation was performed after visualization of the tip of the epiglottis.⁵ Lateral approach was provided to bypass the tongue and maxillary structures and improved view of the glottis. In case of unsuccessful intubation, our back-up plan was to perform fiber-optic laryngoscopy. The use of laryngeal mask airway was discussed but was not preferred because to provide a safe airway could be impossible due to the movements of head during the operation and the probability of the aspiration of the oropharyngeal secretions. To use the succinylcholine was avoided because it can cause exaggerated potassium release, fatal cardiac dysrhythmias and malin hyperthermia. Because of the increased

hyperthermia risk in WWS, body temperature was monitored during the surgery and postoperative period.^{2,3} Nondepolarizing muscle relaxants and opioids were not used due to the possibility of delayed recovery and postoperative respiratory depression resulting from the chronic weakness of respiratory muscles.^{2,3} Postoperative analgesia was provided with paracetamol, heavy sedation was avoided. Postoperative pulmonary dysfunction and consequent aspiration pneumonia was kept in the mind and oropharyngeal secretions were suctioned regularly.

Although, our patient had not any cardiac or genitourinary abnormality, renal dysfunction and involvement of cardiac muscles can observe in WWS and it is important to recognize the increased perioperative cardiac and renal failure risk.² Maintenance of adequate fluid management should be provide to avoid the renal dysfunction and cardiovascular depression.

Children with WWS may have increased intracranial pressure (ICP), so anesthetic management should include the precautions to provide adequate cerebral circulation such as to avoid the excessive decrease or increase in mean arterial pressure.³ It is also important to recognize that the patients with WWS are prone to develop seizures, episodes of central and obstructive apnea, difficulty in swallowing and consequent cardiorespiratory failure, aspiration pneumonia and sepsis.^{2,3} It should be avoid the use of the epileptogenic drugs and hypoxic episodes which can lead to seizures.

In summary, for an unevenful anesthetic management and postoperative care it should be keep in mind that WWS is a severe CMD with multisystemic involvement.

Conflicts of interest

The authors declare no conflicts of interest.

References

1. Walker AE. Lissencephaly. *Arch Neurol Psychiatry*. 1942;48:13–29.
2. Dobyns WB, Pagon RA, Armstrong D, et al. Diagnostic criteria for Walker–Warburg syndrome. *Am J Med Genet*. 1989;32:195–210.
3. Sahajanda H, Meneges J. Anaesthesia for a child with Walker–Warburg syndrome. *Pediatr Anesth*. 2003;13:624–8.
4. Crowe C, Jassani M, Dickerman L. The perinatal diagnosis of the Walker–Warburg syndrome. *Diagnosis*. 1986;6:177–85.
5. Henderson J. The use of paraglossal straight blade laryngoscopy in difficult tracheal intubation. *Anaesthesia*. 1997;52:522–6.