



# REVISTA BRASILEIRA DE ANESTESIOLOGIA

Official Publication of the Brazilian Society of Anesthesiology  
[www.sba.com.br](http://www.sba.com.br)



## CLINICAL INFORMATION

# Life-threatening acute subdural haematoma after combined spinal–epidural anaesthesia in labour

Bulent Bakar<sup>a,\*</sup>, Esra Ozer<sup>b</sup>, Ismail Hakki Tekkok<sup>c</sup>

<sup>a</sup> Department of Neurosurgery, Faculty of Medicine, Kirikkale University, Kirikkale, Turkey

<sup>b</sup> Department of Anaesthesiology and Reanimation, TOBB-ETU Hospital, Ankara, Turkey

<sup>c</sup> Department of Neurosurgery, TOBB-ETU Hospital, Ankara, Turkey

Received 7 February 2013; accepted 9 July 2013

Available online 16 October 2013

### KEYWORDS

Combined  
spinal–epidural  
anaesthesia;  
Labour;  
Subdural haematoma

### Abstract

*Background and objectives:* Only few reports in literature have pointed out to the possibility of a cranial subdural haematoma formation associated with dural puncture during spinal or epidural analgesia. We herein describe such a rare case who was diagnosed to have acute subdural haematoma after combined spinal–epidural anaesthesia used in labour.

*Case report:* A 34-year-old, primigravid women with a gestation of 38 weeks underwent caesarean section under combined spinal–epidural anaesthesia and gave birth to a healthy boy. Thirty-two hours after delivery, her moderate headache progressed to a severe headache associated with nausea and vomiting and later was more complicated with a generalized tonic–clonic seizure and ensuing lethargy. Computed tomography of the brain demonstrated a right-sided fronto-temporo-parietal acute subdural haematoma with diffuse cerebral oedema. She underwent urgent FTP craniotomy and evacuation of the haematoma. Early postoperative cranial computed tomography showed a clean operative site. Eight days after subdural haematoma surgery, she became lethargic again, and this time cranial computed tomography disclosed an extradural haematoma under the bone flap for which she had to undergo surgery again. Two days later, she was discharged home with Karnofsky performance score of 90/100. At follow-up exam, she was neurologically intact and her cranial computed tomography and magnetic resonance were normal.

*Conclusions:* As conclusion, with the use of this combined spinal–epidural anaesthesia, it should be kept in mind that headache does not always mean low pressure headache associated with spinal anaesthesia and that a catastrophic complication of subdural haematoma may also occur. © 2013 Sociedade Brasileira de Anestesiologia. Published by Elsevier Editora Ltda. All rights reserved.

\* Corresponding author.

E-mail: [bulentbanrs@yahoo.com](mailto:bulentbanrs@yahoo.com) (B. Bakar).

**PALAVRAS-CHAVE**

Anestesia combinada  
raqui-peridural;  
Parto;  
Hematoma subdural

## Hematoma subdural agudo potencialmente fatal após anestesia combinada raqui-peridural em parto

**Resumo**

*Justificativa e objetivos:* Apenas alguns relatos na literatura mencionaram a possibilidade de formação de hematoma subdural craniano associada à punção durante a raquianestesia ou anestesia epidural. O presente relato descreve um caso tão raro que foi diagnosticado como hematoma subdural agudo após anestesia combinada raqui-peridural usada em parto.

*Relato de caso:* Paciente primípara, 34 anos, com 38 semanas de gestação, submetida à cesariana sob anestesia combinada raqui-peridural, deu à luz um menino saudável. Após 32 horas do parto, a dor de cabeça moderada da paciente progrediu para dor de cabeça intensa associada a náusea e vômito e se complicou subsequentemente com crise convulsiva generalizada tônico-clônica e consequente letargia. Tomografia computadorizada do cérebro revelou hematoma subdural agudo do lado direito em região frontotemporoparietal (FTP) com edema cerebral difuso. A paciente foi submetida à craniotomia FTP de urgência e evacuação do hematoma. Tomografia computadorizada do crânio no pós-operatório precoce mostrou um sítio operatório limpo. Oito dias após a cirurgia do hematoma subdural, a paciente voltou a ficar letárgica e, dessa vez, a tomografia computadorizada revelou um hematoma extradural sob o retalho ósseo que exigiu outra cirurgia. Dois dias depois, a paciente recebeu alta hospitalar com classificação de desempenho Karnofsky de 90/100. Ao exame de acompanhamento, a paciente apresentou-se neurologicamente intacta e sua tomografia computadorizada e ressonância magnética estavam normais.

*Conclusão:* Ao usar a anestesia combinada raqui-peridural deve-se ter em mente que dor de cabeça nem sempre significa dor de cabeça hipotensiva associada à raquianestesia e que uma complicação catastrófica de hematoma subdural também pode ocorrer.

© 2013 Sociedade Brasileira de Anestesiologia. Publicado por Elsevier Editora Ltda. Todos os direitos reservados.

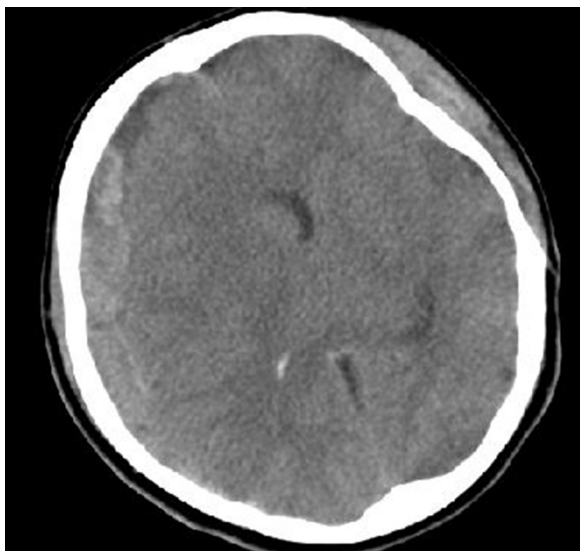
**Introduction**

Today, many anaesthesiologists prefer combined spinal-epidural (CSE) anaesthesia to avoid from the pain of labour. However, this technique bears some unique risks such as itching, nausea, vomiting, maternal hypotension, headache, convulsion, meningitis, toxicity, and even cardiac arrest. Additionally, few but recent reports have pointed out to the possibility of cranial subdural haematoma associated with dural puncture during the spinal and/or epidural anaesthesia in labour.<sup>1-3</sup> Our case study also described a rare case who underwent urgent surgery for acute subdural haematoma occurring 32 h after CSE anaesthesia used in labour.

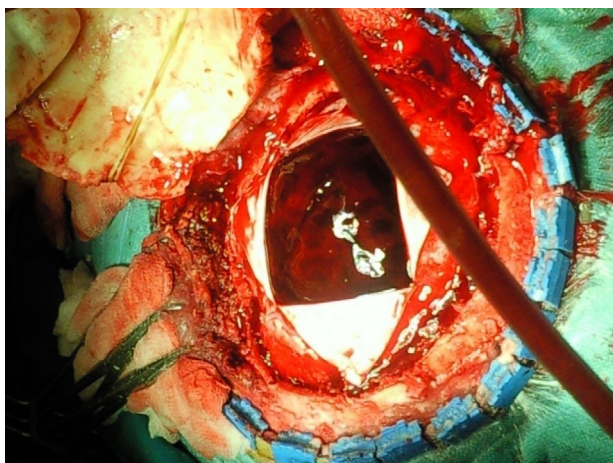
**Case history**

A 34-year-old, primigravid woman with a gestation of 38 weeks underwent caesarean section for cephalopelvic disproportion and foetal distress. Preoperative laboratory investigation was normal except relative thrombocytopenia (90,000/mm<sup>3</sup>) at total blood count. Surgery took place under the CSE anaesthesia, and she gave birth to a healthy boy. To perform the CSE anaesthesia, 18 G Tuohy and 27 G spinal needle were insert through the L4-5 interspinous space and then 10 mg bupivacaine and 25 µg fentanil was infused intrathecally. Early postoperative period was uneventful except for minimal vaginal staining. Next day, thirty-two hours after her surgery, she experienced a progressive headache around the neck. When she attempted to mobilize out of bed, she

vomited and suffered a generalized tonic-clonic seizure and fell back on her bed. After the seizure, she became lethargic with no eye or verbal response to painful stimuli (Glasgow Coma Score (GCS) E1M5V1-Total 7/15) and the right pupil was found to be dilated while her breathing was ataxic; and her cardiac rhythm is bradycardic (45 min<sup>-1</sup>). There was no history of a previous trauma or a drop attack. An emergent brain computed tomography (CT) demonstrated a right-sided fronto-temporo-parietal (FTP) acute subdural haematoma with diffuse oedema of the surrounding brain (Fig. 1). She underwent urgent FTP craniotomy; and acute haematoma was evacuated (Fig. 2). Postoperatively, the patient was sedated and mechanically ventilated for 48 h at intensive care unit (ICU). At ICU, because the postoperative control blood count result showed severe thrombocytopenia (50,000/mm<sup>3</sup>), repeated doses of the standard platelet were transfused to the patient to ameliorate her thrombocytopenia. After extubation, early GCS was 10/15 (E3M5V2). Cranial CT scan documented a clean operative site; and blood count results, blood chemistry parameters and coagulation cascade factors (i.e. active thromboplastin time and prothrombin time) of the patient were found in normal ranges postoperatively. Five days after surgery she reached a GCS of full 15 and was taken to ward. Eight days after subdural haematoma surgery, she became lethargic again with a GCS of 14/15 (E3M6V5) and cranial CT disclosed an extradural haematoma under the bone flap for which she had to undergo surgery again. Two days later, she was discharged home with Karnofsky performance score of 90/100. A follow-up exam 5 months after discharge revealed a



**Figure 1** Preoperative brain computed tomography scan demonstrates the right fronto-temporo-parietal acute subdural haematoma with diffuse cerebral oedema.



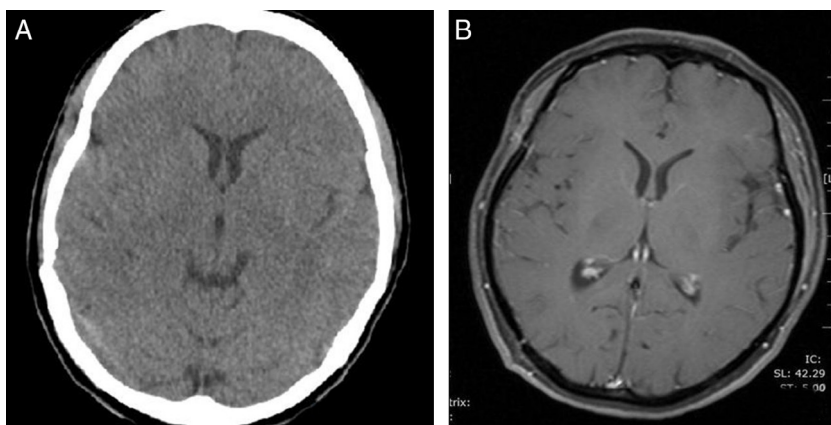
**Figure 2** Photograph taken intraoperatively shows the acute subdural haematoma.

fully capable, functional and neurologically intact patient (Karnofsky performance score 100/100). Cranial CT and magnetic resonance (MR) scans were normal (Fig. 3).

## Discussion

The safety of the spinal and epidural anaesthesia as separate techniques has been well documented. Nevertheless, there are reports that have pointed to the fact that CSE anaesthesia during labour may cause hypotension as its immediate complication. This hypotension that is probably caused by undesired effects of either intrathecal opioids or epidural local anaesthetics may have triggered a secondary intracranial hypotension.<sup>4,5</sup> On top of this, as with spinal and/or epidural anaesthesia, an intended or an inadvertent dural puncture may well provoke leakage of the cerebrospinal fluid (CSF) into the epidural space. This leakage also causes intracranial hypotension.<sup>6</sup> This leakage hence causes caudal displacement of the cerebral and stretches the bridging cerebral vessels (especially the cerebral veins and venules). The walls of these bridging veins are very thin when they course through the subdural space although they have thicker walls while in the subarachnoid space. So, it is possible that either hypotension or the gravitational forces that have separated the cortex from the overlying dura could have caused an initial tear which could have been repaired with a normal coagulation system.<sup>3</sup> On the other hand, cerebral subdural haematomas may also occur spontaneously in parturient women without dural puncture as a consequence of a rapid intracranial pressure drop after the Valsalva manoeuvre.<sup>6,7</sup>

Acute subdural haematomas have been described as lesions causing signs or symptoms within less than 7 days after the initiation of bleeding.<sup>1</sup> Cerebral atrophy, dehydration, excessive CSF leakage originating from dural puncture(s), anticoagulants, and arteriovenous malformations (AVM) are thought to be the contributing factors for subdural haematoma formation. On the other hand, it can be argued that only the largest spinal needle may cause a significant CSF leakage, but Zeidan et al. has reported that mortality was not related to the size of the spinal needle used in CSE and epidural spinal anaesthesia.<sup>8</sup> Our



**Figure 3** (A) Computed tomography scan and (B) magnetic resonance scan with gadolinium obtained after surgery shows no residual haematoma or other pathological conditions (such as arteriovenous malformation, contusion, aneurysm or tumoural mass).

patient did not use anticoagulant; and her postoperative cranial MR with gadolinium revealed no cerebral AVM and/or aneurysm. Furthermore, the anaesthesiologist who performed the CSE anaesthesia to our patient reported no excessive CSF leakage or unexpected event during the procedures. Additionally, we could not explain the aetiology of the thrombocytopenia in our patient.

In most cases, a nonpostural headache, changes in headache characteristics (such as resistant headache, retroorbital or frontal headache), vomiting, seizure, and lethargy are alerting signs. In those patients including these symptoms, aetiology should be well differentiated; and postdural puncture headache, pre-eclamptic and eclamptic headache, simple tension or migraine headache, subdural/subarachnoid haemorrhage, stroke, tumour, meningitis, and cerebral vein thrombosis should be all excluded.<sup>1,5</sup> In our patient, headache occurred rapidly within two days after delivery, and it was rapidly complicated with seizure. Differential diagnosis of the seizure in present case includes eclampsia, intracranial haemorrhage, embolic episodes and local anaesthetic toxicity.<sup>1</sup> Eclampsia was excluded, because no other symptoms except seizure were present in our patient. Toxicity could be excluded as the seizure occurred on the second day. The history was not suggestive of the cortical vein thrombosis; and meningitis was excluded by absent of neutrophilia, neck stiffness and fever. Additionally, rapid development of the serious neurological symptoms, and the emergent cranial CT scan performed by alerted medical staffs confirmed the clinical diagnosis.

Treatment of the subdural haematoma includes conservative (medical observation, anti-oedema medication), or surgical (intracranial pressure monitoring, external ventricular CSF drainage, single or multiple burr-hole drainage, and craniotomy/craniectomy) techniques. Haematomas less than 10 mm in width often resolve spontaneously. However, thicker haematomas complicated with reactive cerebral oedema often cause serious neurological symptoms and require surgical evacuation. Preoperative neurological condition correlates with the postoperative outcome.<sup>1,5</sup> In our patient, we could not clarify the exact cause of the subdural haematoma. Surely some CSF leakage occurred and most probably caused a relative intracranial hypotension leading to stretching of the bridging veins. Yet there was no

Valsalva manoeuvre like in a normal labour that would have contributed to the increasing volume of the haematoma. Whatever the reason, her subdural haematoma was thick and dense enough to be considered for surgery.

## Conclusion

This case demonstrates an acute subdural haematoma after CSE anaesthesia in a patient without risk factors for bleeding. As conclusion, with the use of this CSE anaesthesia, this rare but catastrophic complication of subdural haematoma should be always kept in mind.

## Conflicts of interest

The authors declare no conflicts of interest.

## References

1. Vaughan DJ, Stirrup CA, Robinson PN. Cranial subdural haematoma associated with dural puncture in labour. *Br J Anaesth.* 2000;84:518–20.
2. Kayacan N, Arici G, Karsli B, et al. Acute subdural haematoma after accidental dural puncture during epidural anaesthesia. *Int J Obstet Anesth.* 2004;13:47–9.
3. Bisinotto FM, Dezena RA, Fabri DC, et al. Intracranial subdural hematoma: a rare complication following spinal anesthesia: case report. *Rev Bras Anesthesiol.* 2012;62:88–95.
4. Norris MC, Grieco WM, Borkowski M, et al. Complications of labor analgesia: epidural versus combined spinal–epidural techniques. *Anesth Analg.* 1994;79:529–37.
5. Abbinante C, Lauter E, Di Venosa N, et al. Acute subdural intracranial hematoma after combined spinal–epidural analgesia in labor. *Minerva Anesthesiol.* 2010;76:1091–4.
6. Sharma S, Halliwell R, Dexter M, et al. Acute subdural haematoma in the presence of an intrathecal catheter placed for the prevention of post-dural puncture headache. *Anaesth Intensive Care.* 2010;38:939–41.
7. Ramos-Aparici R, Segura-Pastor D, Edo-Cebollada L, et al. Acute subdural hematoma after spinal anesthesia in an obstetric patient. *J Clin Anesth.* 2008;20:376–8.
8. Zeidan A, Farhat O, Maaliki H, et al. Does postdural puncture headache left untreated lead to subdural hematoma? Case report and review of the literature. *Middle East J Anesthesiol.* 2010;20:483–92.