

Research Article

Mehmet Gökhan Demir, Sedat Aydın*, Banu Atalay Erdoğan,
Serpil Oğuztüzün, Murat Kılıç and Nagehan Özdemir Barışık



Expression of antimicrobial peptides in recurrent adenotonsillitis

Rekürren adenotonsillitte antimikrobiyel peptidlerin ekspresyonu

DOI 10.1515/tjb-2016-0145

Received May 25, 2015; accepted April 18, 2016; previously published online October 20, 2016

Abstract

Background: Recurrent acute tonsillitis is one of the most frequent otorhinolaryngology clinic referrals, yet its pathogenesis remains poorly understood. Antimicrobial cationic peptides are components of the innate system. They are generally small, highly positively charged peptides with broad spectrum antimicrobial activity which function as the body's "natural antibiotics". Our aim is to investigate the role of antimicrobial cationic peptides in the susceptibility of patients to recurrent acute tonsillitis. **Materials and methods:** The study is done with 100 children who had a history of recurrent adenotonsillitis as subject group and 100 children with adenotonsillar hypertrophy as control group. Tonsillar and adenoid tissues are dissected into parts as deep and surface epithelium and investigated semiquantitatively with immunohistochemistry. Human beta defensin (hBD) 1–3 and cathelicidin (LL-37) levels are compared with microscopically.

Results: Immunohistochemistry revealed a strong expression of hBD-1, hBD-2 and hBD-3 in tonsillar tissue.

Quantification of hBD-1, hBD-2 and hBD-3 expressions are shown more in tonsillar tissue than in adenoids. LL-37 is one of the antimicrobial peptides found in human tonsillar tissue and adenoids, that participates in the innate immune system of these tissues. Statistically, hBD-1, hBD-3 and LL-37 expressions were different in recurrent tonsillitis tissue than control ($p < 0.05$). Moreover hBD-2 expression was different in adenoid tissue than control ($p < 0.05$).

Conclusion: Antimicrobial peptides have key role in adenotonsillar infections and this defense mechanism increases susceptibility to recurrent infections in upper respiratory tract.

Keywords: Antimicrobial peptides; Adenotonsillitis; Adenotonsillar hypertrophy; Immunohistochemistry; Immune system.

Özet

Giriş: Rekürren akut tonsillitis, kulak burun boğaz kliniğinde sıklıkla görülmektedir fakat patogenezi çok az bilinmektedir. Antimikrobiyel katyonik peptidler doğuştan olan bağışıklık sisteminin parçasıdır. Bu peptidler genel olarak küçük, pozitif yüklü peptidlerdir. Ayrıca vücudumuzun doğal antibiyotiği olarak görev yapan geniş spektrumlu antimikrobiyel aktivite göstermektedirler. Amacımız hastaların tekrarlanan akut tonsillitise duyarlılıklarında antimikrobiyel katyonik peptidlerin rolünü incelemektir.

Metod: çalışma grubunu rekürren adenotonsillit öyküsü olan 100 hasta, kontrol grubunu ise adenotonsiller hipertrofi olan 100 çocuk oluşturmaktadır. tonsil ve adenoid doku yüzeysel ve derin dokulara ayrılacak şekilde diseke edilmiştir ve semikantitatif olarak immunohistokimyasal olarak incelenmiştir. human beta defensin (hBD) 1–3 ve katlesidin (LL-37) seviyeleri mikroskopik olarak karşılaştırılmıştır.

*Corresponding author: Sedat Aydın, Kartal Dr. Lutfi Kirdar Education and Research Hospital, Department of Otolaryngology, İstanbul, Turkey, e-mail: sedataydin63@yahoo.com

Mehmet Gökhan Demir: Prof. Dr. Celal Ertuğ Etimesgut State Hospital, Department of Otolaryngology, Ankara, Turkey

Banu Atalay Erdoğan: Kartal Dr. Lutfi Kirdar Education and Research Hospital, Department of Otolaryngology, İstanbul, Turkey

Serpil Oğuztüzün: Kırıkkale University, Department of Biology, Kırıkkale, Turkey

Murat Kılıç: Ankara University, Vocational School of Health Services, Ankara, Turkey

Nagehan Özdemir Barışık: Kartal Dr. Lutfi Kirdar Education and Research Hospital, Department of Pathology, İstanbul, Turkey

Bulgular: İmmunohistokimyasal değerlendirmede tonsil dokusunda yüksek HbD1, HbD2 ve Hbd3 ekspresyonu mevcuttur. tonsil dokusunda adenoid dokusuna göre daha fazla HbD1, HbD2 ve Hbd3 seviyesi mevcuttur. LL-37 insan tonsil ve adenoid dokusunda yeralan ve doğumsal immun sistemin bir parçası antimikrobiyal peptiddir. hBD1, hBD2 ve LL-37 seviyeleri rekürren tonsillit ve kontrol grubunda istatistiki olarak farklıdır ($p < 0.05$). Ayrıca hBd2 ekspresyonu adenoid dokuda kontrol grubuna göre farklıdır ($p < 0.05$).

Sonuç: Antimikrobiyel peptidler adenotonsiller enfeksiyonlarda anahtar role sahiptir ve bu defans mekanizması üst solunum yolunda rekürren enfeksiyonlarda hassasiyeti artırır.

Anahtar Kelimeler: Antimikrobiyel peptidler; Adenotonsillit; Adenotonsiller hipertrofi; İmmunohistokimya; İmmun sistem.

Introduction

The Waldeyer ring of lymphoid tissue at the nasopharyngeal and oropharyngeal openings constitutes the first line of defense against ingested and inhaled pathogens. It is constituted by lingual tonsils, the palatine tonsils, and the nasopharyngeal tonsils (adenoids) [1, 2]. These tissues have antimicrobial peptides which help defense mechanism against infections especially in childhood period. Recurrent upper respiratory tract infections such as tonsillitis and adenoiditis can be seen commonly. Despite frequent medical cases and high economical cost, exact reason of these recurrent infections are not known yet.

Antimicrobial peptides are unique, cationic and diverse group of molecules, which are divided into subgroups on the basis of their amino acid composition and structure [3, 4]. According to their structures, these peptides are classified as human beta defensins (hBD), cathelicidins and histatins [5].

Human beta defensins are endogenous antibiotics against gram negative and positive bacteria, fungi, viruses and protozoa [6]. There are three described form of hBD peptides. hBD-1 which was first isolated from hemofiltrate, found in epithelial cells of the urinary, respiratory tract and in keratinocytes and increased in inflammation potent effect against gram negative bacteria [7–10]. hBD-2 and hBD-3 which are isolated from psoriatic lesions, have a potential antimicrobial effect on *Escherichia coli*, *Pseudomonas aeruginosa*, *Candida albicans*, *Staphylococcus aureus*, Methicillin resistant *S. aureus* (MRSA),

Streptococcus pyogenes, Vancomycin-resistant *Enterococcus faecium*, and *Haemophilus influenza* [10–12].

Histatins which are histidine rich peptides, found in human saliva and have potent antifungal activity. They are also antimicrobial and antifungal proteins, and have been found to play a role in wound-closure. The three major histatins are 1, 3, and 5. Histatin 2 is a degradation product of histatin 1, and all other histatins are degradation products of histatin 3 [13].

Cathecidins were first isolated in myeloid cells of different species in 1990 then defined in epithelial cells [5]. Nowadays, they are also detected in gastrointestinal tract, skin, testicular tissue, natural killer cells, T cells, B cells and macrophages [5, 14]. Epithelial cells and circulating neutrophils in blood stream is the main source of the cathelicidins and primary expression area of these peptides is bone marrow [5]. Concentration of cathelicidin is increased in infection and inflammation [5].

LL-37, active form of the cathelicidin, has a potent and broad spectrum effect on germs [15].

In this study, we investigate the role of antimicrobial peptides in recurrent adenotonsillitis and normal adenoid and tonsil tissue in childhood period.

Materials and methods

This study was approved by Hospital Ethical Comitee and all participants and their family were informed about study and the participant's family gave written consent to this study. The study is conducted between 2010–2013 in our hospital. The study is done with 100 children who had a history of recurrent adenotonsillitis as subject group. Control group is composed of 100 children with adenotonsillar hypertrophy without any recurrent infection history.

All the participants was operated under general anesthesia. Tonsil tissues are dissected after operation as surface epithelium and deep tonsillar tissue for further investigation.

Surface epithelium and adenoid tissues were fixed in 10% buffered formalin and embedded in paraffin blocks. Sections were cut 4 μ m thick, and one section was stained with hematoxylin and eosin to observe the tissue morphology. For immunohistochemistry, endogenous peroxidase activity was blocked by incubating the sections in 1% hydrogen peroxide (v/v) in methanol for 10 min at room temperature (RT). The sections were subsequently washed in distilled water for 5 min, and antigen retrieval was performed for 3 min using 0.01 M citrate buffer (pH 6.0) in a domestic pressure cooker.

The sections were transferred in 0.05 M Tris-HCl (pH 7.6) containing 0.15 M sodium chloride (TBS). After washing in water, the sections were incubated at RT for 10 min with super block (SHP125) (ScyTek Laboratories, USA) to block nonspecific background staining. The sections were then covered with the primary antibodies diluted 1:100 for anti-hBD-1, 1:50 for anti-hBD-2, 1:100 for anti-hBD-3, 1:200 for anti-LL-37 in TBS at 4°C overnight. Anti-hBD-1 (cat. no: bs-2165R) was from Bioss Inc., Woburn, MA, USA, Anti-hBD-2 (cat. no: 251659) was from Abbiotec San Diego, USA, Anti-hBD-3 (cat. no: H-072-42) was from Phoenix Pharmaceuticals, Inc., USA, and anti-hCAP-18/LL-37 (cat. no: sc-166770) was from Santa Cruz Biotechnology, Inc. After washing in TBS for 15 min, the sections were incubated at RT for biotinylated link antibody (SHP125) (ScyTek Laboratories, USA). Then, treatment was followed with Streptavidin/HRP complex (SHP125) (ScyTek Laboratories, USA). Diaminobenzidine was used to visualize peroxidase activity in the tissues. Nuclei were lightly counterstained with haematoxyline, and then the sections were dehydrated and mounted. Both positive and negative controls were included in each run. Positive controls consisted of sections of tonsillitis tissues for hBD-3 and hCAP-18/LL-37, lung tissues for hBD-1 and hBD-2. TBS was used in place of the primary antibody for negative controls.

Light microscopy of immunohistochemically stained sections was performed by a pathologist and a biologist, who had no knowledge of the patients' clinical information. Distribution, localization and characteristics of immunostaining were recorded. Brown color in cytoplasm and/or nuclei of epithelial cells were evaluated as positive staining. Scoring was also performed by observers unaware of the patient data. Scoring differences between observers were resolved by consensus. For each antibody, the intensity of the reaction – negative (–), weak (1+), moderate (2+) or strong (3+) – was determined in order to describe the immunoreactions.

SPSS 15.0 computer program is used for assessment. The relation between IHC staining and clinical parameters is investigated with independent sample t-tests. The results were found to be significant for $p < 0.05$.

Results

Totally 200 participants are included in this study and grouped as recurrent adenotonsillitis group ($n=100$) and adenotonsillar hypertrophy ($n=100$) as control group. Descriptive features of these groups are shown in Table 1.

Table 1: Descriptive characteristics of the study population.

Variables	Adenotonsillitis group (n=100)	Control group (n=100)	p-Value
Age (mean \pm SD)	7.14 \pm 2.22	7.03 \pm 2.12	0.721
Gender (M : F)	44 : 56	49 : 51	0.478

Both recurrent tonsillitis and control groups are statistically similar according to age and gender distribution ($p > 0.05$).

According to immunohistochemical staining results, most of the tonsil surface epithelium and deep crypt epithelium have positive staining character with hBD-1, hBD-2, hBD-3 ve LL-37 antimicrobial peptides (Figures 1–5). Also most of the adenoid tissue has a positive expression for hBD-1, hBD-2, hBD-3 ve LL-37 peptides (Figures 6 and 7).

hBD-3, LL-37 and hBD-1 results of the recurrent tonsillitis group are statistically different from control group ($p < 0.05$). But hBD-2 peptide is not different between control and recurrent tonsillitis group ($p > 0.05$) (Table 2).

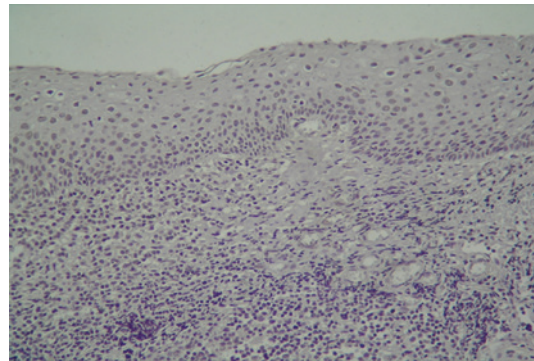


Figure 1: Tonsil surface epithelium without LL-37 staining (tonsil, 200 \times).

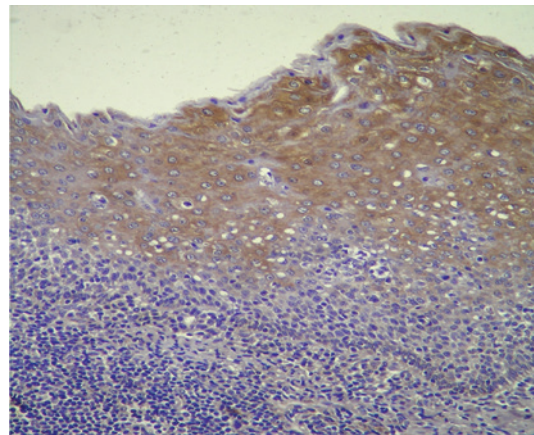


Figure 2: Tonsil surface epithelium staining with HBD-1 severely (tonsil, 200 \times).

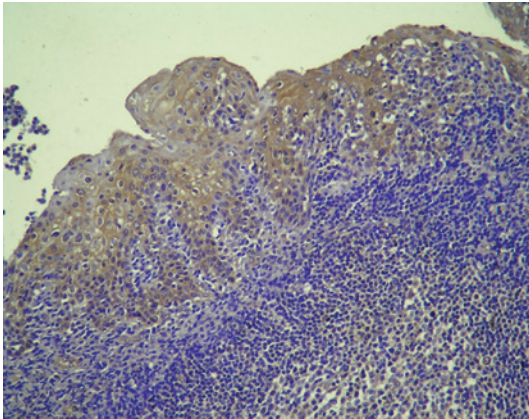


Figure 3: Tonsil cript etihelium staining severely with HDB-3 (tonsil, 200×).

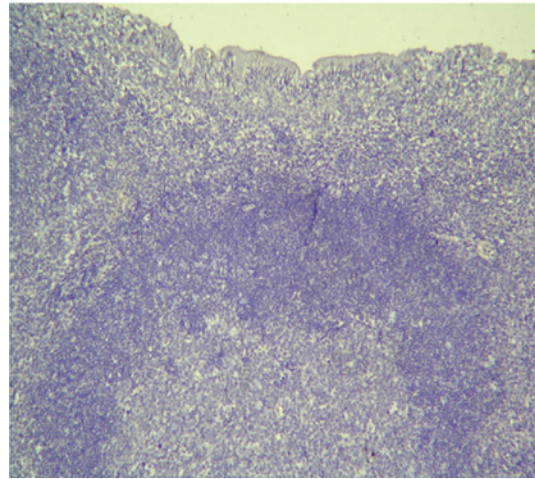


Figure 6: Adenoid tissue without hBD-1 staining (adenoid, 100×).

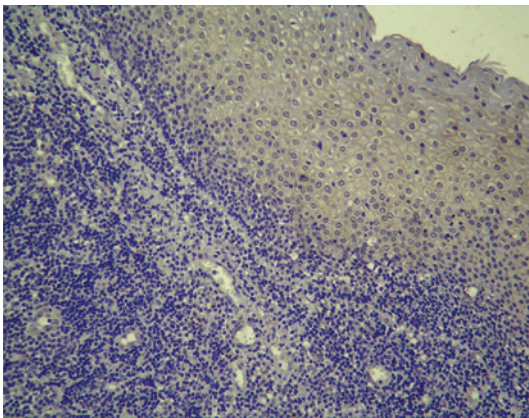


Figure 4: Tonsillar surface epithelium staining weakly with HBD-2 (tonsil, 200×).

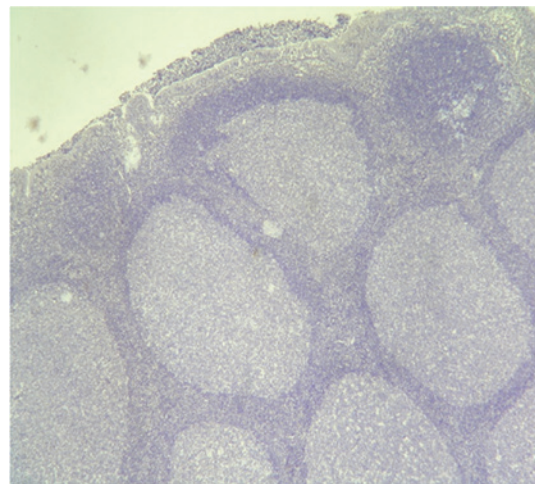


Figure 7: The hBD-2 negative staining in adenoid tissue (adenoid, 40×).

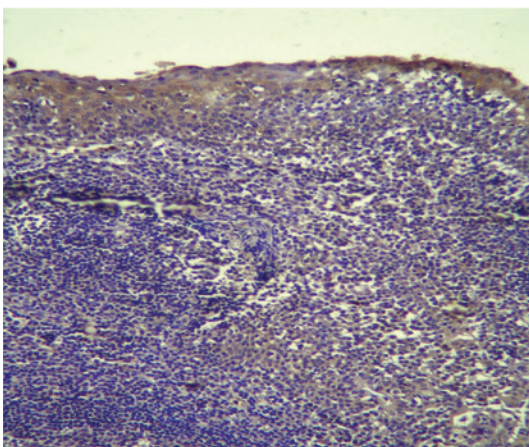


Figure 5: Tonsillar surface epithelium moderately staining with LL-37 (tonsil, 200×).

hDB-2 peptide in recurrent adenoiditis group is statistically different from control group ($p < 0.05$). LL-37 and hBD-3 is not different between recurrent adenoiditis and control group ($p > 0.05$) (Table 3).

Discussion

Waldeyer ring and its components, tonsillar and adenoid tissue, are settled on the upper respiratory opening. Also this strategically important region is the meeting point of various microorganism, food and antigenic materials of

Table 2: Distrubution of the hBD-1, hBD-2, hBD-3 ve LL-37 antimicrobial peptides in control and recurrent tonsillitis groups.

Antimicrobial peptides	Recurrent tonsillitis group mean (SD)	Control group mean (SD)	p-Value
hBD-1	1.93 (0.31)	0.63 (0.22)	0.000^a
hBD-2	1.45 (0.27)	0.94 (0.26)	0.062
hBD-3	0.96 (0.26)	0.42 (0,15)	0.017^a
LL-37	0.75 (0.19)	0.26 (0.15)	0.001^a

^aThe mean difference is significant at the 0.05 level. SD, Standard deviation. hBD-1, LL-37 and hBD-3 results of the recurrent tonsillitis group are statistically different from control group ($p < 0.05$), but hBD-2 peptide is not different among groups ($p > 0.05$).

Table 3: Distrubution of the hBD-1, hBD-2, hBD-3 ve LL-37 antimicrobial peptides in control and recurrent adenoiditis groups.

Antimicrobial peptides	Recurrent adenoiditis group mean (SD)	Control group mean (SD)	p-Value
hBD-1	1.03 (0.31)	0.93 (0.22)	0.932
hBD-2	1.55 (0.27)	0.64 (0.18)	0.001^a
hBD-3	1.36 (0.34)	1.13 (0.29)	0.231
LL-37	1.15 (0.32)	0.96 (0.25)	0.585

^aThe mean difference is significant at the 0.05 level. SD, Standard deviation. Recurrent adenoiditis group is statistically different hBD-2 peptide levels than control group ($p < 0.05$) but LL-37, hBD-1 and hBD-3 levels are statistically not different among groups ($p > 0.05$).

the inhaled air. Because of this critical function, human palatine tonsils has a key role in innate, cellular and humoral immunity at local and systemic levels. This immunity is not settled in newborn period and is learned in childhood. This defense mechanism in early childhood is formed and matured.

Palatine tonsils which are lymphoid organs, surrounded with nonkeratinized stratified squamous epithelium. When we discussed the innate immunity the surface epithelium is both physical barrier for infections and antibiotic function with the help of synthesized surface peptides.

All these antimicrobial peptides are also known as cationic peptides. These peptides have functions against viruses, fungi and bacterias. Due to its cationic property the negative charge of the microbes are linked with this peptides then resulted with denaturation or death of the microbes. Besides of this function, the chemotactic role and wound healing function are also defined [16].

In childhood period, viral infections are the most common cause of acute adenotonsillitis/pharyngitis; adenovirus is the most common cause of

nonstreptococcal adenotonsillitis. Group A beta hemolytic streptococcus is the most common bacterial cause of acute pharyngitis; its peak incidence occurs in children 5–6 years of age during the winter and spring. This organism is survived in oropharyngeal flora and its coloni formation is protected with this flora [17]. Recurrent episodes of adenotonsillar infection is embarrassing due to obstacle for school admittance. Likewise, in otorhinolaryngology practice adenotonsillectomy surgery is one of the most common surgical modality for this purpose [18]. In acute tonsillitis situation, the level of antimicrobial peptides such as lysosyme and lactoferrin are increased [19]. But the level of antimicrobial peptide is not known in recurrent adenotonsillar infection during childhood period. For this purpose we investigate 100 children with adenotonsillar infections and 100 children with adenotonsillar hypertrophy. Adenoid and tonsil tissues are harvested and prepared for immunohistochemical and pathological investigation. According to our findings, we found that patients with recurrent tonsillitis have increased concentration of antimicrobial peptides such as hBD-1, hBD-3 and LL-37 peptides than control groups. This difference is statistically significant. But this relation is not detected on hBD-2 peptide levels. Also, previous studies which support our data, showed the increased level of hBD1-3 levels in acute episode of tonsillitis [20]. Besides these results, another study showed that neither hBD2 nor hBD3 levels were increased in infectious process in tonsillitis [21]. Our results support partially studies of both Ball and Claeys with increased level in hBD1 and hBD3 levels [20, 21]. But hBD2 levels are not changed in infectious stage. Additionally recurrent adenoiditis group has a high hBD-2 levels than adenoid hypertrophy group. The levels of hBD2 and hBD3 in recurrent adenoiditis are not different from adenoid hypertrophy group.

LL-37 peptide is increased in adenotonsillar infections but Song et al. reported reduced levels of LL-37 in control subjects [22]. Our data show that tissues of the recurrent adenotonsillar infection have increased levels of LL-37 than control.

In conclusion, the antimicrobial peptides have critical role in recurrent adenotonsillitis. These peptides are increased in superficial epithelium and have a role in defense mechanism. The data also supports the local role of antimicrobial peptides in infectious conditions.

Conflict of interest statement: There is no conflict of interest in this paper and the authors have no financial disclosures.

References

1. Brandtzaeg P. Immune function of nasopharyngeal tissue. *Adv Otorhinolaryngol* 2011;72:20–4.
2. Brandtzaeg P. Immunology of tonsils and adenoids: everything the ENT surgeon needs to know. *Int J Pediatr Otorhinolaryngol* 2003;67:S69–76.
3. Yeaman MR, Yount NY. [Mechanisms of antimicrobial peptide action and resistance](#). *Pharmacological reviews* 2003;55:27–55.
4. Bals R. Epithelial antimicrobial peptides in host defense against infection. *Respir Res* 2000;1:141–50.
5. Bals R, Wilson JM. Cathelicidins—a family of multifunctional antimicrobial peptides. *Cell Mol Life Sci* 2003;60:711–20.
6. Zaslo VM. Antimicrobial peptides of multicellular organisms. *Nature* 2002;415:389–95.
7. McCray P Jr, Bentley L. [Human airway epithelia express a beta defensin](#). *Am J Respir Cell Mol Biol* 1997;16:343–9.
8. Valore EV, Park CH, Quayle AJ, Wiles KR, McCray PB Jr, Ganz T. Human beta defensin-1: an antimicrobial peptide of urogenital tissues. *J Clin Invest* 1998;101:1633–42.
9. Sørensen OE, Thapa DR, Rosenthal A, Liu L, Roberts AA, Ganz T. Differential regulation of defensin expression in human skin by microbial stimuli. *J Immunol* 2005;174:4870–9.
10. Schröder J-M, Harder J. Human beta-defensin-2. *Int J Biochem Cell Biol* 1999;31:645–51.
11. Harder J, Bartels J, Christophers E, Schröder JM. Isolation and characterization of human beta defensin-3, a novel human inducible peptide antibiotic. *J Biol Chem* Vol 2001;276:5707–13.
12. Ishimoto H, Mukae H, Date Y, Shimbara T, Mondal MS, Ashitani J, et al. Identification of hBD-3 in respiratory tract and serum: the increase in pneumonia. *Eur Respir J* 2006;27:253–60.
13. VanderSpek JC, Offner GD, Troxler RF, Oppenheim FG. Molecular cloning of human submandibular histatins. *Arch Oral Biol* 1990;35:137–43.
14. Steinstraesser L, Oezdogan Y, Wang SC, Steinau HU. [Host defense peptides in burns](#). *Burns* 2004;30:619–27.
15. Gennaro R, Zanetti M. Structural features and biological activities of the cathelicidin-derived antimicrobial peptides. *Biopolymers* 2000;55:31–49.
16. Hancock RE, Diamond G. [The role of cationic antimicrobial peptides in innate host defences](#). *Trends Microbiol* 2000;8:402–10.
17. Brook I. [The role of beta-lactamase producing bacteria and bacterial interference in streptococcal tonsillitis](#). *Int J Antimicrob Agents* 2001;17:439–42.
18. Baugh RF, Archer SM, Mitchell RB. Clinical practice guidelines: tonsillectomy in children. *Otolaryngol Head Neck Surg* 2010;144:1–30.
19. Stenfors LE, Bye HM, Raisanen S. Noticeable differences in bacterial defence on tonsillar surfaces between bacteria-induced and virus-induced acute tonsillitis. *Int J Pediatr Otorhinolaryngol* 2003;67:1075–82.
20. Ball SL, Siou GP, Wilson JA, Howard A, Hirst BH, Hall J. [Expression and immunolocalisation of antimicrobial peptides within human palatine tonsils](#). *J Laryngol Otol* 2007;121:973–8.
21. Claeys S, de Belder T, Holtappels G, Gevaert P, Verhasselt B, van Cauwenbergh P, et al. Human beta-defensins and toll-like receptors in the upper airway. *Allergy* 2003;58:748–53.
22. Song JJ, Hwang KS, Woo JS, Chae SW, Cho JG, Kang HE, et al. Expression of cathelicidin in recurrent throat infection. *Int J Pediatr Otorhinolaryngol* 2006;70:487–92.