

A 49-year-old man presented to the hospital with many years history of back pain. He went to many hospitals during this period. None of the hospitals performed a radiologic examination. He used many non-steroidal anti-inflammatory drugs, but he did not heal. The neurologic examination was normal. A magnetic resonance imaging revealed L1 hemivertebra compression to the thecal sac and spinal cord (Fig. 1). After this diagnosis, the patient was operated and hemivertebra was excised. After one year follow up the patient did not have back pain.

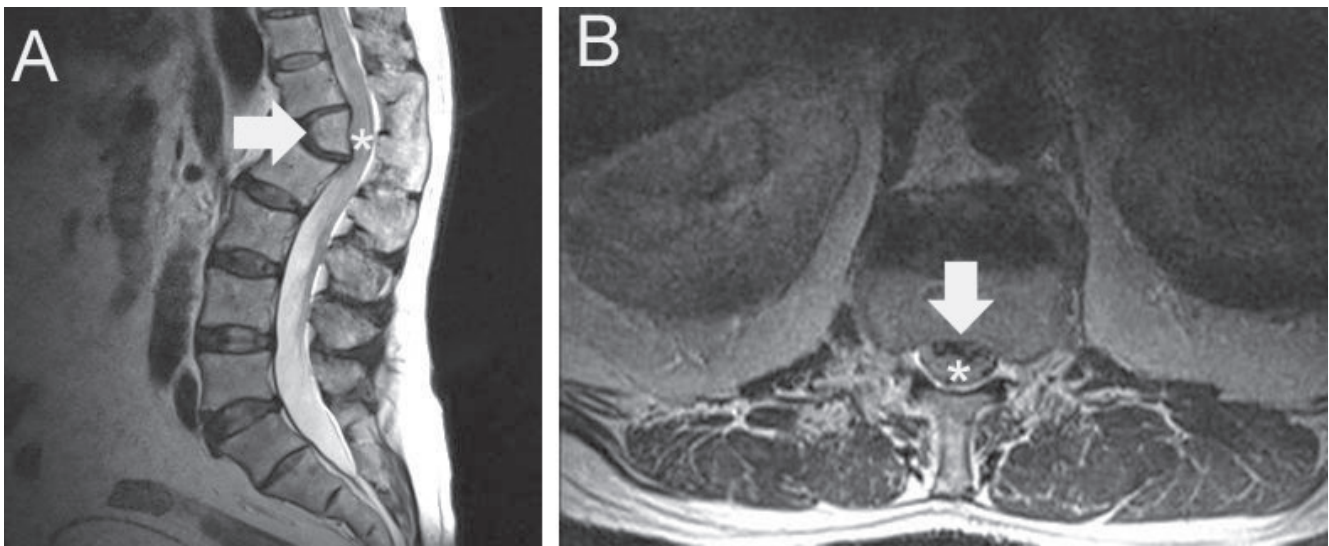


Figure 1. A T2 weighted sagittal (A) and axial (B) magnetic resonance images revealed L1 hemivertebra (arrow) compression to the thecal sac and spinal cord (asterisk).