

Effect of Titanium-prepared Platelet-rich Fibrin Treatment on the Angiogenic Biomarkers in Gingival Crevicular Fluid in Infrabony Defects of Patients with Chronic Periodontitis: A Randomized Controlled Clinical Trial

HG Pirebas, MK Hendek¹, U Kisa², M Yalim³, EO Erdemir¹

Private Dentist, Istanbul, ¹Department of Periodontology, Faculty of Dentistry, ²Department of Biochemistry, Faculty of Medicine, Kirikkale University, Kirikkale, ³Department of Periodontology, Faculty of Dentistry, Gazi University, Ankara, Turkey

ABSTRACT

Aim: The aim of this double-blinded, randomized, controlled clinical study was to investigate the effect of titanium-prepared platelet-rich fibrin (T-PRF) treatment on the angiogenic biomarkers in gingival crevicular fluid (GCF) in infrabony defects of patients with chronic periodontitis. **Materials and Methods:** Twenty five systemically healthy participants who complied with inclusion criteria with periodontal infrabony defects were recruited. In each patient, the infrabony defect of one side of arch was designated as control group (allograft), whereas the infrabony defect on the contralateral side of same arch was designated as test group (allograft + T-PRF). The therapy methods (test or control) were randomly decided. GCF samples were collected at baseline (presurgery) and then the 3rd, 7th, 14th, and 30th days after surgery. Platelet-derived growth factor (PDGF)-BB, vascular endothelial growth factor (VEGF)-A, fibroblast growth factor (FGF)-2, angiogenin (ANG), angiostatin (ANT) in the GCF samples were measured using human enzyme-linked immunosorbent assay kits. **Results:** In both groups, total amounts of PDGF-BB, VEGF-A, FGF-2, ANG, and ANT peaked in the GCF samples obtained at the early postoperative day (day 3) and decreased over time in the samples obtained at the 7th, 14th, and 30th days postsurgery. There were no significant differences between groups for the total amounts of PDGF-BB, VEGF-A, FGF-2, ANG, and ANT at all evaluation periods. **Conclusion:** Application of T-PRF combined with allograft in infrabony defects of patients with chronic periodontitis had no significant effects on angiogenic biomarkers in GCF.

KEYWORDS: *Clinical trial, gingival crevicular fluid, growth factors, osseous defects, periodontal surgery, periodontitis*

Date of Acceptance:
10-Oct-2016

INTRODUCTION

Angiogenesis is called that the formation of new capillaries from existing vessels by reproducing and migrating of endothelial cells. The response of endothelial cells to angiogenic signals comprises four stages. First, it requires the progress of endothelial cells along the basal lamina of main capillaries or veins and creating aperture in the basal lamina surrounding the existing blood vessels. Proteases are produced for degradation of basal membrane and extracellular matrix. The second stage is movement of endothelial

cells toward the source of signal. Subsequently, endothelial proliferation is occurred. The fourth and final stage is the formation of tubular structure. The proliferation stops and cells hold tightly to each other to form a lumen by changing the morphology. Mostly, angiogenesis is completed with synthesis of new basal

Address for correspondence: Dr. Meltem Karsiyaka Hendek, Faculty of Dentistry Department of Periodontology, Kirikkale University, Kirikkale, Turkey.
E-mail: mlmtkrsyk@yahoo.com

This is an open access article distributed under the terms of the Creative Commons Attribution-NonCommercial-ShareAlike 3.0 License, which allows others to remix, tweak, and build upon the work non-commercially, as long as the author is credited and the new creations are licensed under the identical terms.

For reprints contact: reprints@medknow.com

How to cite this article: Pirebas HG, Hendek MK, Kisa U, Yalim M, Erdemir EO. Effect of titanium-prepared platelet-rich fibrin treatment on the angiogenic biomarkers in gingival crevicular fluid in infrabony defects of patients with chronic periodontitis: A randomized controlled clinical trial. Niger J Clin Pract 2018;21:69-75.

Access this article online

Quick Response Code: 	Website: www.njcponline.com
	DOI: 10.4103/1119-3077.224795

membrane and attendance of pericytes and vascular smooth muscle cells to endothelium. Angiogenic growth factors such as platelet-derived growth factor (PDGF), vascular endothelial growth factor (VEGF), fibroblast growth factor (FGF), and epidermal growth factor (EGF) provide elicitation of these four phases of angiogenesis.^[1]

Application of the platelet concentrations in the medical field began in the 1990s and increased by expanding until today. Platelets are the cells initiating the wound healing and also supporting it by secreting various growth factors actively.^[2,3] These growth factors released by platelets act the increase of connective tissue healing, bone regeneration and repair, fibroblast mitogenesis, wound angiogenesis, and the activation of macrophages by stimulating cell proliferation signals.^[4] Many blood product-derived platelets by using different techniques have been developed.^[5] Choukroun *et al.*^[6] developed platelet-rich fibrin (PRF) as an autologous fibrin material that contains leucocytes and PRF. PRF may be considered as a second-generation platelet concentrate, using simplified protocol.^[5,7,8] PRF is an inherent fibrin-based biomaterial enabling the improvement of microvascularization directing epithelial cell migration. In previous studies, fibrin matrix has been directly led to angiogenesis. This property of the fibrin matrix may be explained three-dimensional structure and the activities of cytokines trapped in the matrix. It was shown that basic-FGF, VEGF, and PDGF that have been role in angiogenesis have high affinity to fibrin. On the other hand, fibrin acts as a supporting matrix for mesenchymal stem cells. Dohan *et al.*^[9] reported that growth factors such as PDGF-AB, VEGF, and transforming growth factor (TGF)- β are being slowly released from PRF during 7 days. The products inside natural fibrin material have high potential impact during the healing period. It was reported the key role of leucocytes in platelet concentrations was associated with infection preventive activity^[10] and immune regulatory feature.^[11,12] Dohan *et al.*^[11] studied platelets poor plasma (PPP), PRF and the amount of serum interleukin (IL)-1 β , IL-4, IL-6, tumor necrosis factor (TNF)- α and VEGF and they found all parameters, except VEGF, were high level in PRF and this was provided from leukocyte degranulation in PRF. It was suggested that the increment in cytokine levels was shown as defense capacity of PRF.

Despite of the useful effects of PRF in diverse procedures,^[13-15] some clinicians attach importance to a potential risk when glass tubes with silica activators were used. The unavoidable contact with silica was shown by O'Connell.^[16] The particles of silica in the tube may maintain suspended colloiddally in the layers

of PRF. Therefore, as PRF is used, the silica particles could attain the patient. Titanium-prepared, platelet-rich fibrin (T-PRF), is a new platelet concentrate, is formed in titanium tubes may be more efficient to activate platelets in comparison with glass tubes prepared in Choukroun's method.^[5-7,11] The titanium tubes is utilized to refrain any inverse effects of glass tubes and also silica. Activation of platelets in titanium tubes obtains the evident properties of T-PRF such as increased biocompatibility.

Until today, it has shown that PRF has been used in apexification,^[17] impacted third molar extractions,^[18,19] sinus lifting,^[20,21] infrabony periodontal defects,^[22,23] furcation^[14] and extraction defects,^[24,25] peri-implantitis treatment,^[26] and gingival recession.^[27-29] To the best of our knowledge, no study has reported the effect of autologous T-PRF in early wound healing on angiogenic biomarkers in the treatment of periodontal infrabony defects. Thus, the main aim of present study was to compare the effectiveness of composite graft consisting of an allograft and T-PRF to allograft alone on the angiogenic biomarkers in gingival crevicular fluid in infrabony defects of patients with chronic periodontitis. The hypothesis of this study was that T-PRF may affect the angiogenic biomarkers in gingival crevicular fluid.

MATERIALS AND METHODS

Twenty-five systemically healthy nonsmoker patients (16 females and 9 males; age range: 26–59 years; mean \pm SD: 40 \pm 8.37 years) with matched pairs of interproximal, intrabony defects participated in this double-blinded, randomized, controlled clinical trial that used a split-mouth design. The study was completed in the Department of Periodontology, Faculty of Dentistry at the University of Kirikkale from February 2014 to November 2014.

The study design was approved by the ethics committee of Kirikkale University and guided in accordance with the Declaration of Helsinki of 1975, as revised in 2000 and written informed consent from all participants was obtained. The study protocol (NCT02692079) was approved by the institutional review board.

The inclusion criteria were the presence of two- or three-wall intrabony defects ≥ 3 mm deep along with an interproximal probing depth ≥ 5 mm after nonsurgical periodontal therapy. Patients with systemic illnesses and taking any medications known to affect the outcomes of periodontal surgery, pregnancy, and lactation, who had plaque index >1 after the reevaluation of phase therapy, were excluded from the study. In addition, teeth with furcation defects, prosthesis, mobility \geq Grade II were also excluded.

Presurgical therapy

At 6-8 weeks after the initial periodontal therapy [scaling and root planning with curets (Hu-Friedy, Chicago, Illinois, USA) and polishing], a reevaluation was performed to approve the conformity of patients and sites to periodontal surgery.

T-PRF preparation

Ten milliliters of blood samples were collected from the each participant's arm by syringe and then was transferred to the titanium tube without anticoagulant. After centrifugation (Mikro 22 R Hettich Centrifugal Machine, Tuttlingen, Germany) of blood samples (2800 rpm, 12 minutes) at room temperature, the T-PRF clot was removed from the tubes with sterile tweezers. Red blood cells base was separated with scissors and the clots were placed on sterile woven gauze. Then, it was divided into small pieces with sterile scissors and mixed with allograft.

Surgical procedures

All surgical procedures were performed by the same operator (H.G.P.). Before surgery, 0.12% chlorhexidine solution and an iodine solution were used for intraoral and extraoral antiseptis. After topical and local anesthesia, buccal and lingual sulcular incisions were made and a full-thickness flap was reflected. The defects were debrided and root planed with ultrasonic instrumentation and area-specific curets. All sites were hed with sterile saline solution and bleeding control was performed. The selected sites were randomly (by coin-toss method) assigned to the test and control group by another author (M.K.H.). Test group sites were treated with T-PRF + allograft (CTBA, Magnesitstr, Austria), whereas control group was also treated with only allograft. Patients were blinded for allocation to particular group and treatment. The flaps were repositioned with 4-0 non absorbable silk suture (Ruschmed, 4-0 Silk Black, Istanbul, Turkey).

Postoperative care

After surgery, an antibiotic (Fako, Istanbul, Turkey) (100 mg doxycycline, two times per first day and one time per day for 13 days), an analgesic (Sanovel, Istanbul, Turkey) (100 mg flurbiprofen, two times per day, for 7 days) and chlorhexidine digluconate rinses (Drogsan, Istanbul, Turkey) (0.12%, twice daily for 14 days) were prescribed. The sutures were removed 10th day postoperatively. Gentle brushing with a soft toothbrush at 2nd week and appropriate interdental brush devices at 4th week were recommended. If necessary, reinforcement of oral hygiene and mechanical plaque control were reinstructed, postoperatively. No subgingival instrumentation was attempted at any of these appointments.

Collection and preparation of GCF samples

After the isolation of samples sites, the standardized strips (Periopaper; Ora Flow Inc., Amityville, New York, USA) were placed entrance of sulcus for 30 seconds and volume was measured on a precalibrated device (Periotron 8000; Oraflow Inc., Plainview, New York, USA). Three GCF (buccal, median, palatal/lingual) samples were collected from each defect. Phosphate-buffered saline (300 mL, pH 7.2) was added to each Eppendorf tube containing three paper strips. All samples were stored at -80°C until analysis. GCF samples were collected at baseline (immediately before surgery) and the 3rd, 7th, 14th, and 30th days after the surgery. Total amounts of PDGF-BB, VEGF-A, FGF-2, anjioengin (ANG), and angiostatin (ANT) were measured by enzyme-linked immunosorbent assay (Shanghai Yehua, Shangay, China) using commercial kits according to the manufacturers' instructions.

Statistical analyses

To achieve 90% power and detect differences among groups, 20 defects were essential for each group. To keep from potential dropouts, the sample size was enhanced to 25 defects per group. The normality of the data distribution was examined with the Shapiro–Wilk test. Non-normally distributed data were expressed as median (interquartile range). Friedman nonparametric repeated measurements analysis of variance test and Bonferroni correction were also used for differences between groups and to determine the groups leading to differences, respectively. Statistical analyses were evaluated with a software (SPSS Inc., Chicago, Illinois, USA). Statistical significance level was considered at $P < 0.05$.

RESULTS

Forty eight patients with chronic periodontitis were examined against the criteria listed for eligibility for the study. Seven patients refused to participate and 16 patients did not meet the inclusion criteria in the study. Finally, 25 patients received the intended treatment. All participants returned for evaluation at all study periods [Figure 1]. Wound healing was generally uneventful in all patients. The digestive system problems were observed due to antibiotic from only one patient. Depending on the use of local antimicrobial mouthwash coloration was observed in the tongues and teeth of the patients. Participants' age, gender, defect distribution, and number of osseous walls were shown in [Table 1].

GCF volume was similar at baseline in both groups. In the 3rd day after surgery, in both groups, it increased compared with baseline and then decreased to the end of the study period.

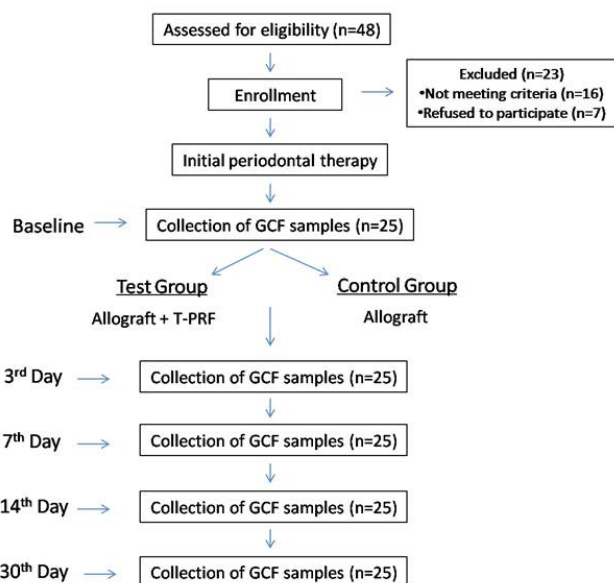


Figure 1: Flow chart of the study

Changes in angiogenic biomarkers in gingival crevicular fluid were reported in [Figure 2]. Prior to treatment, the total amount of PDGF-BB, VEGF-A, FGF-2, ANG, and ANT in GCF did not show statistically significant differences between the test and control groups. It was found that in both groups, total amounts of PDGF-BB,

Table 1: Participants' age, gender, defect distribution, number of osseous walls, and defect characteristics

	Test sites (n = 25)	Control sites (n = 25)
Age	40 ± 8.37 years	
Gender	16 females 9 males	
Two walls	9	7
Three walls	16	18
Premolars	12	14
Molars	13	11
Maxilla	13	15
Mandible	12	10

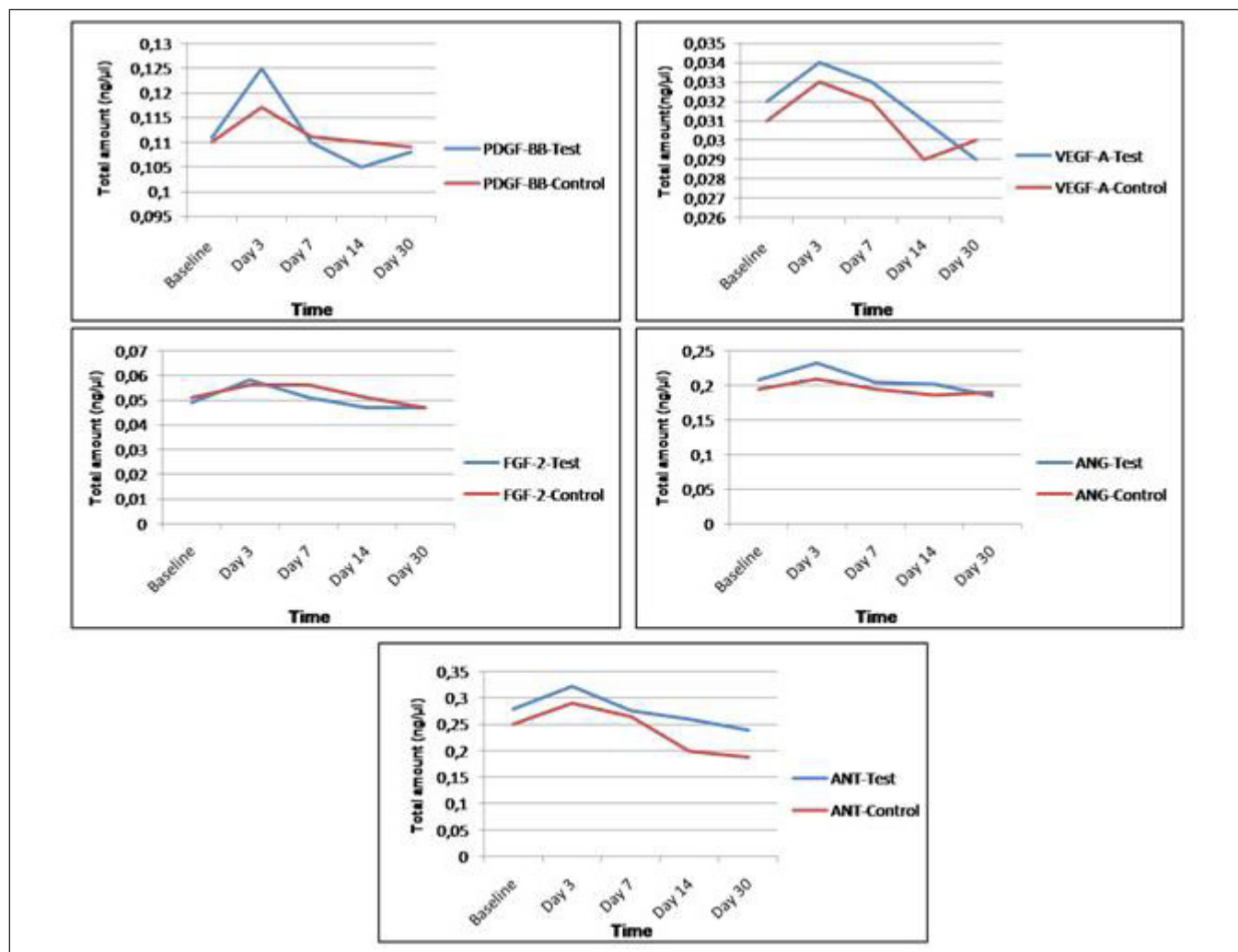


Figure 2: Comparison of total amounts of PDGF-BB, VEGF-A, FGF-2, ANG, ANT, in GCF between groups. ANG = anjigenin, ANT = angiostatin, FGF = fibroblast growth factor, GCF = gingival crevicular fluid, PDGF-BB = platelet-derived growth factor, VEGF = vascular endothelial growth factor

VEGF-A, FGF-2, ANG, and ANT peaked in the early postoperative day 3 and decreased over time in the 7th, 14th, and 30th days postsurgery. However, there were no significant differences between the test and control groups at all times.

DISCUSSION

The present study was aimed to evaluate the effects of T-PRF treatment on the angiogenic biomarkers in GCF in infrabony defects of patients with chronic periodontitis. To the best of our knowledge, till date there are no published data on the use of T-PRF in the infrabony defects of patients with periodontitis. We observed that no additional benefit of T-PRF on angiogenic biomarkers after periodontal surgery in infrabony defects.

Various cells such as endothelial cells, white blood cells, platelets are included in wound repair and these cells play a major role in the coagulation phase and tissue regeneration by releasing growth factors and cytokines.^[30,31] Platelet-derived factors have been broadly used for clinical and surgical applications due to releasing important growth factors and other molecules.^[32-35] Growth factors are biologic mediators that regulate cellular events in tissue regeneration including cell proliferation, chemotaxis, differentiation, and matrix synthesis.^[36]

Different preparation protocols have been used for platelet concentrates to release growth factors. In a study evaluating growth factors from different platelet concentrate, it was shown that the amount of growth factors released from PRP was higher than that from PRF.^[37] Conversely, in another study, PRF released more autologous growth factors and more resistant effect on proliferation and differentiation of rat osteoblasts than PRP *in vitro*.^[38] *In vitro* studies, it has also shown that PRF influenced the proliferation and differentiation of osteoblast cells by releasing growth factors such as PDGF, TGF- β .^[9,39] In recent studies, it has demonstrated PRF stimulated osteoblast adhesion and the upregulation of collagen protein production.^[40] The structure of PRF would permit to cell migration and angiogenesis as a scaffold and would be a reservoir for growth factors, cytokines, providing a slow release over 7 days.^[9,41,42] In another study, in the treatment of periodontal intrabony defects, the combination of PRF and demineralized freeze-dried bone allografts (DFDBA) displayed better outcomes in probing depth reduction and clinical attachment level gain compared with DFDBA alone.^[23] In one histologic study comparing PRF combined with FDBA to FDBA alone in sinus floor elevation, it was demonstrated bone structures seem to be similar between groups and the combination of PRF and FDBA have

been accelerate bone regeneration and allow implant placement after only 4 months of healing.^[43] In our study, we investigated the effectiveness of T-PRF on angiogenic biomarkers in the surgical treatment of human periodontal endosseous defects. Tunali *et al.*^[44] defined the structural characteristics of T-PRF and compare it with PRF and they found that the T-PRF appeared to have organized network and its fibrin network covers larger area and also fibrin seemed thicker. The activation of platelets in titanium tubes brings some high feature to T-PRF. These structural differences could have provided to the formation of more polymerized fibrin due to better hemocompatibility of titanium.^[45] Due to this structure, T-PRF may last a bit longer in the tissue.^[46] Tunali *et al.*^[46] placed T-PRF under the mucoperiosteal flap and examined tissue samples obtaining from the region with hematoxylin eosin at the 3rd, 5th, 10th, 15th, and 30th days. According to this, its resorption started at the 5th day and it was not completely resorbed for up to 10 days. In our study, there were no significant differences between groups for the total amounts of PDGF-BB, VEGF-A, FGF-2, ANG, and ANT at all evaluation periods. This result may be attributed to preparation protocol of T-PRF. In our study, we prepared T-PRF as a membrane with finger pressure between sterile woven gauze and the remaining fluid was discarded. In a previous study, it was pointed out that the remaining liquid can be mixed with bone grafts and used as an additional source of growth factors.^[47] The another limitation of our study was the lack of any group treated with only conventional flap surgery or only T-PRF due to the split-mouth.

CONCLUSION

Within the limitations of this study, application of T-PRF combined with allograft in infrabony defects of patients with chronic periodontitis had no significant additional effects on angiogenic biomarkers in GCF. More studies are necessary to evaluate the clinical effects of T-PRF.

Acknowledgments

The authors pointed out their thanks to Mesut Akyol and Pervin Demir in the Department of Biostatistics and Medical Informatics, University of Yildirim Beyazit, Turkey, for providing statistics support.

Financial support and sponsorship

The Scientific Research Project Fund of Kirikkale University (Project number: 2014/18) supported this research.

Conflicts of interest

There are no conflicts of interest.

REFERENCES

- Martínez CE, Smith PC, Palma Alvarado VA. The influence of platelet-derived products on angiogenesis and tissue repair: A concise update. *Front Physiol* 2015;6:290.
- Laurens N, Koolwijk P, de Maat MP. Fibrin structure and wound healing. *J Thromb Haemost* 2006;4:932-9.
- Carlson NE, Roach RB. Platelet rich plasma: Clinical applications in dentistry. *J Am Dent Assoc* 2002;133:1383-6.
- Marx RE, Carlson ER, Eichstaedt RM, Schimmele SR, Strauss JE, Georgeff KR. Platelet-rich plasma: Growth factor enhancement for bone grafts. *Oral Surg Oral Med Oral Pathol Oral Radiol Endod* 1998;85:638-46.
- Dohan Ehrenfest DM, Rasmusson L, Albrektsson T. Classification of platelet concentrates: From pure platelet-rich plasma (P-PRP) to leucocyte- and platelet-rich fibrin (L-PRF). *Trends Biotechnol* 2009;27:158-67.
- Choukroun J, Adda F, Schoffler C, Verville A. Une opportunité en parodontologie: Le. *Implantodontie* 2001;42:55-62.
- Dohan DM, Choukroun J, Diss A, Dohan SL, Dohan AJ, Mouhyi J, *et al.* Platelet-rich fibrin (PRF): A second-generation platelet concentrate. Part I: Technological concepts and evolution. *Oral Surg Oral Med Oral Pathol Oral Radiol Endod* 2006;101:37-44.
- Dohan Ehrenfest DM, Diss A, Odin G, Doglioli P, Hippolyte MP, Charrier JB, *In vitro* effects of Choukroun's PRF (platelet-rich fibrin) on human gingival fibroblasts, dermal prekeratinocytes, preadipocytes, and maxillofacial osteoblasts in primary cultures. *Oral Surg Oral Med Oral Pathol Oral Radiol Endod* 2009;108:341-52.
- Dohan DM, de Peppo GM, Doglioli P, Sammartino G. Slow release of growth factors and thrombospondin-1 in Choukroun's platelet-rich fibrin (PRF): A gold standard to achieve for all surgical platelet concentrates technologies. *Growth Factors* 2009;27:63-9.
- Cieslik-Bielecka A, Gazdzik TS, Bielecki TM, Cieslik T. Why the platelet-rich gel has antimicrobial activity? *Oral Surg Oral Med Oral Pathol Oral Radiol Endod* 2007;103:303-5.
- Dohan DM, Choukroun J, Diss A, Dohan SL, Dohan AJ, Mouhyi J, *et al.* Platelet-rich fibrin (PRF): A second generation platelet concentrate. Part III: Leucocyte activation: A new feature for platelet concentrates? *Oral Surg Oral Med Oral Pathol Oral Radiol Endod* 2006;101:51-5.
- El-Sharkawy H, Kantarci A, Deady J, Hasturk H, Liu H, Alshahat M, *et al.* Platelet-rich plasma: Growth factors and pro- and anti-inflammatory properties. *J Periodontol* 2007;78:661-9.
- Del Corso M, Sammartino G, Dohan Ehrenfest DM. Re: Clinical evaluation of a modified coronally advanced flap alone or in combination with a platelet-rich fibrin membrane for the treatment of adjacent multiple gingival recessions: A 6-month study. *J Periodontol* 2009;80:1694-7.
- Sharma A, Pradeep AR. Autologous platelet rich fibrin in the treatment of mandibular degree II furcation defects: A randomized clinical trial. *J Periodontol* 2011;82:1396-403.
- Simonpieri A, Choukroun J, Del Corso M, Sammartino G, Dohan Ehrenfest DM. Simultaneous sinus-lift and implantation using microthreaded implants and leukocyte- and platelet-rich fibrin as sole grafting material: A six-year experience. *Implant Dent* 2011;20:2-12.
- O'Connell SM. Safety issues associated with platelet-rich fibrin method. *Oral Surg Oral Med Oral Pathol Oral Radiol Endod* 2007;103:587-93.
- Rudagi KB, Rudagi B. One-step apexification in immature tooth using grey mineral trioxide aggregate as an apical barrier and autologous platelet-rich fibrin membrane as an internal matrix. *J Conserv Dent* 2012;15:196-9.
- Ruga E, Gallesio C, Boffano P. Platelet rich fibrin and piezoelectric surgery: A safe technique for the prevention of periodontal complications in third molar surgery. *J Craniofac Surg* 2011;22:1951-5.
- Hoaglin DR, Lines GK. Prevention of localized osteitis in mandibular third molar sites using platelet-rich fibrin. *Int J Dent* 2013;875380.
- Mazor Z, Horowitz RA, Del Corso M, Prasad HS, Rohrer DR, Dohan Ehrenfest DM. Sinus floor augmentation with simultaneous implant placement using Choukroun's platelet-rich fibrin as the sole grafting material: A radiologic and histologic study at 6 months. *J Periodontol* 2009;80:2056-64.
- Tajima N, Ohba S, Sawase T, Asahina I. Evaluation of sinus floor augmentation with simultaneous placement using platelet-rich fibrin as sole grafting material. *Int J Oral Maxillofac Implants* 2013;28:77-83.
- Lekovic V, Milinkovic I, Aleksic Z, Jankovic S, Stankovic P, Kenney EB, *et al.* Platelet-rich fibrin and bovine porous bone mineral vs. platelet-rich fibrin in the treatment of intrabony periodontal defects. *J Periodontol* 2012;47:409-17.
- Bansal C, Bharti V. Evaluation of efficacy of autologous platelet-rich fibrin with demineralized-freeze dried bone allograft in the treatment of periodontal intrabony defects. *J Indian Soc Periodontol* 2013;17:361-6.
- Peck MT, Marnewick J, Stephen L. Alveolar ridge preservation using leukocyte and platelet-rich fibrin: A report of a case. *Case Rep Dent* 2011;345048.
- Hauser F, Gaydarov N, Badoud I, Vazquez L, Bernard JP, Ammann P. Clinical and histological evaluation of postextraction platelet-rich fibrin socket filling: A prospective randomized controlled study. *Implant Dent* 2013;22:295-303.
- Del Corso M, Mazor Z, Rutkowski JL, Dohan Ehrenfest DM. The use of leukocyte-and platelet-rich fibrin during immediate postextractive implantation and loading for the esthetic replacement of a fractured maxillary central incisor. *J Oral Implantol* 2012;38:181-7.
- Aroca S, Keglevich T, Nikolidakis D, Gera I, Nagy K, Azzi R, *et al.* Treatment of class III multiple gingival recessions: A randomized-clinical trial. *J Clin Periodontol* 2010;37:88-97.
- Jankovic S, Aleksic Z, Klokkevold P, Lekovic V, Dimitrijevic B, Kenney EB, *et al.* Use of platelet-rich fibrin membrane following treatment of gingival recession: A randomized clinical trial. *Int J Periodont Restorat Dent* 2012;32:41-50.
- Eren G, Atilla G. Platelet-rich fibrin in the treatment of bilateral gingival recessions. *Clin Adv Periodont* 2012;2:154-60.
- Barrientos S, Stojadinovic O, Golinko MS, Brem H, Tomic-Canic M. Growth factors and cytokines in wound healing. *Wound Repair Regen* 2008;16:585-601.
- Suzuki S, Morimoto N, Ikada Y. Gelatin gel as a carrier of platelet-derived growth factors. *J Biomater Appl* 2013;28:595-606.
- Eppley BL, Pietrzak WS, Blanton M. Platelet-rich plasma: A review of biology and applications in plastic surgery. *Plast Reconstr Surg* 2006;118:147-59.
- Nurden AT, Nurden P, Sanchez M, Andia I, Anitua E. Platelets and wound healing. *Front Biosci* 2008;13:3532-48.
- Blair P, Flaumenhaft R. Platelet alpha-granules: Basic biology and clinical correlates. *Blood Rev* 2009;23:177-89.
- Serra R, Buffone G, Dominijanni A, Molinari V, Montemurro R, de Francis S, Application of platelet-rich gel to enhance healing of transmetatarsal amputations in diabetic dysvascular patients. *Int Wound J* 2013;10:612-5.
- de Obarrio JJ, Araúz-Dutari JI, Chamberlain TM, Croston A. The use of autologous growth factors in periodontal surgical therapy:

- Platelet gel biotechnology: Case reports. *Int J Periodont Restorat Dent* 2000;20:486-97.
37. Gassling VL, Acil Y, Springer IN, Hubert N, Wiltfang J. Platelet-rich plasma and platelet-rich fibrin in human cell culture. *Oral Surg Oral Med Oral Pathol Oral Radiol Endod* 2009;108:48-55.
 38. He L, Lin Y, Hu X, Zhang Y, Wu H. A comparative study of platelet-rich fibrin (PRF) and platelet-rich plasma (PRP) on the effect of proliferation and differentiation of rat osteoblasts *in vitro*. *Oral Surg Oral Med Oral Pathol Oral Radiol Endod* 2009;108:707-13.
 39. Dohan DM, Choukroun J, Diss A, Dohan SL, Dohan AJ, Mouhyi J, *et al.* Platelet-rich fibrin (PRF): A second-generation platelet concentrate. Part II: Platelet-related biologic features. *Oral Surg Oral Med Oral Pathol Oral Radiol Endod* 2006;101:45-50.
 40. Wu CL, Lee SS, Tsai CH, Lu KH, Zhao JH, Chang YC. Platelet-rich fibrin increases cell attachment, proliferation and collagen-related protein expression of human osteoblasts. *Aust Dent J* 2012;57:207-12.
 41. Choukroun J, Diss A, Simonpieri A, Girard MO, Schoeffler C, Dohan SL, *et al.* Platelet-rich fibrin (PRF): A second-generation platelet concentrate. Part IV: Clinical effects on tissue healing. *Oral Surg Oral Med Oral Pathol Oral Radiol Endod* 2006;101:56-60.
 42. Dohan Ehrenfest DM, Bielecki T, Jimbo R, Barbé G, Del Corso M, Inchingolo F, *et al.* Do the fibrin architecture and leukocyte content influence the growth factor release of platelet concentrates? An evidence-based answer comparing a pure platelet-rich plasma (P-PRP) gel and a leukocyte- and platelet-rich fibrin (L-PRF). *Curr Pharm Biotechnol* 2012;13:1145-52.
 43. Choukroun J, Diss A, Simonpieri A, Girard MO, Schoeffler C, Dohan SL, *et al.* Platelet rich fibrin (PRF): A second-generation platelet concentrate. Part V: Histologic evaluations of PRF effect on bone allograft maturation in sinus lift. *Oral Surg Oral Med Oral Pathol Oral Radiol Endod* 2006;101:299-3.
 44. Tunali M, Özdemir H, Küçükodacı Z, Akman S, Yaprak E, Toker H, *et al.* A novel platelet concentrate: Titanium-prepared platelet-rich fibrin. *BioMed Res Int* 2014;209548.
 45. Takemoto S, Yamamoto T, Tsuru K, Hayakawa S, Osaka A, Takashima S. Platelet adhesion on titanium oxide gels: Effect of surface oxidation. *Biomaterials* 2004;25:3485-92.
 46. Tunali M, Özdemir H, Küçükodacı Z, Akman S, Yaprak E, Firatlı E. *In vivo* evaluation of titanium-prepared platelet-rich fibrin (T-PRF): A new platelet concentrate. *Br J Oral Maxillofac Surg* 2012;51:438-43.
 47. Su CY, Kuo YP, Tseng YH, Su CH, Burnouf T. *In vitro* release of growth factors from platelet-rich fibrin (PRF): A proposal to optimize the clinical applications of PRF. *Oral Surg Oral Med Oral Pathol Oral Radiol Endod* 2009;108:56-61.