

Case Report

The Importance of Early Diagnosis of Gardner's syndrome in Dental Examination

MZ Adisen, A Okkesim, M Misirlioglu

Department of Oral and Maxillofacial Radiology, Faculty of Dentistry, Kirikkale University, Kirikkale, Turkey

ABSTRACT

Gardner syndrome (GS) is a rare genetic disorder. Dentists play an important role in diagnosis considering that craniomaxillofacial osteomas are a major criteria for GS. We report a 26-year-old male patient who referred to our department with toothache. On routine panoramic radiographic examination, multiple radiopaque masses were detected incidentally. In addition, on extraoral examination, a soft tissue tumor was detected on his shoulder. The patient was referred to the gastroenterology department and intestinal polyps were detected in the colon. Histopathology report revealed malignant changes in the intestinal polyps. Early colectomy, which is a life-saving operation, was possible because of our early diagnosis.

Date of Acceptance:
15-Jan-2017

KEYWORDS: *Cone-beam CT, Gardner syndrome, osteoma, panoramic radiography*

INTRODUCTION

Gardner syndrome (GS) is a rare genetic disorder characterized by the triad of familial polyposis, multiple osteomas, and tumors of soft tissues.^[1] The colonic polyps usually undergo malignant change by the fourth decade. Skeletal abnormalities, the most common of which are osteomas, are an essential component of GS.^[2] They are most commonly found in the skull, mandible, facial bones, and paranasal sinuses.^[3] Jaw osteomas may be the first clinical finding of GS. This article presents a case of incidentally detected GS during routine dental examination, emphasizing the dental manifestations of the disease for early detection.

CASE REPORT

A 26-year-old male patient was referred to our Maxillofacial Radiology Department with toothache. On routine panoramic radiographic examination [Figure 1], multiple radiopaque masses with relatively well-circumscribed margins were detected incidentally involving the both maxilla and mandible. In particular, large lobulated masses at the bilateral angle of the mandible and diffuse sclerosis throughout the mandibular body were noted. He did not have any trauma history. Patient reported a desmoid tumor occurrence on his body and previously underwent a surgical operation for removal of a tumor on his chest. However, another tumor

occurred on his shoulder 1 year after surgical operation [Figure 2a]. No other tumor was detected on patient's body on clinical examination. In addition, there were no extraoral or intraoral findings such as swelling, stiffness, or evidence of facial asymmetry related to the lesions [Figure 2b] and he did not complain of any symptoms.

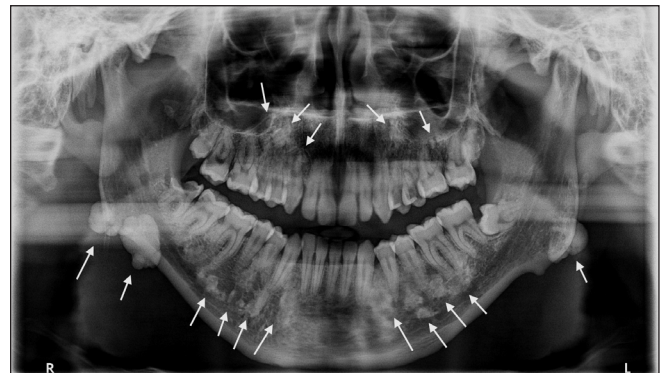


Figure 1: Panoramic radiographic examination revealed multiple radiopaque masses with relatively well-circumscribed margins were detected incidentally involving the both maxilla and mandible. In particular, large lobulated masses at bilateral angle of the mandible and diffuse sclerosis throughout the mandibular body were noted

Address for correspondence: Dr. Mehmet Zahit Adisen, Department of Oral and Maxillofacial Radiology, Faculty of Dentistry, Kirikkale University, Kirikkale, Turkey.
E-mail: m_zahit@hotmail.com

This is an open access article distributed under the terms of the Creative Commons Attribution-NonCommercial-ShareAlike 3.0 License, which allows others to remix, tweak, and build upon the work non-commercially, as long as the author is credited and the new creations are licensed under the identical terms.

For reprints contact: reprints@medknow.com

How to cite this article: Adisen MZ, Okkesim A, Misirlioglu M. The importance of early diagnosis of gardner's syndrome in dental examination. Niger J Clin Pract 2018;21:114-6.

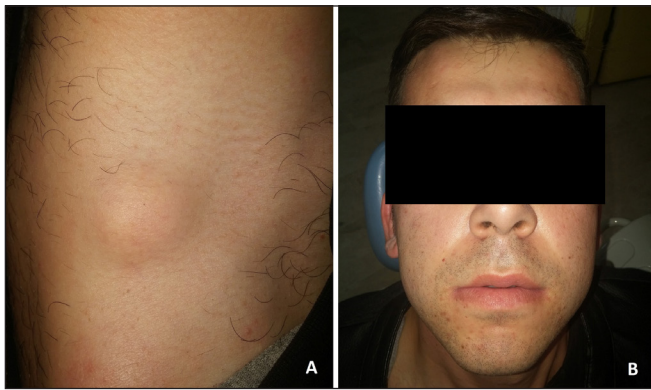


Figure 2: (a) Soft tissue tumor on patient shoulder. (b) There was no swelling, stiffness, or evident facial asymmetry related to lesions

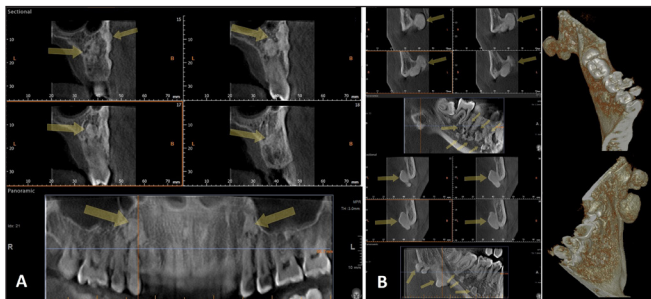


Figure 3: (a) Multiple enostosis located in the medullar (spongy) bone of the corpus of maxilla. (b) Multiple enostosis located in the medullar (spongy) bone of the corpus of mandible. Bilateral fungiform type osteomas were observed arising from angle of mandible

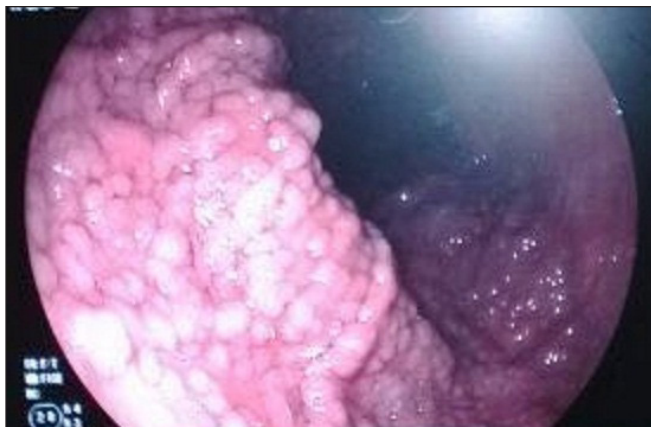

Figure 4: Showing intestinal polyps in the colon

The oral mucosa was normal and the regional lymph nodes were not palpable.

No trigeminal paresthesia was diagnosed, and facial nerve function was preserved. For differential diagnosis of radiopaque masses in jaws, multiple osteomas with GS, multiple submandibular sialoliths, tonsilloliths, or lymph node calcifications were considered.

Cone-beam computed tomography (CBCT) images acquired with PaxUni three-dimensional (3D) at the following settings: 50–90 kVp, 4–10 mA, and seconds

exposure time, and a 50 × 50 mm field of view (FOV) size, revealed multiple enostosis located in the medullar (spongy) bone of the corpus of the maxilla and mandible [Figure 3a]. In addition, bilateral mushroom shaped osteomas were observed at the angle of mandible [Figure 3b]. Because of the radiographic appearance and clinical findings of the lesion, a preliminary diagnosis of GS was made. The patient was referred to the department of gastroenterology for further evaluation and treatment. In colonoscopic examination, intestinal polyps were detected in the colon and were associated with a high risk of malignant transformation [Figure 4]. Histopathology report revealed malignant changes in intestinal polyps. Patient was appointed for early colectomy by a colorectal surgeon, which is a life-saving operation, was possible because of our early diagnosis.

DISCUSSION

Patients with GS have dental abnormalities such as odontomas, supernumerary teeth, compact or cancellous osteomas, osteosclerotic bone islands and impacted teeth, as extracolonic manifestations at an approximate rate of 30–75%.^[4,5] Especially, an osteoma is seen in 68-82% of affected patients.^[4] Ida *et al.* revealed that patients with more than three osteomas need to have the familial history checked, with an emphasis on intestinal disease, because this is highly suggestive of GS.^[6] The majority of individuals have a family history of this pathology, however, 25% of patients can present with a new dominant mutation and be the first member of their family.^[7] In our case, no other family members were known to have the disease.

The differential diagnosis of osteoma includes exostoses, osteochondroma, osteoblastoma, osteosarcoma, and complex odontoma. In general, exostoses have a limited growth and are located in marginal gingival and hard palate. Osteochondromas shows heterogeneous areas (radiopaque and radiolucent) and osteoblastoma and osteosarcoma have rapid growth.^[8]

Panoramic radiography may be useful in the early detection of GS by the dentist but may be limited for overall management. CBCT provides better characterization of the bony structures of the skull base and facial skeleton than conventional radiography providing cross-sectional images of the osteomas.^[9] Thus, CBCT scan has become an important diagnostic tool for maxillofacial lesions, however, only a few cases of GS have been studied using this technique. In our case report, we did not find relevant disfigurement and the invasion of the mandibular canal by the osteoma did not cause any clinical alteration on CBCT images.

Soft-tissue lesions such as fibromas, neurofibromas, keloids, sebaceous cysts, leiomyomas, and lipomas are also observed in GS.^[4,10] Desmoid tumors are considered locally invasive, nonmalignant, and may occur in the skin of the anterior abdominal wall or intraabdominally.^[5] These lesions occur in approximately 10% of patients.^[5] Female-to-male ratio is reported to be 3:1 for these tumors.^[11] The majority of cutaneous lesions observed in GS present as multiple epidermoid cysts on the face, scalp, and extremities. They are benign lesions that occur at an early age, around puberty.^[12]

CONCLUSION

In summary, osteoma is a benign neoplasm of bone that is characterized by slow continuous growth and is the most common accompanying bone lesion seen in GS. Osteoma is a painless tumor that may cause asymmetry in the maxillofacial region. It is generally removed for cosmetic reasons. Considering that polyposis normally develops after the osteomas, the maxillofacial manifestations should alert dental practitioners about the possibility of GS. As the syndrome is genetically inherited and this condition has implications for other family members, early diagnosis of GS by dental practitioners is essential to prevent the malignant transformation of polyps.

Acknowledgements

There are no acknowledgements.

Financial support and sponsorship

Nil

Conflicting Interest

There are no conflicts of interest.

REFERENCES

1. Smud D, Augustin G, Kekez T, Kinda E, Majerovic M, Jelincic Z. Gardner's syndrome: genetic testing and colonoscopy are indicated in adolescents and young adults with cranial osteomas: A case report. *World J Gastroenterol* 2007;13:3900-3.
2. Baykul T, Heybeli N, Oyar O, Dođru H. Multiple huge osteomas of the mandible causing disfigurement related with Gardner's syndrome: Case report. *Auris Nasus Larynx* 2003;30:447-51.
3. Lew D, DeWitt A, Hicks RJ, Cavalcanti MG. Osteomas of the condyle associated with Gardner's syndrome causing limited mandibular movement. *J Oral Maxillofac Surg* 1999;57:1004-9.
4. Ertas ET, Atıcı MY, Sözen E. Can careful dental and radiographic examination provide life-saving information? Early diagnosis of Gardner syndrome based on dentomaxillary findings. *Oral Radiol* 2016;1-5.
5. Panjwani S, Bagewadi A, Keluskar V, Arora S. Gardner's Syndrome. *J Clin Imaging Sci* 2011;1:65.
6. Ida M, Nakamura T, Utsunomiya J. Osteomatous changes and tooth abnormalities found in the jaw of patients with adenomatosis coli. *Oral Surg Oral Med Oral Pathol* 1981;52:2-11.
7. Patel H, Rees RT. Unicystic ameloblastoma presenting in Gardner's syndrome: A case report. *Br Dent J* 2005;198:747-8.
8. Kshirsagar K, Bhate K, Pawar V, SanthoshKumar S, Kheur S, Dusane S. Solitary Peripheral Osteoma of the Angle of the Mandible. *Case Rep Dent* 2015:2015.
9. Yuasa K, Yonetsu K, Kanda S, Takeuchi T, Abe K, Takenoshita Y. Computed tomography of the jaws in familial adenomatosis coli. *Oral Surg Oral Med Oral Pathol* 1993;76:251-5.
10. Basaran G, Erkan M. One of the rarest syndromes in dentistry: Gardner syndrome. *Eur J Dent* 2008;2:208-12.
11. Kawashima A, Goldman S, Fishman E, Kuhlman JE, Onitsuka H, Fukuya T, *et al.* CT of intraabdominal desmoid tumors: Is the tumor different in patients with Gardner's disease?. *AJR Am J Roentgenol* 1994;162:339-42.
12. Wesley RK, Cullen C, Bloom WS. Gardner's syndrome with bilateral osteomas of coronoid process resulting in limited opening. *Pediatr Dent* 1987;9:53-7.