


Rectal pyogenic granulomas: an uncommon cause of gastrointestinal bleeding

Tuba Devrim¹ , Özlem Gül Utku², Dilek Oğuz²

¹Department of Pathology, Kırıkkale University School of Medicine, Kırıkkale, Turkey

²Department of Internal Medicine, Kırıkkale University School of Medicine, Kırıkkale, Turkey

Cite this article as: Devrim T, Utku ÖG, Oğuz D. Rectal pyogenic granulomas: an uncommon cause of gastrointestinal bleeding. *Turk J Gastroenterol* 2018; 29: 126-7.

Dear Editor,

Pyogenic granuloma (PG), also known as lobular capillary hemangioma, is a type of benign vascular tumor that is typically visible with inflammatory vascular lesions. PGs affect the skin and oral mucosa; however, in rare cases, they have been reported in the gastrointestinal tract (1). Colonic PGs commonly emerge with hematochezia with or without anemia; occasionally, bleeding can be massive. Intestinal PGs are usually excised by endoscopic polypectomy and determining their endoscopic appearance is essential for appropriate treatment (2).

A 49-year-old woman was admitted to our hospital because of mucoid diarrhea. The findings of two colonoscopic examinations were normal. However, one year later, a colonoscopic examination identified a mucosal, sharp-edged, hyperemic, and edematous lesion at the distal third of the rectum. Biopsy samples revealed mild mucosal ischemia. One year later, a lesion was detected in the rectum, revealing microscopically ulcer and mucosal hyperplasia. After a 3-year follow-up, the lesion showed a polypoid structure (Figure 1) over the rectal plicae and they were identified as PGs. Microscopic (Leica, Germany) analyses demonstrated lobular patterns containing clusters of small capillaries lined by a single layer of endothelial cells (Figure 2). Endothelial cells lining the capillary loops were immunohistochemically stained with CD34 (Figure 3), which has been reported as the one of the most useful markers of PG (3). Additionally, the patient's final blood analysis revealed hypochromic microcytic anemia.

The widely accepted term of "lobular capillary hemangioma" emphasizes the essential component of the lesion.

ORCID ID of the authors: T.D. 0000-0002-5321-2002

This study was presented at the 27th Annual National Pathology Congress, 15-18 November 2017, Antalya, Turkey.

Address for Correspondence: Tuba Devrim E-mail: tubadevrim@gmail.com

Received: August 22, 2017 Accepted: September 1, 2017

© Copyright 2018 by The Turkish Society of Gastroenterology · Available online at www.turkjgastroenterol.org

DOI: 10.5152/tjg.2018.17551

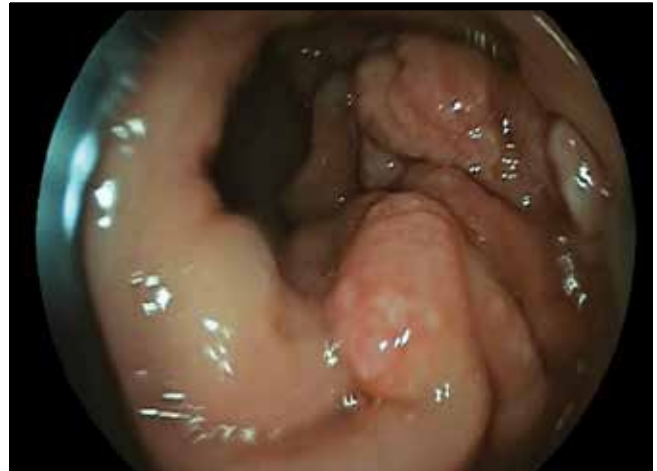

Figure 1. Endoscopic appearance of multiple pyogenic granulomas as polypoid rectal lesions

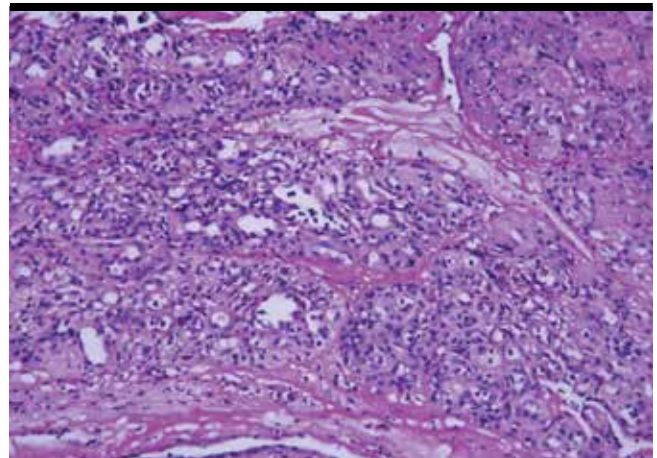


Figure 2. Proliferations of small and dilated capillaries arranged in a lobular pattern. The interlobular stroma is edematous and hemorrhagic and is infiltrated with inflammatory cells (hematoxylin-eosin, original magnification: 20×).

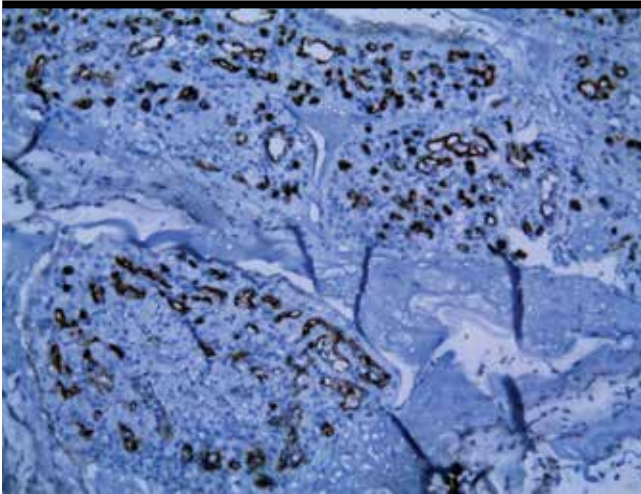


Figure 3. Endothelial cells displaying positive immunohistochemical staining for CD34 (original magnification: 20×)

Besides, PGs have been equated with granulation tissues, and this has resulted in uncertainty in the literature (1). It has been reported that PGs may be induced and reactivated by trauma, with the subsequent overgrowth of granulation tissue (4). Consistent with this opinion, by evaluating previous endoscopic and pathologic findings of the present case, it can be concluded that PGs may develop on the ulcer base and can be induced by trauma with the subsequent overgrowth of granulation tissue.

Although endoscopic resection is the most suitable treatment, surgical resection is the second treatment choice for gastrointestinal PGs. Endoscopic resection has been reported to be safer and more useful than surgical resection (4). Recently, the successful synchronized therapy of endoscopic resection and embolization of the nutrient artery of PG lesions has been reported (4).

Inflammatory polyps, benign and malignant vascular malformations, and angiomatous variants of Kaposi sarcoma have been considered in the differential diagnosis of PGs. Macroscopically, PGs can be misdiagnosed as colon car-

cinomas, particularly when they appear as large, circular, growing tumors (5).

To sum up, the patient who visited our hospital 5 years ago initially showed normal colonoscopy findings and blood levels; however, over time, exhibiting mucosal ischemia and ulceration was finally, following a preliminary query, she was diagnosed as having PGs due to endoscopic biopsy examination. In conclusion, the present case suggests that gastrointestinal PGs are probably originated from the textures of prior trauma, inflammation, or ulceration and it could be better to diagnose and treat them endoscopically to avoid comprehensive surgical intervention.

Peer-review: Externally peer-reviewed.

Author contributions: Concept - T.D., O.G.U., D.O.; Design - T.D., O.G.U., D.O.; Supervision - T.D., O.G.U., D.O.; Resource - T.D., O.G.U., D.O.; Materials - T.D., O.G.U., D.O.; Data Collection and/or Processing - T.D., O.G.U., D.O.; Analysis and/or Interpretation - T.D., O.G.U., D.O.; Literature Search - T.D., O.G.U., D.O.; Writing - T.D., O.G.U., D.O.; Critical Reviews - T.D., O.G.U., D.O.

Conflict of Interest: No conflict of interest was declared by the authors.

Financial Disclosure: The authors declared that this study has received no financial support.

REFERENCES

1. De María J, Curvale C, Guidi M, Hwang H, Matanó R. Pyogenic granuloma of the jejunum; diagnosis and treatment with double-balloon enteroscopy: A case report. *Rev Gastroenterol Mex* 2017; 82: 94-6. [\[CrossRef\]](#)
2. Lui KL, Ng KS, Li MK. A rare cause of haematochezia: pyogenic granuloma in colon. *Hong Kong Med J* 2014; 20: 168.e1-2. [\[CrossRef\]](#)
3. Nakaya T, Tokunaga T, Aono S, et al. Pyogenic granuloma of the descending colon. *Endoscopy* 2007; 39: 259-60. [\[CrossRef\]](#)
4. Lin C, Hsieh Y, Hsu C, et al. Clinical and endoscopic features of gastric pyogenic granuloma. *Advances in Digestive Medicine* 2014; 1:118-25. [\[CrossRef\]](#)
5. González-Vela MC, Val-Bernal JF, Garijo MF, García-Suárez C. Pyogenic granuloma of the sigmoid colon, *Ann Diagn Pathol* 2005; 9: 106-9. [\[CrossRef\]](#)