

## SHORT REPORT

### Case Report: Intramesocolic Malposition of the Gallbladder

Oral SAYGUN, Kuzey AYDINURAZ, Cağatay DAPHAN, Abdullah AKKUS, Fatih AĞALAR

Department of General Surgery, Faculty of Medicine, Kırıkkale University, Kırıkkale - Turkey

Received: March 19, 2004

**Key Words:** Gallbladder, anomaly, malposition, cholecystectomy

The gallbladder may be found in a variety of abnormal positions (1). Most of them are due to arrested development at some stage of embryonic growth. If an anomaly is present in this region, it is frequently associated with an anomaly of the blood supply and vice versa (2). We report a case of intramesocolic malposition of the gallbladder, which was removed safely by conversion to an open procedure.

#### Case Report

A 43-year-old male patient was admitted to the hospital with nausea and moderate intermittent right upper quadrant pain radiating to the right scapula. On physical examination, there was mild epigastric tenderness and Murphy's sign was positive. The leucocyte count was 10,900/ml. Hepatobiliary ultrasonography revealed a 4 mm wall thickness and a single intraluminal gallstone 10.4 mm in diameter. There were no other pathologic findings. As these findings were consistent with biliary colic, laparoscopic cholecystectomy was scheduled. It was noted that the fundus, corpus and infundibulum of the gallbladder were resting in the peritoneal layers of the transverse mesocolon and so conversion to laparotomy through a right subcostal incision was performed in order to verify the situation (Figure). No other anomaly was detected. The gallbladder was successfully excised from the mesocolon by retrograde dissection. The cystic artery and cystic duct showed no anomaly. A few accessory

vessels arising from the mesocolon were ligated and cholecystectomy was completed. The postoperative course was uneventful.

Important anomalies of the gallbladder are related to number (agenesis, double or bilobed gallbladder), form (phyrgian cap, hourglass) and position (1). Abnormal position of the gallbladder seems to be rare. Although classically 5 malpositions of the gallbladder have been described (left-sided, transverse position, retroperitoneal, floating, and intrahepatic) (2), other ectopic gallbladder sites have also been reported (lesser omentum, retroduodenal, within the falciform ligament, within the abdominal wall muscles, and intrathoracic) (3-6). Although it is known that the normal anatomy of the extrahepatic biliary passages and their arterial supplies are observed in only about one-third of patients, malposition of the gallbladder is rare. We could not find any case of a gallbladder located in the mesocolon in the English literature.

Preoperative diagnosis of such cases is difficult (7). In the present case the ultrasonographic (US) findings were not consistent with intraoperative findings. It is suggested that cholecystectomy should be performed in ectopic gallbladders even if they are asymptomatic (8). As most of these anomalies may result in pitfalls at US imaging, knowledge of the wide range of US findings of malposition of the gallbladder helps to avoid misdiagnosis and helps the patient obtain the proper approach for ectopic gallbladder (9,10).

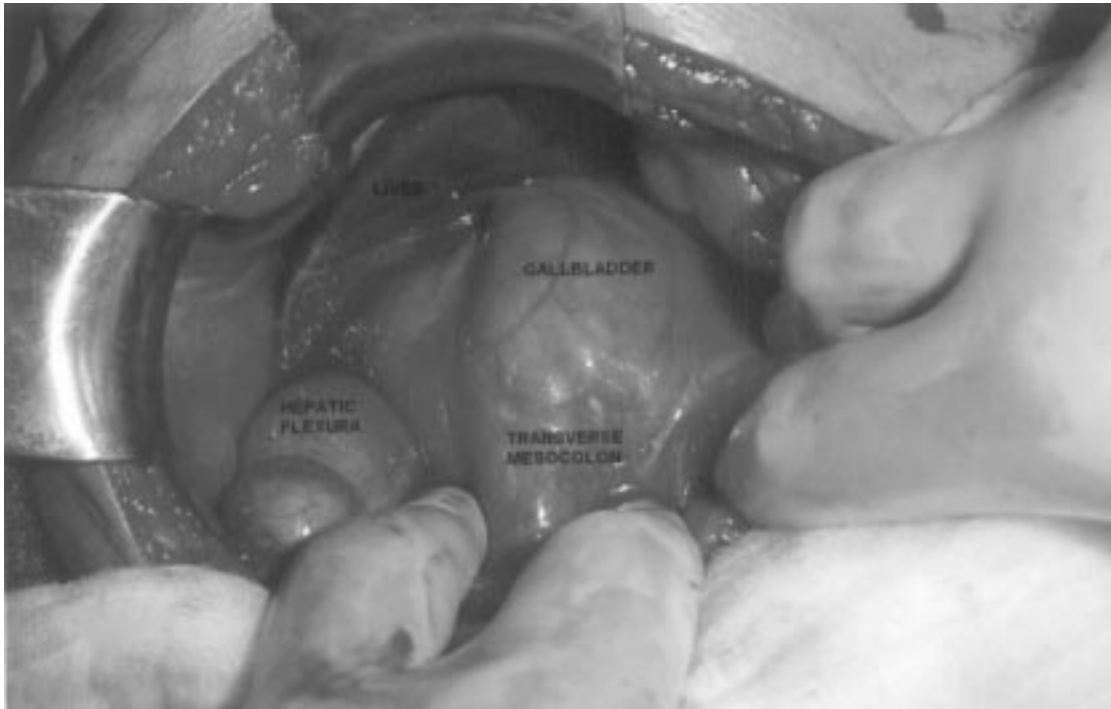


Figure. Intramesocolic malposition of the gallbladder.

Early conversion to an open procedure may help to minimize complications in the presence of unexpected findings especially in such cases that may have an intrinsic risk of accompanying arterial and/or duct anomalies.

*Corresponding author:*

Oral SAYGUN  
Emek Mah. 60. Sokak, No:2/2  
06510 Ankara - TURKEY  
E-mail: oralsaygun@yahoo.com

**References**

1. Schwartz SI. Gallbladder and extrahepatic biliary system. Principles of Surgery (Eds. Schwartz SI, Shires GT, Spencer FC). Int. Ed. McGraw-Hill, 1999, pp:1437-1466.
2. Gadacz TR. Anatomy, embryology, anomalies and physiology of the gallbladder and biliary ducts. Shackelford's Surgery of the Alimentary Tract Vol. 3 (Eds. Zuidema GD, Yeo CJ) 5th ed. W.B. Saunders, Philadelphia, 2002, pp:143-155.
3. Azmat N, Francis KR, Mandava N et al. Agenesis of the gallbladder revisited laparoscopically. Am J Gastroenterol 88: 1269-70, 1993.
4. Principe A, Spangaro M, Lapilli A et al. Congenital anomalies of the gallbladder. A case of retrohepatic gallbladder contained in the coronary ligament. Minerva Chir 34: 879-84, 1979.
5. Alawaneh I. Anomaly of the gallbladder lying extraperitoneally in the internal oblique muscle: report of an unusual case. Int Surg 64: 45-7, 1979.
6. Labitzke R. Congenital intrathoracic ectopic gallbladder, a currently unreported developmental disorder. Attempt at a classification of abnormal gallbladder sites. Chirurg 62: 755-8, 1991.
7. Senecail B, Nonent M, Kergastel I et al. Ultrasonic features of congenital anomalies of the gallbladder. J Radiol 81: 1591-4, 2000.
8. Tzardinoglou E, Prousalidis J, Apostolidis S et al. Hanging noncalculous gallbladder. HPB Surg 9: 137-9, 1996.
9. Naganuma S, Ishida H, Konno K et al. Sonographic findings of anomalous position of the gallbladder. Abdom Imaging 23: 67-72, 1998.
10. Buschulte J, Brands W, Wirth H. Atopic gallbladder. Case report, embryologic etiology and review of the literature. Langenbecks Arch Chir 377: 53-5, 1992.