

Three Adnexal Tumors in a Single Lesion: A Case Report

Tek Lezyonda Üç Adneksal Tümör: Olgu Sunumu

Elif Sari¹, Ugur Horoz², Hulda Rifat Ozakpinar², Emre Inozu², Ali Teoman Tellioglu³, Bilgihan Acikgoz⁴

¹ Kirikkale University Faculty of Medicine, Plastic, Reconstructive and Aesthetic Surgery Department, Kirikkale, Turkey

² Diskapi Yildirim Beyazit Education and Research Hospital, Plastic, Reconstructive and Aesthetic Surgery Clinic, Ankara, Turkey

³ Yildirim Beyazit University Faculty of Medicine, Plastic, Reconstructive and Aesthetic Surgery Department, Ankara, Turkey

⁴ Diskapi Yildirim Beyazit Education and Research Hospital, Pathology Clinic, Ankara, Turkey

ABSTRACT

Eccrine poroma is a benign tumor originating from the epidermal sweat duct unitis. Malignant transformation may occur in these lesions, and symptoms of bleeding, pain, and pruritus suggest potential malignancy. Common sites of involvement include plantar, palmar, and acral skin, but eccrine poromas may occur in any skin surface area with sweat glands. Hidroacanthoma simplex, eccrine poroma, dermal duct tumor and poroid hidradenoma are four histopathologic types of poroma or poroid neoplasms. Some authors have reported a combination of two or three of these tumors in a single lesion. As far as we know, the overlapping eccrine ductal tumor that covers eccrine poroma(EP), dermal duct tumor(DDT), and eccrine hidradenoma(EH)) has not been reported in the literature. The aim of this report is to present this rare case.

Key Words: Eccrine poroma, overlap eccrine duct tumor dermal duct tumor, eccrine hidradenoma

Received: 04.07.2014

Accepted: 05.08.2014

ÖZET

Ekrin poroma, epidermal ter bezi ünitelerinden kaynaklanan benign bir tümördür. Bu lezyonlarda malignleşme potansiyeli olabilir ve kanama, ağrı ve kaşıntı bulguları potansiyel bir maligniteyi akla getirmektedir. Plantar, palmar ve akral deri sıkça etkilenen alanları içermektedir, fakat ekkrin poromalar ter bezleri içeren herhangi bir deri alanında da oluşabilirler. Hidroakantoma simpleks, ekkrin poroma, dermal kanal tümörü ve poroid hidradenom poroma poroid neoplazmların 4 tipidir. Bazı yazarlar bu tümörlerden iki ya da üçünün tek bir lezyonda ilişkili olduklarını raporlamışlardır. Bildiğimiz kadarıyla ekkrin poroma(EP), dermal kanal tümörü(DDT) ve erkin hidradenom(EH) içeren çakışmış ekkrin duktal tümör literatürde yayınlanmamıştır. Bu bildirin amacı, nadir olan bu olguyu sunmaktır.

Anahtar Sözcükler: Ekkrin poroma, çakışan ekkrin kanal tümörü, dermal kanal tümörü, ekkrin hidradenom

Geliş Tarihi:07.04.2014

Kabul Tarihi: 08.05.2014

INTRODUCTION

Eccrine poroma was first described in 1956 by Goldman et al. as a benign tumor originating from the epidermal sweat duct unitis(1). These rare tumors typically present as a soft sessile reddish papule or nodule protruding from a cup-shaped depression. Malignant transformation may occur in these lesions, and symptoms of bleeding, pain, and pruritus suggest potential malignancy. Common sites of involvement include plantar, palmar, and acral skin, but eccrine poromas may occur in any skin surface area which contains sweat glands(2). The peak incidence of porocarcinomas is in the seventh decade of life, and they appear to be slightly more common among males than females(3). Also young and child patients have been recently reported in the series(4).

Four histopathologic types of poroma or poroid neoplasm were defined by Abenoza and Ackerman in 1990. They are hidroacanthoma simplex, eccrine poroma, dermal duct tumor and poroid hidradenoma (PH)(5). Some authors have reported the association of two or three of these tumors in a single lesion(6,7). In this paper, a case of an overlapping eccrine duct tumor [eccrine poroma(EP)+ dermal duct tumor(DDT)+ eccrine hidradenoma(EH)] is reported.

This article was reported as an oral presentation in BAPRAS Congress 2013, Budva, Montenegro.

Address for Correspondence / Yazışma Adresi: Elif Sari, MD Kirikkale University Faculty of Medicine, Plastic, Reconstructive and Aesthetic Surgery Department, Yahsihan, Kirikkale, Turkey Phone: +90 506 381 37 03 Fax: +90 580 225 28 19 E-mail: drelifsanli@hotmail.com

©Telif Hakkı 2014 Gazi Üniversitesi Tıp Fakültesi - Makale metnine <http://medicaljournal.gazi.edu.tr/> web adresinden ulaşılabilir.

©Copyright 2014 by Gazi University Medical Faculty - Available on-line at web site <http://medicaljournal.gazi.edu.tr/>

doi: <http://dx.doi.org/10.12996/gmj.2014.37>

CASE REPORT

A 35-year-old male patient was referred to our clinic with a 3-year history of a continuously growing and frequently bleeding tumor on the back of his thigh (Figure 1). There was no trauma or infection history. Examination revealed a round, erythematous, erosive tumor, approximately 2x2 cm sized. The patient had no lymphadenopathy or weight loss. The lesion was excised completely with clear surgical margins under local anesthesia. No relapses were detected after a 1 year follow-up.

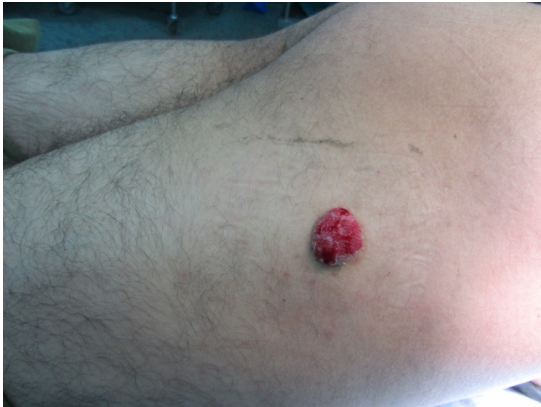

Figure 1. Preoperative view of the lesion. A solitary 2x2 cm sized red-colored mass on the back of the thigh. It had a rough surface that showed hemorrhagic crusts.

Histological examination was demonstrated ductal differentiations, eccrine and dermal duct tumor islands(Figures 2- 4).

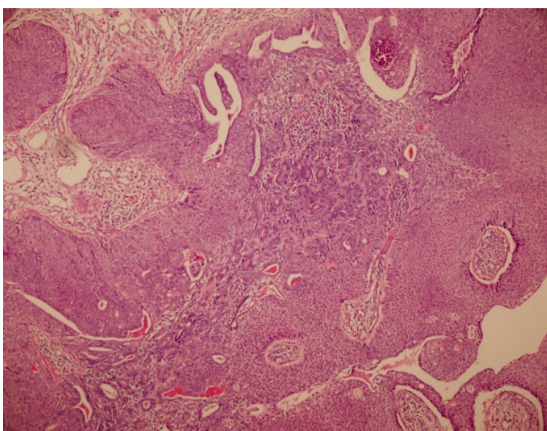


Figure 2. H&E x200 Ductal differentiation areas of the tumor.

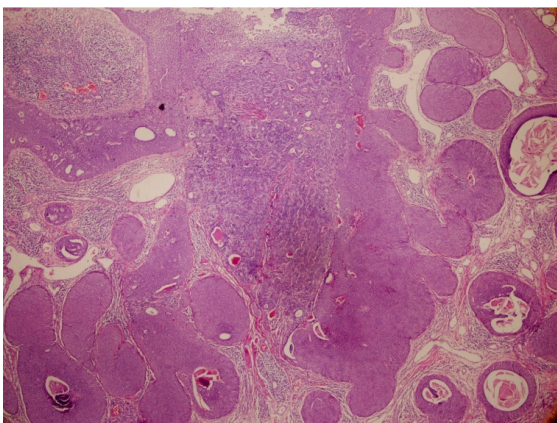


Figure 3. H&E x100 Eccrine poroma and dermal duct tumor areas may be seen in this view.

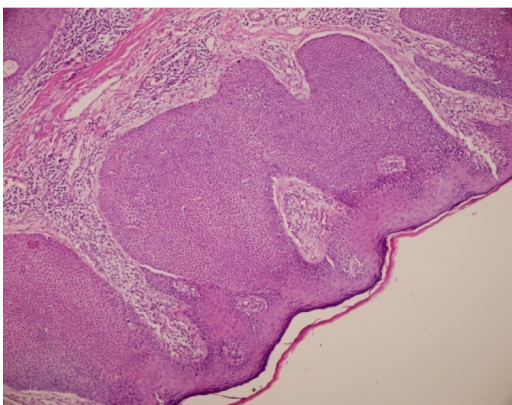


Figure 4. H&E x40 Eccrine hidradenoma islands that were located near the lesion.

DISCUSSION

Eccrine poroma is common, benign, slow growing solitary adnexal tumor originating from the intraepidermal portion of the eccrine sweat gland. This malignancy most commonly affects elderly patients, but may also occur at any age(1). Subsequently, many cases have been reported with approximately two thirds of the cases occurring on the sole or on the side of the foot, which is an area with a high concentration of eccrine sweat glands. Other common sites are the hand and finger, with sporadic occurrences on the neck, chest, forehead, nose and scalp(1).

Although eccrine poroma is known to be benign, the variants of eccrine poroma seem to frequently have malignant features. Robson et al. reported that coexistence between benign eccrine poroma and eccrine porocarcinoma is encountered in up to 11% of the cases(8). Clinically, the neoplasm exhibits an important polymorphism, which can make diagnosis difficult. Wart, pyogenic granuloma, basal cell carcinoma, or intradermal nevus may be suspected. Characteristic histologic findings confirm the diagnosis.

There are several particular subtypes of eccrine poroma. In hidroacanthoma simplex, neoplastic lesions are located entirely within the epidermis. In dermal duct tumor, the neoplasm is located largely or entirely within the dermis. Poroid hidradenoma consists of a large, sometimes multinodular, aggregation of neoplastic cells with varying proportions of cystic and solid components(9). Because eccrine poromas may recur after incomplete removal and because malignant variants have been described, complete surgical excision is a safe treatment choice. Malignant degeneration may take place in longstanding solitary lesions and cutaneous and fatal visceral metastases have been reported(10,11).

In the literature eccrine poroma with poroid hidradenoma, eccrine poroma with eccrine porocarcinoma, poroma with sebaceous differentiation, eccrine poroma with dermal duct tumor and hidroacanthoma simplex in the single lesions were reported (6, 12). But as far as we know, an overlap of eccrine poroma with ductal duct tumor and eccrine hidradenoma was not reported before. Therefore, this triple combination should be kept in mind and wide excisions should be done for the treatment.

Conflict of Interest

No conflict of interest was declared by the authors.

REFERENCES

1. Kang MC, Kim SA, Lee KS, Cho JW. A Case of an Unusual Eccrine Poroma on the Left Forearm Area. *Ann Dermatol* 2011; 23: 250-3.
2. Jagdeo J, Robinson-Bostom L, Long T. Unusual clinical presentation of benign eccrine poroma. *J Am Acad Dermatol* 2006; 54: 733-4.
3. Gerber PA, Schulte KW, Ruzicka T, Bruch-Gerharz D. Eccrine Porocarcinoma of the Head: An Important Differential Diagnosis in the Elderly Patient. *Dermatology* 2008;216:229- 33.
4. Orlandi C, Arcangeli F, Patrizi A, Neri I. Eccrine Poroma in a Child. *Pediatric Dermatology* 2005; 22: 279- 80.
5. Abenzoza P, Ackerman AB. eds. Poromas. In *Neoplasms with eccrine differentiation*. Philadelphia, PA: Lea&Febiger, 1990; 113.
6. Kakinuma H, Miyamoto R, Iwasawa U, Baba S, Suzuki H. Three subtypes of poroid neoplasia in a single lesion: eccrine poroma, hidroacanthoma simplex, and dermal duct tumor. *Histologic, histochemical, and ultrastructural findings*. *Am J Dermatopathol* 1994; 16: 66.
7. Misago N, Kohda H. A single lesion demonstrating features of eccrine poroma and poroid hidradenoma. *J Dermatol* 1995; 22: 773.
8. Robson A, Greene J, Ansari N, Kim B, Seed PT, McKee PH et al. Eccrine porocarcinoma (malignant eccrine poroma): a clinicopathologic study of 69 cases. *Am J Surg Pathol* 2001; 25: 710- 20.
9. Harada T, Miyamoto T, Takahashi M, Tsutsumi Y. Eccrine poroma in the external auditory canal. *Otolaryngology - Head and Neck Surgery*. 2003; 128: 439.
10. Valverde K, Senger C, Ngan BY, Chan HS. Eccrine porocarcinoma in a child that evolved rapidly from an eccrine poroma. *Med Pediatr Oncol* 2001;37: 412- 4.
11. Labbé D, Harbon S, Domp martin A, Mandard JC, Leroy D, Compere JF. Malignant eccrine poroma. Apropos of two facial sites. *Ann Chir Plast Esthet* 1989;34: 146- 52.
12. Chiu HH, Lan CCH, Wu CS, Chen GS, Tsai KB, Chen PH. A single lesion showing features of pigmented eccrine poroma and poroid hidradenoma. *J Cutan Pathol* 2008; 35: 861- 5.