

## An Ectopic Case of *Psoroptes cuniculi* Infestation in a Pet Rabbit

Abuzer ACAR<sup>1</sup>, Arif KURTDEDE<sup>2</sup>, Kerem URAL<sup>3,\*</sup>, Cenker Çağrı CINGİ<sup>1</sup>, Mehmet Çağrı KARAKURUM<sup>4</sup>,  
Buğrahan Bekir YAĞCI<sup>5</sup>, Barış SARI<sup>6</sup>

<sup>1</sup>Department of Internal Medicine, Faculty of Veterinary Medicine, Afyon Kocatepe University, Afyon - TURKEY

<sup>2</sup>Department of Internal Medicine, Faculty of Veterinary Medicine, Ankara University, 06110, Ankara - TURKEY

<sup>3</sup>Republic of Turkey Ministry of Agriculture and Rural Affairs, Board of High Stewards, Ankara - TURKEY

<sup>4</sup>Department of Internal Medicine, Faculty of Veterinary Medicine, Mehmet Akif Ersoy University, Burdur - TURKEY

<sup>5</sup>Department of Internal Medicine, Faculty of Veterinary Medicine, Kırıkkale University, Kırıkkale - TURKEY

<sup>6</sup>Department of Parasitology, Faculty of Veterinary Medicine, Kafkas University, Kars - TURKEY

Received: 30.03.2007

**Abstract:** A 2-year-old female New Zealand rabbit was admitted to Ankara University Veterinary Faculty, Department of Internal Medicine. Upon physical examination crustaceous auricular lesions, and erythematous and exudative pruritic skin lesions, both on the ventral abdomen and on extremities were detected. Microscopic examination of skin scrapings taken from pinnae and hair plucked from the ventral abdominal region revealed the presence of *Psoroptes cuniculi*. The ventral abdominal localization of *P. cuniculi* was evaluated as an ectopic infestation. Despite the injection of ivermectin 400 µg/kg and daily supportive therapy the rabbit died on the fifth day of hospitalization.

**Key Words:** Ectopic localization, *Psoroptes cuniculi*, rabbit

### Bir Pet Tavşanında Ektopik *Psoroptes cuniculi* İnfestasyonu Olgusu

**Özet:** İki yaşlı dişi Yeni Zelanda tavşanı Ankara Üniversitesi Veteriner Fakültesi İç Hastalıkları Kliniğine getirildi. Fiziksel muayenede kulakta kabuklu lezyonların yanısıra karın altında ve ekstremitelerde eritematöz ve eksudatif kaşıntılı deri lezyonları belirlendi. Kulaktan alınan deri kazıntılarında ve karın altı bölgesinden alınan tüy örneğinde *Psoroptes cuniculi*'nin varlığı belirlendi. *Psoroptes cuniculi*'nin karın altına yerleşimi ektopik infestasyon olarak değerlendirildi. Sağaltımda 400 µg/kg dozunda ivermektin enjeksiyonu ve günlük destekleyici bakıma rağmen tavşan kliniğe getirildikten 5 gün sonra öldü.

**Anahtar Sözcükler:** Ektopik yerleşim, *Psoroptes cuniculi*, tavşan

### Introduction

*Psoroptes cuniculi*, a common ectoparasite of rabbits, causes otoacariasis with severe erythematous, crustaceous, and exudative pruritic skin inflammation (1). Psoroptic mites are mainly found inside the pinnae, where crust and scabs are created (2-4). Itchy ears, erythema, and crusting lesions of the external ear canal, and pain on palpation are the main clinical findings (1). Multiple doses of ivermectin (5,6) were reported to cure *P. cuniculi* infestation in rabbits. Moxidectin (7) and selamectin (8,9) were also reported for the treatment of psoroptic mange in rabbits.

### Case History

A 2-year-old female New Zealand rabbit presented with bilateral crusting inside the pinnae and pruritic ventral abdominal skin lesions. The owner housed the rabbit in a moist and dirty environment and fed it home-made food. The owner first noticed scaling inside both pinnae 2 weeks prior to presentation. Clinical examination revealed severe bilateral crustaceous lesions in both pinnae, with a brown discharge (Figure 1a), and erythematous, exudative, and alopecic skin lesions with pruritis on the ventral abdomen and extremities (Figure 1b).

\*E-mail: uralkerem@gmail.com

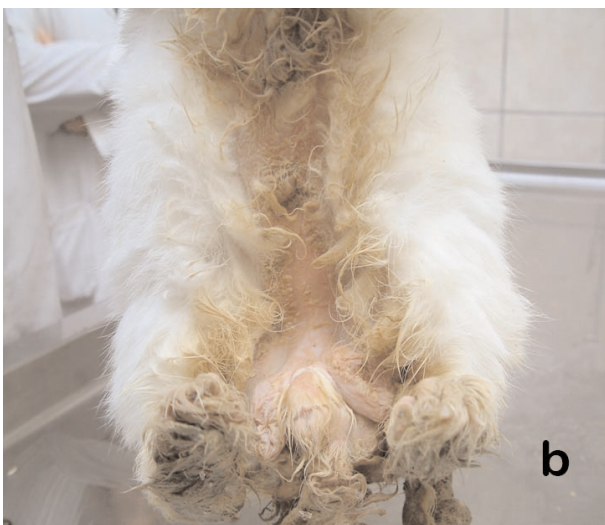

Figure 1. Lesions on the rabbit. a) Inner surface of the pinna; b) ventral abdomen and extremities.

## Results and Discussion

Skin scrapings taken from both pinnae and hair plucked from the ventral abdominal region were mixed with mineral oil and examined under the low power objective of a microscope. The observation of an oval body shape, pointed mouth parts, and jointed pedicles with funnel-shaped suckers (10) confirmed the diagnosis of *P. cuniculi* (Figure 2). The presence of *P. cuniculi* was confirmed in both the skin scrapings from the pinnae and the hair from the ventral abdomen.

Ectoparasites are frequently found on rabbits (1). The universal parasite, *P. cuniculi*, has mainly been found inside the rabbit pinnae; however, in advanced cases or in older, sick, and untreated animals the parasite, on occasion, colonizes and infests other parts of the body,

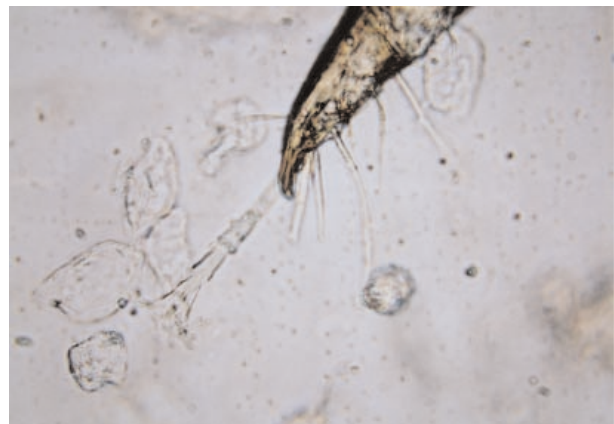


Figure 2. The jointed pedicle with funnel-shaped sucker of the parasite.

including the head, neck, legs, perianal region, and ventral abdomen (2,11). In the presented case, *P. cuniculi* was diagnosed in both ear canals and on the ventral abdominal region, an infrequent localization, as reported previously (3,12).

Initial treatment consisted of a single subcutaneous ivermectin injection of 400 µg/kg, lavaging the external ear canal with topical 0.1% iodine solution in water, and administering gentamycin solution into the ear canals. Despite daily subcutaneous 5% dextrose plus ringer solution and intramuscular AD<sub>3</sub>E vitamin injections, the rabbit's condition gradually deteriorated and it died 5 days after it was hospitalized in our clinic. At presentation, excluding the dermatological problems, the rabbit seemed otherwise healthy. No other macro-pathological condition was detected at that time. However, necropsy was not performed as per the owner's wish; therefore, it would be unwise to draw conclusions about the cause of death. Indeed it is possible that although the rabbit had psoroptic infestation immunosuppression might have played a role in its death.

The treatment regime for *P. cuniculi* infestation includes subcutaneous administration of 2 doses of 1% ivermectin solution, 300-400 µg/kg, 14 days apart (1,13); however, Hillyer (14) recommended the administration of 3 doses. In one previous report, ivermectin combined with a single topical application of fipronil spray was found to be safe and successful in eliminating *P. cuniculi* infestation. Nonetheless, the manufacturers of fipronil (Frontline®, Merial) strongly recommend not using this product on rabbits because of

serious adverse effects. The therapeutic failure in the presented case was considered to have resulted from the debilitation caused by severe infestation of the pinnae and ventral abdominal skin.

It was concluded that *P. cuniculi* lesions, which are found mainly inside the pinnae and/or head, could localize

on the ventral abdominal region in generalized cases (ectopic psoroptic scabies). In heavily infested cases ivermectin injection, local treatment, and parenteral supportive therapy may be incapable of preventing death in rabbits.

## References

1. Harrenstien, L., Gentz, E.J., Carpenter, J.W.: How to handle respiratory, ophthalmic, neurologic, and dermatologic problems in rabbits. Symposium on Rabbit Medicine. Veterinary Medicine. April 1995; 373-380.
2. Burke, T.J.: Skin disorders of rodents, rabbits and ferrets. In: Kirk, R.W., Bonagura, J.D. Eds. Current Veterinary Therapy XI Small Animal Practice. W.B. Saunders Co., Philadelphia, London, Toronto, 1992; 1170-1175.
3. Cutler, S.L.: Ectopic *Psoroptes cuniculi* infestation in a pet rabbit. J. Small Anim. Pract., 1998; 39: 86-87
4. Harkness, J.E., Wagner, J.E.: Specific diseases. In: The Biology and Medicine of Rabbits and Rodents. Lea & Febiger. Philadelphia. 1977; 73-75.
5. Curtis, S.K., Housley, R., Brooks, D.L.: Use of ivermectin for treatment of ear mite infestation in rabbits. J. Am. Vet. Med. Assoc., 1990; 196: 1139-1140.
6. Curtis, S.K., Brooks, D.L.: Eradication of ear mites from naturally infested conventional research rabbits using ivermectin. Lab. Anim. Sci., 1990; 40: 406-408.
7. Wagner, R., Wendlberger, U.: Field efficacy of moxidectin in dogs and rabbits naturally infested with *Sarcoptes* spp., *Demodex* spp. and *Psoroptes* spp. mites. Vet. Parasitol., 2000; 93: 149-158.
8. McTier, T.L., Hair, J.A., Walstrom, D.J., Thompson, L.: Efficacy and safety of topical administration of selamectin for treatment of ear mite infestation in rabbits. J. Am. Vet. Med. Assoc., 2003; 223: 322-324.
9. Kurtdede, A., Karaer, Z., Acar, A., Guzel, M., Cingi, C.C., Ural, K., Ica, A.: Use of selamectin for the treatment of psoroptic and sarcoptic mite infestation in rabbits. Vet. Dermatol., 2007; 18: 18-22.
10. Urquhart, G.M., Armour, J., Duncan, J.L., Dunn, A.M., Jennings, F.W.: Veterinary Parasitology. Blackwell Science. Oxford. 1996; 197.
11. Yeates, J.W.G.: Rabbit mite infestation. Vet. Rec., 1994; 134: 359-360.
12. Perucci, S., D'Agostino, C.: Life-cycle stage morphology and ectopic localization of *Psoroptes cuniculi*, XXII Congresso Nazionale della Società Italiana di Parasitologia. Grugliasco, Torino, Italy. 2002; 52-53
13. Okerman, L.: Diseases of the skin. In: Diseases of Domestic Rabbits. Blackwell Scientific, Oxford. 1994; 52-53.
14. Hillyer, E.V.: Pet rabbits. Vet. Clin. North Am. Small Anim. Pract., 1994; 24: 25-65.