

## Clinical and Surgical Evaluation of Perineal Hernia in Dogs: 41 Cases

Zeynep PEKCAN \*  Omer BESALTİ \*\* Yusuf Sinan SİRİN \*\*\* Murat CALISKAN \*\*

\* Kirikkale University, Faculty of Veterinary Medicine, Department of Surgery, TR-71491 Yahsihan, Kirikkale - TURKEY

\*\* Ankara University Faculty of Veterinary Medicine Department of Surgery, TR-06110 Diskapi, Ankara - TURKEY

\*\*\* Mehmet Akif Ersoy University Faculty of Veterinary Medicine Department of Surgery, TR-15100 Burdur - TURKEY

**Makale Kodu (Article Code): KVFD-2009-1149**

### Summary

The purpose of the study was to report the clinical and surgical records of perineal hernia and associated rectal pathology with epidural morphine analgesia in 41 dogs. Fourty one dogs suffered from perineal hernia were included into the study with the age varied from 4.5 to 16 years. Eleven dogs had bilateral while the other 30 had unilateral (17 right, 13 left) perineal hernia. The clinical signs were perianal swelling (n=41), severe tenesmus (n=19), dyschesia (n=9), proctitis (n=7), fecal incontinence (n=4), stranguria (n=2) and hematuria (n=1). Associated rectal pathologies were diverticulation (n=15), dilatation (n=4), deviation (n=3) and sacculation (n=1). The rectal diverticulum was corrected by extraluminal plication (n=12) or rectal resection (n=3). Internal obturator muscle flap transposition was used to repair the hernia in all cases. Postoperative pain was subjectively evaluated and scores were "no pain" in 10 cases, mild in 28 cases, moderate in 3 cases. Mean follow-up time was 27.3 months (range 4 months to 5 years) and the recurrence was observed only in three cases postoperatively. In conclusion, combined perineal herniorraphy with internal obturator muscle transposition and rectal wall repairment can be carried out at the same time and epidural morphine administration provide adequate analgesia for these operations.

**Keywords:** *Perineal hernia, Rectal pathology, Pain, Dog*

## Köpeklerde Perineal Herninin Klinik ve Cerrahi Değerlendirilmesi: 41 Olgu

### Özet

Bu çalışmanın amacı 41 köpekte perineal herni ve eşlik eden rektal patolojilerin klinik ve operatif bulgularını postoperatif ağrı skorları ile birlikte sunmaktır. Perineal herni tanısı konulan, yaşları 4.5 ile 16 arasında değişen 41 köpek çalışma kapsamına alındı. 11 köpekte bilateral, 30 köpekte unilateral (17 sağ, 13 sol) perineal herni tespit edildi. Klinik semptomlar perineal şişkinlik (n=41), şiddetli tenesmus (n=19), ağrılı defekasyon (n=9), proktitis (n=7), fekal inkontinens (n=4), stranguri(n=2) ve hematuri (n=1) idi. Bunlara eşlik eden rektal patolojiler divertikülasyon (n=15), dilatasyon (n=4), deviasyon (n=3) ve sakkulasyon (n=1) idi. Rektal divertikülasyon ekstraluminal plikasyon (n=12) veya rektal rezeksiyon (n=3) ile düzeltildi. Perineal herninin onarımında tüm olgularda internal obturator kas flebi kullanıldı. Postoperatif ağrı subjektif olarak değerlendirildi. Buna göre 10 olguda ağrının olmadığı, 28 olguda hafif ve 3 olguda orta düzeyde ağrı olduğu kaydedildi. Ortalama 27.3 aylık (4 ay-5 yıl) takip süresinde 3 olguda nüks tespit edildi. Sonuç olarak, internal obturator kas flebi ile perineal herninin onarılabileceği, aynı operasyonda rektal duvar patolojilerinin düzeltilebileceği ve bu operasyonlarda epidural morfin uygulamasının yeterli düzeyde analjezi sağladığı kaydedildi.

**Anahtar sözcükler:** *Perineal herni, Rektal patoloji, Ağrı, Köpek*


### INTRODUCTION

Perineal hernia is characterized by disruption of the pelvic diaphragm and herniation of the abdominal or pelvic organs into the ischiorectal fossa especially in

middle-aged or aged intact male dogs <sup>1-7</sup>. Approximately 59% of the perineal hernias are unilateral while 41% are bilateral <sup>6</sup>.

 **İletişim (Correspondence)**

 +90 533 6338209

 vetzeynep@yahoo.com

Perineal hernia may be associated with sacculation, dilatation, deviation and diverticulation of rectum, retroflexion of urinary bladder or uretral obstruction<sup>8-10</sup>. The recurrence of the hernia, tenesmus and rectal prolapse are not rare with standard herniorrhaphy<sup>5,9,11,12</sup>. Internal obturator flap technique has been used frequently and the recurrence rate declined to 2-10%<sup>10</sup>. Castration is recommended due to the effects of testosterone<sup>4,13,14</sup>, or relaxin<sup>14</sup> on the prostate gland and perianal musculature. Large rectal sacculation and rectal diverticulum may cause straining to expel feces and may lead to disruption of the perineal hernia repair. Therefore, surgical correction of rectal diverticulum or large sacculation should be carried out to prevent recurrence of perineal hernia<sup>10,15</sup>. Colopexy, cystopexy or vas deferens pexy are also suggested for prevention of recurrence of rectal herniation<sup>6,9,13</sup>. Adequate analgesia protocol is also needed for prevention of straining and concomitant recurrence.

The purpose of this retrospective study was to report details of perineal hernia and associated rectal pathology accompanied by epidural analgesia in 41 dogs.

## MATERIAL and METHODS

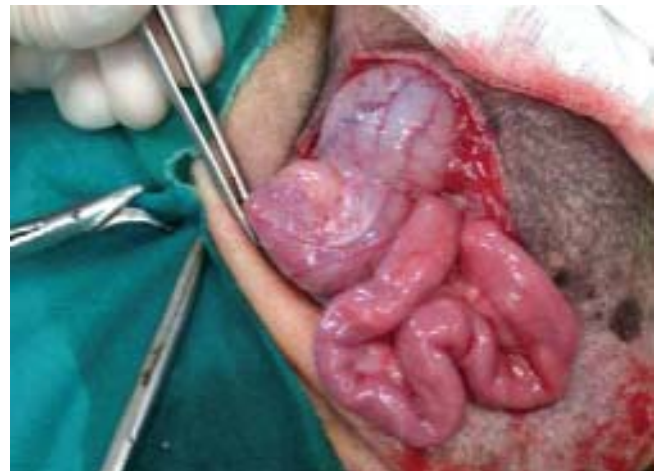Fourty one male dogs submitted to the Department of Surgery, Faculty of Veterinary Medicine at Ankara University between February 2004 and December 2008 with clinical signs related to perineal hernia such as perianal swelling, tenesmus, proctitis and dyschesia were included in the study. The breed distribution of the dogs were Poodle (n=18), Pekingese (n=9), Collie (n=5), Mongrel (n=3), German Shephard (n=2), Cocker (n=1), Spitz (n=1), Rottweiler (n=1) and Daschund (n=1). Perineal hernia was diagnosed for the dogs. History, physical, and if needed radiologic and/or ultrasonographic examination findings were recorded.

Rectal examination was performed to assess the rectal wall support and rectal lesions. When the differentiation was not easily performed by digital examination, barium was applied via rectum. The detected disorders were described as deviation (change in rectal position from the midline), dilatation (symmetric enlargement of the rectal diameter without tearing the muscular wall), sacculation (asymmetric enlargement of the rectal diameter without tearing the muscular wall) and diverticulation (disruption of the muscular layer of the rectum and protrusion of the rectal mucosa through the muscular layer of the rectal wall)<sup>9</sup>.

Anesthesia for operation - The dogs were with-draweled for food since 24 h before surgery. The caudal part of the rectum was evacuated digitally. Cephalosporin were administered (20 mg/kg IV, Sefazol, Mustafa

Nevzat, Turkey) before premedication to prevent infection. Dogs were premedicated with diazepam (0.4 mg/kg IV, Diazem, Deva, Turkey) and then general anesthesia were induced with propofol (4-6 mg/kg IV, Diprivan, AstraZeneca, UK), and maintained with isoflurane (Forane, Abbott, UK) in oxygen. Lumbosacral epidural analgesia was carried out using 0.1 mg/kg morphine (Morphine HCl, Galen Ilac, Turkey) diluted in 2 ml/10 kg saline solution and the operation table was tilted 20-25 degrees thigh-down position to produce analgesic effect around the perineal region.

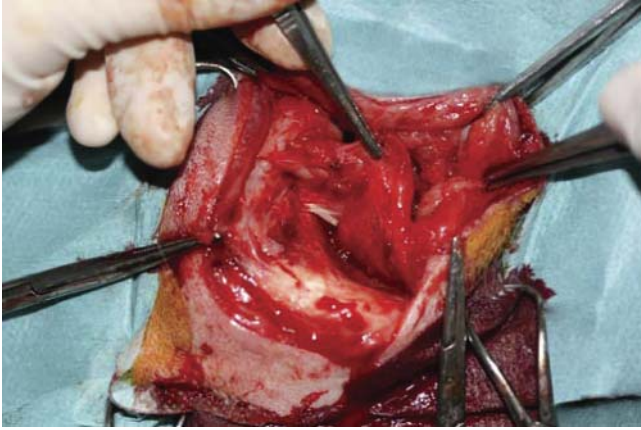
The dogs were placed upon the operation table in sternal recumbency with the rear legs over the end of the table. The operation table was tilted 10 to 15 degrees head-down position. The tail was positioned over the back. Anal sacs of the dogs was evacuated and purse string suture placement around the anus was placed. A curvilinear skin incision was made 1 to 2 cm lateral to the anus, beginning at the base of the tail and extending 1 to 2 cm ventral to the ischium. The hernial sac contents were replaced into the abdomen through the pelvic inlet (*Fig. 1*). In rectal diverticulum determined cases, assistant surgeon inserted his index finger through the rectum and deviated the dilated part through the operation side to see the ruptured muscular layer. The surgeon reduced the size of the rectal diverticulum by placing a few interrupted Lembert sutures (2-0 or 3-0 PDS) to the seromuscular layer parallel to rectal direction. Sutures were begun at the beginning of the rectal diverticulum and continued until the diameter of the diverticulated part were same as the cranial part. Sutures were placed carefully not to penetrate the mucosal layer. After the rectum was restored, the internal obturator muscle was subperiostally elevated (*Fig. 2*). It was sutured medially to the external anal sphincter and laterally to the



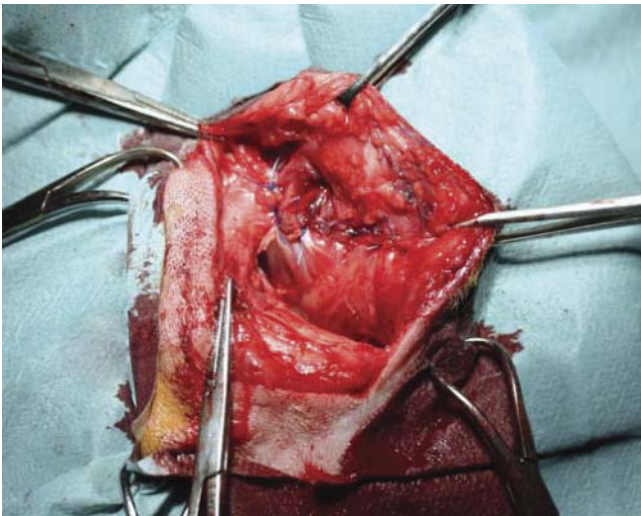
**Fig 1.** Appearance of the herniated organs (urinary bladder and intestines)

**Şekil 1.** Fıtıklı organların görünüşü (idrar kesesi ve bağırsaklar)

sacroterous ligament, the coccygeus muscle and the levator ani muscle using 2-0 or 3-0 polypropylene sutures (Fig. 3). In bilateral herniated dogs, both herniorraphy operation were performed during the same operation. All dogs were castrated by the postscrotal approach after herniorraphy without changing the position of dogs.



**Fig 2.** Elevation of the internal obturator muscle subperiostally  
**Şekil 2.** Internal obturator kasının subperiostal kaldırılması



**Fig 3.** The appearance of the internal obturator muscle flap after herniorraphy  
**Şekil 3.** Herniorafiden sonra internal obturator kas flebinin görünüşü

Postoperative pain was subjectively evaluated based on behavioral signs<sup>3,9</sup>: Response to stimulation, body posture, appetite, exercise, willingness to sit and walk, gait and defecation pattern. Scoring was based on a 0 to 3 scale; 0: no pain, 1: mild pain, 2: moderate pain and 3: severe pain. After 24 h, carprofen (2 mg/kg orally, SID, Rimadyl, Pfizer, USA) was administered for 2-5 days.

Stool softeners were administered for 2-4 weeks after surgery to prevent straining. Amoxicillin klavulanik acid (20 mg/kg BID, oral) (Amoklavin, Deva, Turkey)

were administered for a week and local wound care was also recommended.

The mean follow-up time was 27.3 months (ranging 4-60 months) with clinical examination and telephone conversation.

In three bilateral herniated dogs, the diverticulum and dilatation were so extensive that rectal resection was planned. After dilated part of the rectum was resected by approaching reverse U-shaped incision, end-to-end anastomosis was made and bilateral herniorraphy operation was performed as mentioned before.

## RESULTS

The age of the dogs at presentation was 4.5 to 16 years (mean 10.2 years). The average duration of clinical signs recorded was 11.3 months (20 days - 3 years). Eleven dogs had bilateral and 30 had unilateral (17 right, 13 left) perineal hernia. The reasons for referral were perianal swelling (n=41), severe tenesmus (n=19), proctitis (n=7), dyschesia (n=9), fecal incontinence (n=4), stranguria (n=2) and hematuria (n=1). Perineal hernia was associated with rectal diverticulum (n=15), dilatation (n=4), deviation (n=3) and sacculation (n=1). Prostatic hyperplasia (n=6) and testicular tumour (n=1) was treated by castration, perianal adenoma (n=1) was treated by excision of the tumour, and inguinal hernia was treated by inguinal herniorraphy. In addition to perineal hernia, sac contents included retroperitoneal fat (n=34), intestine (n=10), prostate (n=8), urinary bladder (n=6) and omentum (n=3).

Dyschesia, severe tenesmus, fecal incontinence, intermittent rectal prolapse and severe proctitis were recorded in three cases before surgery. These symptoms had continued for two months in the first case, six months in the second case and eighteen months in the third case prior to surgery. The owners often described the need for local massages of the bulge while defecation furthermore, they took the dogs to local veterinarian for enema at few instances because of severe pain during defecation. These three dogs had paresis of the external anal sphincter before the surgery. Rectal resection was carried out in these three dogs because of severe inflammation and malformation in the rectal tissue. Intermittent tenesmus was also recorded for two days after the operation for these dogs. The pain score was two in the first two cases; and one in the third case for the first 24 h. Fecal incontinence continued for two months in the third case, three months in the first case and did not resolve in the second case. However, tenesmus was resolved and perineal hernia did not recur in all three dogs.



Analgesia scores were 0 in ten cases, 1 in twenty eight cases and 2 in three cases for the first 24 h, and the mean pain score was 0.8. No complications occurred associated with the epidural opioid medication.

At the surgery of one dog, a large prostatic enlargement was observed within the herniated content, which was difficult to be replaced into the abdomen and no pathology was observed in the rectum. Although, there was no straining observed postoperatively, the dog developed a permanent straining 10 h after the operation. Three days after surgery, this dog developed a right perineal seroma. The seroma was aspirated and two sutures were removed for the fluid drainage. The tenesmus continued for 6 days and its severity gradually decreased by the course of time.

One dog with a history of recurrent perineal hernia for 2 years, was presented for fecal incontinence. The first operation had been carried out with the standard herniorrhaphy operation. The severity of proctitis and dyschesia increased during two years period and finally the owner admitted the dog to our clinic. In clinical examination, left perineal hernia, severe proctitis, diverticulation, paresis of the external anal sphincter and depressed perianal reflex were recorded. The plication and herniorrhaphy were carried out as mentioned previously. Although there was no complication associated with the plication and herniorrhaphy, the owner wanted the dog to be euthanized due to the fecal incontinence.

Twelve dogs with rectal diverticulum treated with plication had no complications associated with both infection and narrowing of the diverticulated rectum.

The perineal hernia recurred in three cases. One of which had bilateral hernia with rectal dilatation, the other had unilateral hernia with rectal diverticulation and the third case had unilateral hernia without concurrent pathology.

## DISCUSSION

In the present study, we surgically treated the dogs with perineal hernia that was associated with rectal diverticulum (n=15), dilatation (n=4), deviation (n=3) and sacculation (n=1), prostatic enlargement (n=5), testicular tumor (n=1), perianal adenoma (n=1) and inguinal hernia (n=1). To our experience, surgical outcomes of the internal obturator muscle transposition and rectal plication technique (in cases associated with diverticulum) seemed to be favorable.

There are several treatment methods used for the repair of perineal hernia including the standard

herniorrhaphy<sup>1,16,17</sup>, transposition of the internal obturator muscle<sup>9,11,18</sup>, semitendinosus muscle<sup>19</sup> or superficial gluteal muscle, porcine dermal collagen usage<sup>20</sup>, porcine small intestinal submucosa<sup>3</sup>, autogenous fascia lata graft<sup>7</sup>, polypropylene mesh<sup>10</sup> and plastic mesh<sup>21</sup>. Recurrence rates varied among these studies. Combined techniques have also been proposed such as colopexy, cystopexy or vas deferens pexy and "2-step protocol" was developed, in which laparotomy was performed as the initial stage of repair in bilateral or complicated perineal hernia and followed by perineal herniorrhaphy<sup>5,6,8,9,13</sup>.

Brissot et al.<sup>9</sup> recommended to wait 2-15 days interval periods for the perineal herniorrhaphy after colopexy operation to prevent loss of colopexy benefits, but reported that it was only possible in 16 cases among 41 cases. Since the perineal hernia occurred in dogs older than 7 years<sup>5,6,10</sup>, as also observed in this study, it does not always seem feasible to perform two consecutive operations. Instead of two different operations, combined rectal plication and herniorrhaphy can be performed at the same time. To our experience, this procedure does not prolong the operation time significantly. The results of this study regarding to the resolution of clinical signs and recurrence are compatible with other reports<sup>9,10</sup>. The recurrence was seen in three cases among 41 dogs in this study. We suppose that, if the internal obturator muscle is elevated subperiostally in a proper manner and rectal pathology is corrected, this muscle provides a good closure for the repairment of the perineal hernia.

If bilateral hernia repair is considered, the hernias can be repaired at the same time; however, some surgeons prefer waiting for 4-6 weeks between repairs to decrease the stress and distortion of the external anal sphincter muscle<sup>10,15</sup>. Rectal prolapse can also occur after repair of perineal hernias because of tenesmus, especially in dogs with bilateral hernia, complicated by rectal sacculation<sup>5,12</sup>. Bongartz et al.<sup>7</sup> reported 2 rectal prolapse in 12 dogs; they thought that simultaneous bilateral procedures might induce more pain, and stricture of the pelvic diaphragm lead to an increased effort during defecation. In the present study, both unilateral and bilateral perineal hernia were treated at the same operation, there were no severe pain inducing persistent tenesmus, and no prolapse recorded associated with pain. We thought that the epidural morphine injection not only provided perioperative analgesia but was also a method of controlling tenesmus and consequent rectal prolapse after surgery.

Pain can cause straining that usually subsides in a few days with resolution of postoperative pain. However,

postoperative continual straining for a long time before healing can lead to recurrence of herniation<sup>10,13</sup>. Prevention or relief of straining could have a role in preventing and retarding the progression of development of perineal hernia<sup>2,11</sup>. That is why postoperative analgesia is important. In these case series, no complications were recorded associated with epidural morphine, and the analgesia scores were 0 in ten cases, 1 in twenty eight cases and 2 in three cases.

Perineal wound infection was the most common complication, ranging from 5% to 45%. Sjollema and Sluijs<sup>11</sup> reported that the wound infection was the most frequent complication (45%), but they did not use antibiotics until the infection was noticed. Misplaced sutures into the rectal mucosa can lead to excessive straining and development of rectocutaneous fistula<sup>6,15</sup>. Popovitch et al.<sup>12</sup> and Brissot et al.<sup>9</sup> reported localized infection around the colopexy side 7.14% and 9.76%, respectively. Although some authors<sup>10,21</sup> resolved the rectal disease by plication, they recorded suture sinuses and seroma after the operation. In the present study careful placement of sutures was carried out by the guide of an assistant which everted the rectum by his finger during the correction of diverticulum, and antibiotics were used subsequently for a week to prevent infection. It was thought that careful manipulations and an appropriate antibiotic therapy were efficacious to prevent perineal wound infection and complication associated with the rectal wall repairment as some authors mentioned<sup>17,22</sup>.

Repeated compression and stretching of the pudental nerve during straining may result in irreversible damage to the nerve and deterioration of sphincter function<sup>2,4,11</sup>. In three rectal resection performed cases fecal incontinence continued for two months in one case, three months in the second case and did not resolve in the third case. We thought that fecal incontinence was due to the preoperative pudental nerve damage as the others reported previously<sup>2,4,11</sup>. Consistent fecal incontinence in one case, which was operated previously in an other clinic, is probably due to the pudental nerve damage occurred during the first operation as the owner stated that these symptoms had been continued for two years. That's why dilated anus developed and did not resolve in two months after the operation.

On the basis of the results reported here, combined perineal herniorrhaphy with internal obturator muscle transposition and rectal wall repairment by plication or resection can be carried out simultaneously and epidural morphine administration provides adequate analgesia for these operations.

## REFERENCES

- Dieterich HF:** Perineal hernia repair in the canine. *Vet Clin North Am: Small Anim Pract*, 5, 383-399, 1975.
- Sjollema BE, Haagen AJV, Sluijs FJ, Hartman F, Goedegebuure SA:** Electromyography of the pelvic diaphragm and anal sphincter in dogs with perineal hernia. *AJVR*, 54, 185-190, 1993.
- Stoll MR, Cook JL, Pope ER, Carson WL, Kreeger JM:** The use of porcine small intestinal submucosa as a biomaterial for perineal herniorrhaphy in the dog. *Vet Surg*, 31, 379-390, 2002.
- Head LL, Francis DA:** Mineralized paraprostatic cyst as a potential contributing factor in the development of perineal hernias in a dog. *JAVMA*, 221, 533-535, 2002.
- Gilley RS, Caywood DD, Lulich JP, Bowersox TS:** Treatment with a combined cystopexy-colopexy for dysuria and rectal prolapse after bilateral perineal herniorrhaphy in a dog. *JAVMA*, 222, 1717-1721, 2003.
- Bellenger CR, Canfield RB:** Perineal hernia. In, Slatter D (Ed): *Textbook of Small Animal Surgery*. 3rd ed., pp. 487-498, Saunders Philadelphia, 2003.
- Bongartz A, Carofiglio F, Balligand M, Heimann M, Hamaide A:** Use of autogenous fascia lata graft for perineal herniorrhaphy in dogs. *Vet Surg*, 34, 405-413, 2005.
- Niles JD, Williams JM:** Perineal hernia with bladder retroflexion in a female cocker spaniel. *JSAP*, 40, 92-94, 1999.
- Brissot HN, Dupre GP, Bouvy BM:** Use of laparotomy in a staged approach for resolution of bilateral or complicated perineal hernia in 41 dogs. *Vet Surg*, 33, 412-421, 2004.
- Vnuck D, Maticic D, Kreszinger M, Radisic B, Kos J, Lipar M, Babic T:** A modified salvage technique in surgical repair of perineal hernia in dogs using polypropylene mesh. *Vet Med-Czech*, 51, 111-117, 2006.
- Sjollema BE, Sluijs FJ:** Perineal hernia repair in the dog by transposition of the internal obturator muscle. II. Complications and results in 100 patients. *Vet Q*, 11, 18-23, 1989.
- Popovitch CA, Holt D, Bright R:** Colopexy as a treatment for rectal prolapse in dogs and cats: A retrospective study of 14 cases. *Vet Res*, 23, 115-118, 1994.
- Bilbrey SA, Smeak DD, DeHoff W:** Fixation of the deferent ducts for the urinary bladder and prostate in canine perineal hernia. *Vet Surg*, 19, 24-27, 1990.
- Niebauer GW, Shibly S, Seltenhammer M, Pirker A, Brandt S:** Relaxin of prostatic origin might be linked to perineal hernia formation in dogs. *Annals New York Acad Sci*, 1041, 415-422, 2005.
- Anderson MA, Constantinescu GM, Mann FA:** Perineal hernia repair in the dog. In, Bojrab MJ (Ed): *Current Techniques in Small Animal Surgery*. 4th ed. pp. 555-564, Williams & Wilkins Baltimore, 1998.
- Özak A, Beşaltı Ö, Gökçe P, Can Z:** Köpeklerde perineal herni'nin tanı ve sağaltımı (1999-2001). *JTVS*, 7 (3-4): 31-34, 2001.
- Alkan Z, Bumin A, Öztürk S:** Perineal hernili 3 köpekte divertikulum rekti olgusunun klinik, radyografik tanısı ve şırıjikal sağaltımı. *JTVS*, 7 (3-4): 51-54, 2001.

**18. Sluijs FJ, Sjollem BE:** Perineal hernia repair in the dog by transposition of the internal obturator muscle. I. Surgical technique. *Vet Q*, 11, 12-17, 1989.

**19. Chambers JN, Rawlings CA:** Applications of a semitendinosus muscle flap in two dogs. *JAVMA*, 199, 84-86, 1991.

**20. Frankland AL:** Use of porcine dermal collagen in the repair

of perineal hernia in dogs- a preliminary report. *Vet Rec*, 119, 13-14, 1986.

**21. Larsen JS:** Perineal herniorrhaphy in dogs. *JAVMA*, 149, 277-280, 1966.

**22. Okumuş Z, Atalan G, Erdoğan HM, Güneş V:** Bir köpekte divertikulum rekti olgusu. *Kafkas Üniv Vet Fak Derg*, 4 (1): 103-108, 1998.