

See discussions, stats, and author profiles for this publication at: <https://www.researchgate.net/publication/285684125>

# Retrobulbar Neuritis as the Initial Sign of Interferon-Alpha-Associated Multiple Sclerosis in a Chronic Hepatitis B Patient: Case Report

Article in *Türkiye Klinikleri Journal of Medical Sciences* - January 2011

DOI: 10.5336/medsci.2009-13361

CITATION

1

READS

32

4 authors, including:



**Kemal Örnek**

Ahi Evran Üniversitesi

108 PUBLICATIONS 643 CITATIONS

[SEE PROFILE](#)



**Zafer Onaran**

Kirikkale University

57 PUBLICATIONS 200 CITATIONS

[SEE PROFILE](#)

Some of the authors of this publication are also working on these related projects:



Hydroimplantation in pseudoexfoliation [View project](#)

# Retrobulbar Neuritis as the Initial Sign of Interferon-Alpha-Associated Multiple Sclerosis in a Chronic Hepatitis B Patient: Case Report

## Kronik Hepatit B Hastasında İnterferon Alfa Tedavisine Bağlı Multipl Sklerozun İlk Belirtisi Olarak Retrobulber Nörit

Kemal ÖRNEK, MD,<sup>a</sup>  
Zafer ONARAN, MD,<sup>a</sup>  
Pelin YILMAZBAŞ, MD,<sup>a</sup>  
Sefa GÜLİTER, MD<sup>b</sup>

Departments of <sup>a</sup>Ophthalmology,  
<sup>b</sup>Internal Medicine,  
Kırıkkale University Faculty of Medicine,  
Kırıkkale

Geliş Tarihi/Received: 07.05.2009  
Kabul Tarihi/Accepted: 28.10.2009

Yazışma Adresi/Correspondence:  
Zafer ONARAN, MD  
Kırıkkale University Faculty of Medicine,  
Department of Ophthalmology,  
Kırıkkale,  
TÜRKİYE/TURKEY  
drzaferonaran@yahoo.com

**ABSTRACT** Interferon-alpha (IFN- $\alpha$ ) is a therapeutic agent which plays an important role in the management of viral and malignant disorders. However, it has several side effects on eye and visual pathway. A 43-year-old man was admitted with sudden loss of vision. He had been on IFN- $\alpha$  treatment for chronic hepatitis B which was stopped 9 months earlier. The diagnosis of retrobulbar optic neuritis was made. Six months later, he admitted to us with decreased vision in the same eye. Magnetic resonance imaging of the brain revealed white matter lesions. Further neurological investigations confirmed the diagnosis of multiple sclerosis. Multiple sclerosis should be considered in differential diagnosis of hepatitis B patients with a history of IFN- $\alpha$  treatment who present with visual symptoms.

**Key Words:** Hepatitis B, chronic; interferon-alpha; multiple sclerosis; optic neuritis

**ÖZET** İnterferon- alfa (IFN- $\alpha$ ), viral ve malign hastalıkların tedavisinde önemli rol oynayan bir ajandır. Ancak göz ve görme yollarını etkileyen yan etkileri de bulunmaktadır. Kırk üç yaşında erkek hasta, tek taraflı görme kaybı şikayetiyle başvurdu. Hikayesinde kronik hepatit B tedavisi için uygulanan ve dokuz ay öncesinde kesilmiş IFN- $\alpha$  tedavisi mevcut idi. Hastaya retrobulber optik nörit tanısı kondu. Altı ay sonra aynı gözde görme kaybı ile tekrar başvuran hastanın beyin manyetik rezonans görüntülemesinde beyaz madde lezyonları tespit edildi. İleri nörolojik değerlendirmede multipl skleroz tanısı doğrulandı. IFN-  $\alpha$  tedavisi alan hepatit B hastalarında ortaya çıkan görme şikayetlerinde multipl skleroz da ayırıcı tanıda düşünülmelidir.

**Anahtar Kelimeler:** Hepatit B, kronik; interferon-alfa; multipl skleroz; optik nörit

Türkiye Klinikleri J Med Sci 2011;31(3):716-9

Interferon-alpha (IFN- $\alpha$ ) is a natural glycoprotein produced by immune cells in response to viral infections, and it is widely used to treat chronic viral hepatitis.<sup>1</sup> Multiple sclerosis (MS) is an autoimmune disorder characterized by demyelination in the central nervous system (CNS). Diagnosis of the disease is made according to the revised McDonald diagnostic criteria for MS based on clinical, magnetic resonance imaging (MRI) and laboratory findings.<sup>2</sup> Although the cause of demyelination remains unknown, occasionally a therapeutic agent may promote an autoimmune process that attacks myelin. IFN- $\alpha$  associated MS has been reported in two chronic leukemia patients (CML) and one chronic hepatitis C patient.<sup>3,4</sup> Optic neuritis is one of the presenting features of MS in about 20% of pati-

ents.<sup>5</sup> Here we present the first report of a retrobulbar optic neuritis in a chronic hepatitis B patient, possibly associated with IFN- $\alpha$ -induced MS.

## CASE REPORT

A 43-year-old man admitted to our clinic with a sudden loss of vision in the right eye. He had been on IFN- $\alpha$  treatment for chronic hepatitis B which was interrupted 9 months earlier due to systemic side effects. He had been administered 9 million units subcutaneous IFN- $\alpha$  three day a week for one year. He had no history of ocular or any other systemic disease. Best corrected visual acuity in the right eye was counting fingers from one meter and it was 10/10 in the left eye. There was no afferent pupillary defect. Fundus examination revealed bilateral normal optic discs (Figure 1). Both pattern and flash visual evoked potential (VEP) recordings were performed. Pattern VEP waveform in the right eye was distorted and flash VEP was delayed with lower amplitude with respect to the left eye (Figure 2). There were no pathological findings in neurological and serological tests. MRI of the brain and orbits was normal. Seven days later, his visual acuity was measured as 5/10. However, color vision tested with Ishihara plates was significantly reduced. One month after, his visual acuity was found to be 8/10 and color vision 13/24 without any treatment. Six months later, the patient was admitted to hospital suffering from decreased vision (1/10) in the same eye. Fundus examination was normal but brain MRI demonstrated several white

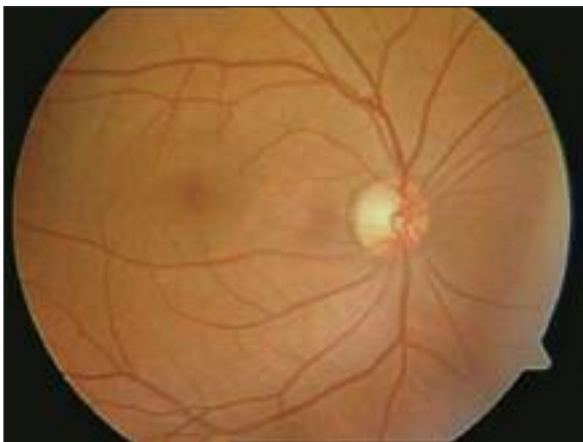

FIGURE 1: Fundus of right eye showing a normal optic disc

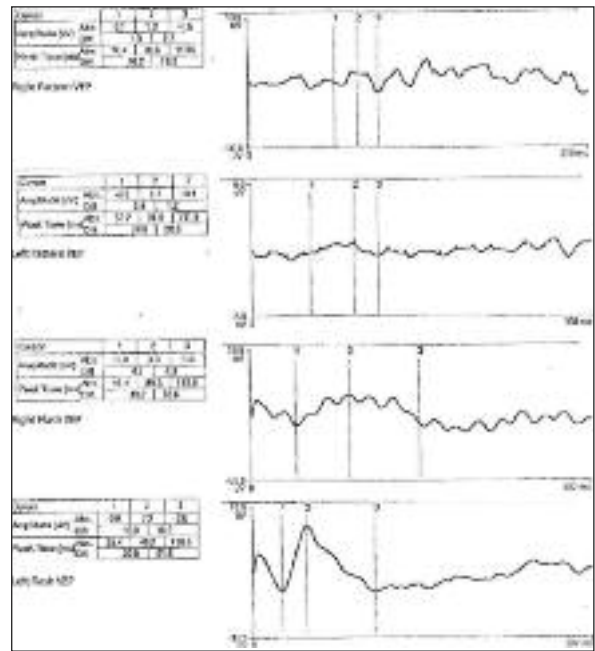


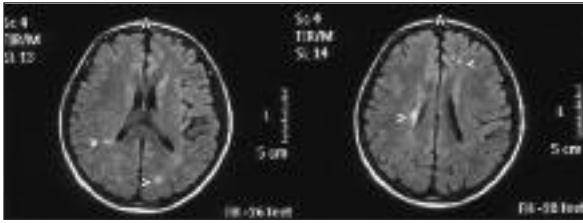
FIGURE 2: Visual evoked potentials (pattern and flash) obtained from both eyes and were impaired in the right side.

matter lesions (Figure 3). There were also pathologic signal enhancements which were hyperintense in T2-weighted MRI of the spinal cord (Figure 4).

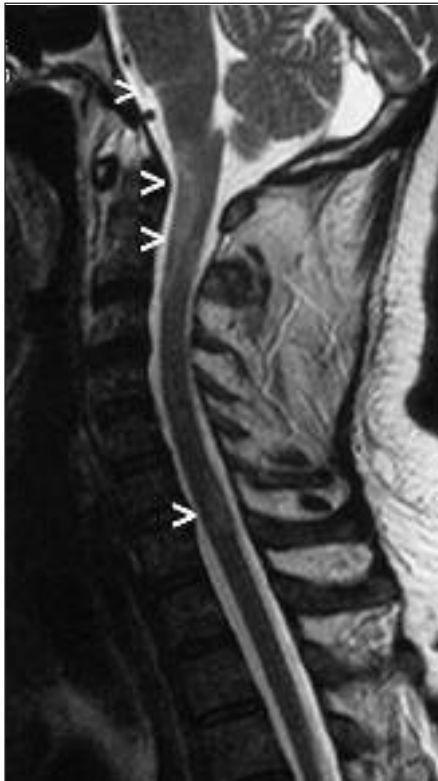Neurological examination revealed a positive Romberg test and ataxia. Lumbar puncture was performed and examination of cerebrospinal fluid showed oligoclonal bands and elevated IgG index (1.45). These clinical, laboratory and radiological findings met the revised McDonald criteria and MS diagnosis was made. High-dose (1g/day) intravenous methylprednisolone was given for three days. As the patient had viral hepatitis as well oral steroid tapering was not performed due to risk of prolonged exposure. Significant improvement was achieved in the visual acuity (6/10) following treatment. The patient was treated with intravenous methylprednisolone by neurologists for two times in the following year because of acute exacerbation of MS.

## DISCUSSION

Visual disturbances in chronic hepatitis patients receiving INF- $\alpha$  therapy have been related to various pathologies including multiple sclerosis-like disease, ischemic optic neuropathy and retino-



**FIGURE 3:** Magnetic resonance imaging of the brain shows multiple periventricular and juxtacortical white matter lesions consistent with demyelination.



**FIGURE 4:** Pathologic signal enhancement in T2W spinal MRI at the level of brain stem, C1-3 and C6-7, indicating a demyelinating disease.

pathy.<sup>3,4,6,7</sup> IFN is a leukocyte-derived cytokine that is a part of the chronic hepatitis virus infection therapy. IFN has multiple effects on the immune system and is known to trigger the development of autoantibodies, as well as the onset or exacerbation

of autoimmune diseases.<sup>8</sup> MS is an organ-specific autoimmune disease targeting CNS myelin. IFN- $\alpha$  induced MS has been shown in CML and chronic hepatitis C patients which were manifested during the therapy or as long as 2 months after the cessation of IFN- $\alpha$ . Our case differs from the others in several ways. Our patient had chronic hepatitis B who initially developed retrobulbar optic neuritis and eventually progressed to CNS and spinal cord demyelination long after termination of IFN- $\alpha$  therapy. Prognosis of IFN-associated MS has not been well defined since it has been proposed that cessation of the IFN- $\alpha$  treatment could lead to remission of the disease or may result in a fulminant course.<sup>9</sup> Galli et al. reported the development of retrobulbar optic neuritis in a patient with acute hepatitis B infection, and they attempted to explain the underlying pathogenesis with immune complexes-mediated neurotoxicity hypothesis.<sup>10</sup>

Intravenous steroids are often prescribed in retrobulbar optic neuritis to improve visual outcome or to decrease the long-term risk of multiple sclerosis. However, at the time of diagnosis of optic neuritis we hesitated to treat our patient with steroids due to presence of a chronic viral hepatitis. Tough when MS was confirmed, he was treated with steroids under the close observation of the internal medicine specialists.

IFN has been used clinically to treat numerous viral and malignant diseases. There is a therapeutic dilemma in terms of the use of IFN- $\alpha$  in the management of MS as it could be both the cause of the disease and a therapeutic option. Moreover, IFN therapy may be associated with ocular complications. Our case demonstrates an indirect ophthalmic side effect of IFN- $\alpha$  since it caused MS. We believe that MS should be considered in the differential diagnosis of visual symptoms in chronic hepatitis B patients with a history of IFN- $\alpha$  treatment.

## REFERENCES

1. Güner İ, Özmen D, Bayindir O. [Cytokines]. *Türkiye Klinikleri J Med Sci* 1997;17(2): 65-74.
2. Polman CH, Reingold SC, Edan G, Filippi M, Hartung HP, Kappos L, et al. Diagnostic criteria for multiple sclerosis: 2005 revisions to the "McDonald Criteria". *Ann Neurol* 2005;58(6): 840-6.
3. Matsuo T, Takabatake R. Multiple sclerosis-like disease secondary to alpha interferon. *Ocul Immunol Inflamm* 2002;10(4):299-304.
4. Kataoka I, Shinagawa K, Shiro Y, Okamoto S, Watanabe R, Mori T, et al. Multiple sclerosis associated with interferon-alpha therapy for chronic myelogenous leukaemia. *Am J Hematol* 2002;70(2):149-53.
5. Gilbert ME, Sergott RC. New directions in optic neuritis and multiple sclerosis. *Curr Neurol Neurosci Rep* 2007;7(3):259-64.
6. Vardizer Y, Linhart Y, Loewenstein A, Garzozzi H, Mazawi N, Kesler A. Interferon-alpha-associated bilateral simultaneous ischemic optic neuropathy. *J Neuroophthalmol* 2003;23(4):256-9.
7. d'Alteroche L, Majzoub S, Lecuyer AI, Delplacé MP, Bacq Y. Ophthalmologic side effects during alpha-interferon therapy for viral hepatitis. *J Hepatol* 2006;44(1):56-61.
8. Preziati D, La Rosa L, Covini G, Marcelli R, Rescalli S, Persani L, et al. Autoimmunity and thyroid function in patients with chronic active hepatitis treated with recombinant interferon alpha-2a. *Eur J Endocrinol* 1995;132(5):587-93.
9. Höftberger R, Garzuly F, Dienes HP, Grubits J, Rohonyi B, Fischer G, et al. Fulminant central nervous system demyelination associated with interferon-alpha therapy and hepatitis C virus infection. *Mult Scler* 2007;13(9):1100-6.
10. Galli M, Morelli R, Casellato A, Perna MC. Retrobulbar optic neuritis in a patient with acute type B hepatitis. *J Neurol Sci* 1986;72(2-3):195-200.