



ELSEVIER



CrossMark

Neuroradiology / Neuroradiologie

Brain Diffusion Changes in Polycystic Ovary Syndrome

Ebru Unlu, MD^a, Alper H. Duran, MD^{a,*}, Cinar Balcik, MD^b, Mehtap Beker-Acay, MD^b, Yunus Yildiz, MD^c, Ozlem B. Tulmac, MD^d, Bekir S. Unlu, MD^e, Aylin Yucel, MD^b

^aDepartment of Radiology, MD Anderson Cancer Center, University of Texas, Houston, Texas, USA

^bDepartment of Radiology, School of Medicine, Afyon Kocatepe University, Afyonkarahisar, Turkey

^cClinic of Obstetrics and Gynecology, Ilgin State Hospital, Konya, Turkey

^dDepartment of Obstetrics and Gynecology, School of Medicine, Kirikkale University, Kirikkale, Turkey

^eDepartment of Obstetrics and Gynecology, School of Medicine, Afyon Kocatepe University, Afyonkarahisar, Turkey

Key Words: Polycystic ovary syndrome; Diffusion weighted imaging; Obesity in Polycystic ovary syndrome; Eating disorder

Polycystic ovary syndrome (PCOS) is the most frequent endocrine disorder in women of reproductive age, affecting 4%-10% of the population. It is a complex disorder classically characterized by chronic oligo- or anovulation, polycystic ovaries, and hyperandrogenism. It is also associated with a number of comorbid conditions, including type 2 diabetes, cardiovascular disease, dyslipidemia, obesity, infertility, and breast and endometrial cancer [1,2]. In addition, psychiatric disorders are observed more often in PCOS patients than in the general population, particularly depressive, anxiety, and eating disorders [3–6]. According to previous reports, approximately 57% of PCOS patients have at least 1 psychiatric disorder [4,5].

To date, the exact etiology for increased risk of mood disorders in PCOS patients remains unknown and it has been generally suggested that the clinical and physical manifestations of PCOS, such as obesity, hirsutism, acne, or infertility, were thought to be the causes of considerable emotional distress in PCOS women [3–6]. This point of view may be partially true, however, we suggest that it is necessary to investigate the role of the central nervous system to establish a clear causal relationship between PCOS and mood disorders.

It has been shown that the brain regions involved in mood regulation are the anterior cingulate cortex, the orbitofrontal cortex, and the dorsolateral prefrontal cortex [7]. Also, the thalamus has a critical role in the modulation of cognition

and emotion [8]. In addition, specific brain regions suggested to be related to hunger and satiety are the dorsomedial and dorsolateral frontal, orbitofrontal, anterior cingulate, middle temporal, visual, and insular cortexes; thalamus; amygdala; hypothalamus; hippocampal gyrus; midbrain; corpus striatum; and cerebellum [9].

Although a complete understanding of the underlying pathophysiology of PCOS is still lacking, it has been evidenced that many of the comorbidities are related to hyperandrogenism and continuous unopposed hyperestrogenism (hyperestrogenic state) in PCOS [2,10]. However, to date, the long-term effect of high levels of these hormones on brain have not been fully investigated. On the other hand, there is evidence for functional links between testosterone and the prefrontal cortex and amygdala in the regulation of social emotional behavior [11,12]. Also, a strong correlation was found between depressive symptoms and serum androgen levels [13,14].

Diffusion-weighted imaging (DWI), a well-established magnetic resonance imaging (MRI) sequence, provides important information on microstructural characteristics of tissues by detecting the microscopic movement of water molecules within the extracellular space [15]. DWI can distinguish cytotoxic edema from vasogenic edema, and thus is commonly used to diagnose early cerebral ischemia in clinical practice. DWI yields qualitative information, whereas apparent diffusion coefficient (ADC) values calculated from DWI data are quantitative measurements of the diffusion of water molecules that may be altered in pathologic conditions [16].

Given that psychiatric disorders are commonly associated with PCOS and the possible effects of high levels of androgens and unopposed estrogens on brain, we aimed to

* Address for correspondence: Alper H. Duran, MD, 1515 Holcombe Street, MD Anderson Cancer Center, Radiology Department, Houston, Texas 77030, USA.

E-mail address: alperduran@gmail.com (A. H. Duran).

address the question whether there were brain diffusion changes in women with PCOS. Also we aimed to investigate possible relationships between hormonal parameters and ADC values. To the best of our knowledge, the our study is the first that investigate brain DWI findings in PCOS patients.

Materials and Methods

Study Population

This retrospectively designed study was performed in accordance with the Helsinki Declaration, and it was approved by the local Ethical Committee before data collection. The medical records of 658 subjects diagnosed with PCOS presenting to the Department of Obstetrics and Gynecology of our hospital between January 2008 and January 2015 were systematically reviewed from our hospital database. The diagnoses of patients with PCOS were based on the Rotterdam criteria [17]. Among these, PCOS patients who had also undergone brain MRI were searched from database. From the records, 20 PCOS patients who had brain MRI were included in the present study. The serum levels of estradiol, progesterone, prolactin, luteinizing hormone, follicle-stimulating hormone, total and free testosterone of PCOS patients were recorded. Subsequently, control subjects were selected from the subjects who had undergone brain MRI. The volunteers who met all the inclusion and exclusion criteria were invited to undergo gynecologic examination and pelvic sonographic examination. Finally 35 control subjects who had normal ovulating cycles, normal sonographic appearance of the ovaries, and no signs of hyperandrogenism were included in the study. Body mass index (BMI) (kg/m^2) was calculated to assess obesity. The subjects with normal weight were included in the study because of the possible effect of obesity on brain diffusion [9]. Also, all the study population had a normal brain MRI as evaluated by a clinical neuroradiologist. Exclusion criteria for both groups were as follows: <16 or >35 years of age; BMI >30 kg/m^2 ; or causes of hormonal imbalance such as pregnancy, breastfeeding, administration of exogenous estrogens, oral contraceptives, antiandrogens, or corticosteroids.

MRI Acquisition

All subjects were scanned with a 1.5-T Philips Intera MR unit (Philips Medical Systems, Amsterdam, the Netherlands) using standard head coil. The MRI examination consisted of spin echo images including axial and sagittal T1-weighted images (repetition time [TR] = 550 ms, echo time [TE] = 15 ms), axial T2-weighted images (TR = 3550 ms, TE = 115 ms), and fluid-attenuated inversion recovery images (TR = 9000 ms, TE = 105 ms, inversion time = 2500 ms). The sequences also included the following parameters: field of view = 230×230 mm^2 , matrix size = 256×256 mm^2 , slice thickness = 5 mm, and number

of slices = 20. DWI was performed with echo-planar imaging. The parameters were the following: TR = 4000 ms, TE = 10 ms, matrix size = 128×128 mm^2 , slice thickness = 5 mm, field of view = 230×230 mm^2 , number of acquisitions = 2, slice orientation = axial plane, number of slices = 20, scan time = 28 seconds. Diffusion gradients were applied separately in 3 orthogonal directions to generate 3 sets of DWI (x, y, and z axes). Diffusion-weighted images were displayed on a workstation for postprocessing, including reconstruction of the ADC maps.

ADC Data Analysis

Circular regions of interest (ROIs) were placed in axial slices by 2 experienced neuroradiologist on predefined anatomic areas (dorsolateral and dorsomedial frontal, orbitofrontal, middle temporal, visual, and cingulate cortexes; midbrain; amygdala; cerebellum; hippocampal gyrus; hypothalamus; thalamus; corpus striatum; and insula) and ADC values were directly calculated from automatically generated ADC maps (Figure 1). The selection was based on literatures suggesting that those regions are related to depression, emotion, cognition, hunger, and satiety [7–9]. The ROIs were placed in the cerebrospinal fluid (CSF) at the midventricular level of each subject, which revealed a mean ADC of $2.96 \pm 0.39 \times 10^{-3}$ mm^2/s . We excluded all ADC pixel values that were $>2.0 \times 10^{-3}$ mm^2/s (corresponding to mean CSF ADC – 2 Standard Deviation) to avoid CSF contamination [18]. The ROIs were approximately 10 mm^2 in the midbrain, hippocampal gyrus, hypothalamus, amygdala, middle temporal cortex, insula, and thalamus; 20–30 mm^2 in the occipital, orbitofrontal, cingulate, dorsomedial, and dorsolateral cortexes; and 40 mm^2 in the corpus striatum and cerebellum. Partial volume effects emerging from CSF were also minimized by inspecting the slices below and above the region and using small ROIs in work areas. Similar ROI sizes were used for an individually selected region in all the study population. ROI analysis was blinded to the hypotheses of the study, clinical data and group assignment of the subjects. The overall Pearson correlation for interrater reliability assessed on 8 randomly selected images was 0.98 and intrarater reliability, and based on 8 scans measured twice by the same rater was 0.99. All these values were well within acceptable limits.

Statistical Analysis

Statistical analysis was performed using SPSS version 19.0 (IBM, Armonk, NY). Because the values were identified as normal distribution, an independent sample *t* test was used to evaluate differences between PCOS patients and control subjects. Pearson's correlation coefficient was used to determine relationship between variables of groups. A *P* value lower than .05 was considered statistically significant.

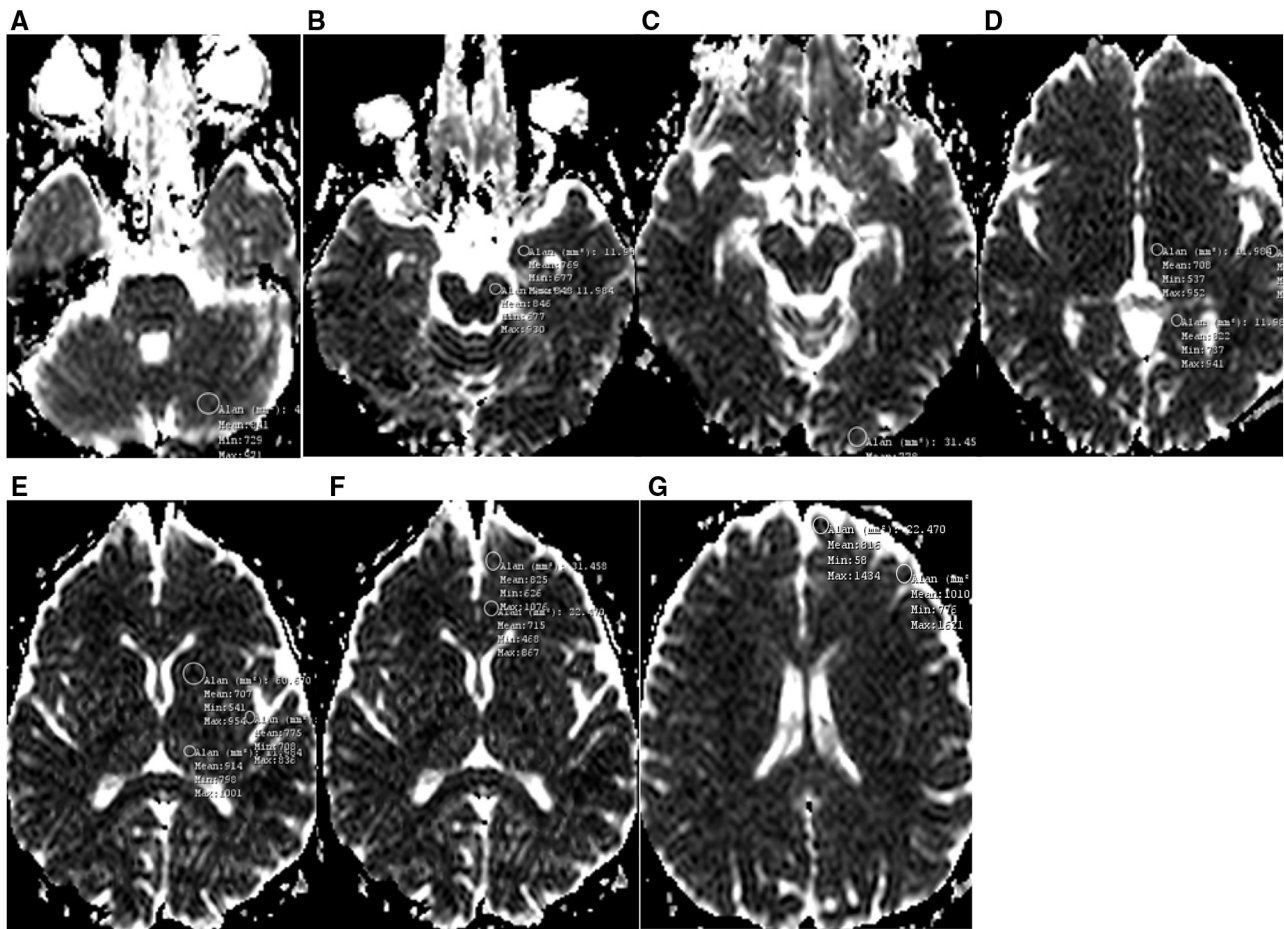


Figure 1. Positioning of regions of interest on apparent diffusion coefficient maps: (A) cerebellum; (B) midbrain, amygdala; (C) occipital cortex; (D) hypothalamus, hippocampal gyrus, and middle temporal cortex; (E) insula, corpus striatum, and thalamus; (F) orbitofrontal cortex, cingulate gyrus; and (G) dorsomedial frontal cortex and dorsolateral frontal cortex.

Results

Demographic variables and the ADC values of the study population are presented in Table 1. There were no significant differences in age or body mass index between 2 groups.

The ADC values of insula; thalamus; dorsomedial and dorsolateral frontal, cingulate, middle temporal, and visual cortices were significantly higher in the PCOS patients compared with healthy subjects ($P < .05$). In terms of ADC values in the hypothalamus, amygdala, hippocampal gyrus, orbitofrontal cortex, corpus striatum, midbrain, and cerebellum, there were no significant differences between 2 groups ($P > .05$) (Table 1).

Additionally, ADC values of the dorsomedial and dorsolateral frontal cortices were positively correlated with serum levels of estrogen ($\rho = 0.33$, $P = .04$; $\rho = 0.40$, $P = .01$, respectively) and free testosterone ($\rho = 0.38$, $P = .02$; $\rho = 0.42$, $P = .01$, respectively). There were no correlations among serum progesterone, follicle-stimulating hormone, luteinizing hormone, and prolactin levels and ADC values of other anatomic areas.

Discussion

The principal finding of the present study is the significant increase in ADC values of the dorsomedial and dorsolateral frontal cortices, anterior cingulate cortex, thalamus, insula, and middle temporal and visual cortices in women with PCOS compared with age- and BMI-matched healthy controls. We also found that ADC values of the dorsomedial and dorsolateral frontal cortices were positively correlated with estrogen and free testosterone levels. These data indicate that ADC values are significantly increased in various brain locations that are related to emotion, cognition, hunger, and satiety. All these findings were consistent with our previous hypothesis that PCOS is associated with brain diffusion alterations, namely increased extracellular space in distinct brain locations, suggesting vasogenic oedema with or without neuronal cell damage.

DWI provides microscopic information from water molecules in the tissues, giving us the ability to distinguish cytotoxic oedema from vasogenic oedema and complements conventional MRI sequences. It offers information about local microstructural changes of biological tissues that

Table 1
Demographic data and apparent diffusion coefficient values ($\times 10^{-3}$ mm²/s) of 14 brain regions of study population

	PCOS (n = 20)	Control (n = 35)	P value
Age (y)	24 ± 1.5	25 ± 2.9	.5
Body mass index	23.2 ± 1.1	24.1 ± 2.9	.3
Dorsomedial frontal cortex	79 ± 0.03	0.71 ± 0.02	.002 ^a
Dorsolateral frontal cortex	0.77 ± 0.09	0.72 ± 0.04	.009 ^a
Orbitofrontal cortex	0.72 ± 0.08	0.71 ± 0.06	.38
Corpus striatum	0.71 ± 0.09	0.72 ± 0.07	.62
Thalamus	0.74 ± 0.03	0.71 ± 0.02	.001 ^a
Midbrain	0.72 ± 0.07	0.73 ± 0.04	.60
Amygdala	0.74 ± 0.06	0.73 ± 0.03	.26
Visual cortex	0.76 ± 0.03	0.74 ± 0.04	.02 ^a
Cerebellum	0.75 ± 0.07	0.74 ± 0.04	.56
Hypothalamus	0.75 ± 0.08	0.75 ± 0.03	.99
Insular cortex	0.83 ± 0.02	0.79 ± 0.02	.008 ^a
Middle temporal cortex	0.82 ± 0.02	0.77 ± 0.03	.002 ^a
Cingulate cortex	0.81 ± 0.02	0.78 ± 0.02	.001 ^a
Hypocampal gyrus	0.73 ± 0.05	0.72 ± 0.07	.30

Values are mean ± SD. PCOS = polycystic ovary syndrome.

^a Statistically significant.

influence diffusion [15]. DWI yields qualitative information regarding random (Brownian) intra-, extra-, and transcellular motion of water molecules whereas ADC values calculated from DWI data allow quantitative measurement of the diffusion of water molecules, which may be altered in pathologic conditions in tissues [16]. ADC is elevated as a result of vasogenic oedema, which is characterized by a relative increase of water in the extracellular space where water molecules are more mobile. In other words, increased ADC values, due to increased diffusion, correspond to microstructural damage and reduction of cell volumes [15,16,19].

In the present study, ADC values of brain regions related to depression, hunger, satiety, and cognitive centres were found to be increased in patients with PCOS. These findings indicate that PCOS is associated with increased amount of interstitial water in distinct brain regions, which suggest vasogenic oedema. As is known, psychiatric disorders, including depressive, anxiety, and eating disorders are more often observed in women with PCOS than in the general population [3–6]. However, we suggest that the relationship of PCOS with mood disorders has been underestimated because to date the clinical manifestations of PCOS, such as hirsutism, obesity, acne, or infertility, were thought to be the main reason for emotional distress and reduced quality of life in PCOS patients.

It has been shown that the brain regions involved in mood regulation are the prefrontal cortex (anterior cingulate cortex, dorsolateral frontal cortex, orbitofrontal cortex), subcortical grey matter regions (caudate nucleus and thalamus), and limbic structures (amygdala and hippocampus) [20]. The prefrontal cortex plays an important role in the regulation of complex cognitive, emotional, and behavioural functioning [21]. Thus, prefrontal cortex damage typically results in deficits in judgement, orientation, concentration, and problem-solving ability [21,22].

Our analysis showed that PCOS women have significantly increased ADC values in anterior cingulate cortex and the dorsomedial and dorsolateral frontal cortices, suggesting microstructural damages in these areas. More specifically, the dorsolateral prefrontal cortex plays a key role in executive behavioral control, including the regulation of thinking and decision making. Also, the cingulate cortex is an integral part of the limbic system and is involved in emotional regulation as well as cognitive and executive function. Moreover, the dorsomedial prefrontal cortex, which shows high activation during detection of internal response conflict during choice behavior, is also considered to be a part of the limbic system and plays an important role in complex cognitive processes, including social cognition [23,24]. Taken together, it is reasonable for us to speculate that the high incidence of depressive and anxiety symptomatology in PCOS may be due to the disruption of the composition of the extracellular interneuronal space in the dorsal cortical stream, which comprises the anterior cingulate, dorsomedial, and dorsolateral prefrontal cortices.

In the present study, PCOS patients were also found to have increased ADC values in brain regions that are suggested to be related to hunger and satiety, such as the thalamus, insular cortex, visual and medial temporal cortices, and anterior cingulate cortex [9]. Also, the dorsolateral prefrontal cortex, which has increased ADC values in PCOS patients, has been shown to be associated with early satiety [9]. In particular, the visual occipital cortex is of significant importance in patients with eating disorders (anorexia nervosa, bulimia nervosa) [25,26]. In the light of these results, we also suggest that various eating disorders in PCOS patients may be explained as the result microstructural damage in these brain regions.

Another result of the present study that should be highlighted is the significant positive correlation between ADC values of the dorsomedial and dorsolateral prefrontal cortices and estrogen and free testosterone levels. As is known, estrogens have multiple important roles in the normal brain both during the intrauterine period and across the life span [10]. Also, estradiol plays important roles in regulating body fluid balance. For instance, estrogens lead to plasma volume expansion through effects on capillary fluid dynamics, altering body water distribution within the extra capillary fluid space [27]. However, despite numerous studies showing neuroprotective and neurotrophic effects of estrogen [28,29], the long-term effects of unopposed estrogen (as in PCOS) on brain morphology are still not known. Also, recent studies have shown the influences of testosterone on neural activity of prefrontal cortex and contributed to understanding the cerebral alterations in subjects with antisocial disorders, who generally show high levels of testosterone [30]. These findings could reflect a possible association between microstructural changes in the prefrontal cortex and long-standing unopposed hyper-estrogenic state and high testosterone levels in women with PCOS.

There are several limitations to this study. First, we were not able to perform functional MRI or diffusion tensor imaging because of technical issues, so, only ADC measurements were taken for neuroradiological evaluation. A second limitation of our study is the lack of the assessment of study population for psychiatric disorders because of the study's retrospective nature. Further prospective studies with larger numbers of subjects and advanced MRI techniques are needed to confirm our findings.

Conclusions

In conclusion, we investigated brain diffusion changes in various brain regions in PCOS subjects and searched for possible relationships with hormonal parameters. We found widespread altered integrity in the brain regions related to depression, hunger, satiety, emotion, cognition, and vision in patients with PCOS, as shown by increased ADC values. We suggest that these subtle changes in brain tissue composition may explain some of the psychiatric disorders associated with this disease. Also, we found a positive correlation of estrogen and free testosterone levels with prefrontal cortex, suggesting that hormonal disturbances in PCOS may lead to this altered integrity. Taken together, the results of this study should be interpreted as promising findings and future studies should further explore and develop these findings for potential clinical relevance both in the diagnosis and treatment of mood disorders in PCOS.

References

- [1] Unlu E, Unlu BS, Turamanlar O, et al. Alterations in pituitary gland volume in polycystic ovary syndrome: a structural magnetic resonance imaging study. *Clin Imaging* 2015;39:449–53.
- [2] Norman RJ, Dewailly D, Legro RS, Hickey TE. Polycystic ovary syndrome. *Lancet* 2007;370:685–97.
- [3] Dokras A. Mood and anxiety disorders in women with PCOS. *Steroids* 2012;77:338–41.
- [4] Rassi A, Veras AB, dos Reis M, et al. Prevalence of psychiatric disorders in patients with polycystic ovary syndrome. *Compr Psychiatry* 2010;51:599–602.
- [5] Hollinrake E, Abreu A, Maifeld M, Van Voorhis BJ, Dokras A. Increased risk of depressive disorders in women with polycystic ovary syndrome. *Fertil Steril* 2007;87:1369–76.
- [6] Acmaz G, Albayrak E, Acmaz B, et al. Level of anxiety, depression, self-esteem, social anxiety, and quality of life among the women with polycystic ovary syndrome. *Sci World J* 2013:851815.
- [7] Bae JN, MacFall JR, Krishnan KR, et al. Dorsolateral prefrontal cortex and anterior cingulate cortex white matter alterations in late-life depression. *Biol Psychiatry* 2006;60:1356–63.
- [8] Agarwal N, Rambaldelli G, Perlini C, et al. Microstructural thalamic changes in schizophrenia: a combined anatomic and diffusion weighted magnetic resonance imaging study. *J Psychiatry Neurosci* 2008;33:440–8.
- [9] Alkan A, Sahin I, Keskin L, et al. Diffusion-weighted imaging features of brain in obesity. *Magn Reson Imaging* 2008;26:446–50.
- [10] Matalliotakis I, Kourtis A, Koukoura O, Panidis D. Polycystic ovary syndrome: etiology and pathogenesis. *Arch Gynecol Obstet* 2006;274:187–97.
- [11] Volman I, Toni I, Verhagen L, Roelofs K. Endogenous testosterone modulates prefrontal-amygdala connectivity during social emotional behavior. *Cereb Cortex* 2011;21:2282–90.
- [12] Van Wingen G, Mattern C, Verkes RJ, Buitelaar J, Fernández G. Testosterone reduces amygdala-orbitofrontal cortex coupling. *Psychoneuroendocrinology* 2010;35:105–13.
- [13] Weber B, Lewicka S, Deuschle M, Colla M, Heuser I. Testosterone androstenedione and dihydrotestosterone concentrations are elevated in female patients with major depression. *Psychoneuroendocrinology* 2000;8:765–71.
- [14] Baischer W, Koinig G, Hartmann B, Huber J, Langer G. Hypothalamic-pituitary-gonadal axis in depressed premenopausal women: elevated blood testosterone concentrations compared to normal controls. *Psychoneuroendocrinology* 1995;20:553–9.
- [15] Kacar E, Sarinc Ulasli S, Günay E, et al. Assessment of neural alterations in obstructive sleep apnoea syndrome: can apparent diffusion coefficient measurements be useful? *Clin Respir J* 2016;10:189–97.
- [16] Le Bihan D. Apparent diffusion coefficient and beyond: what diffusion MR imaging can tell us about tissue structure. *Radiology* 2013;268:318–22.
- [17] Rotterdam ESHRE/ASRM-Sponsored PCOS Consensus Workshop Group. Revised 2003 consensus on diagnostic criteria and long-term health risks related to polycystic ovary syndrome (PCOS). *Hum Reprod* 2004;19:41–7.
- [18] Mascalchi M, Tessa C, Moretti M, et al. Whole brain apparent diffusion coefficient histogram: a new tool for evaluation of leukoaraiosis. *J Magn Reson Imaging* 2002;15:144–8.
- [19] Loubinoux I, Volk A, Borredon J, et al. Spreading of vasogenic edema and cytotoxic edema assessed by quantitative diffusion and T2 magnetic resonance imaging. *Stroke* 1997;28:419–27.
- [20] Ballmaier M, Toga AW, Blanton RE, et al. Anterior cingulate, gyrus rectus, and orbitofrontal abnormalities in elderly depressed patients: an MRI-based parcellation of the prefrontal cortex. *Am J Psychiatry* 2004;161:99–108.
- [21] Unlu E, Bagcioglu E, Acay MB, et al. Magnetic resonance imaging study of corpus callosum abnormalities in patients with different subtypes of schizophrenia. *Afr J Psychiatr* 2014;20:146–52.
- [22] Banasr M, Duman RS. Glial loss in the prefrontal cortex is sufficient to induce depressive-like behaviors. *Biol Psychiatry* 2008;64:863–70.
- [23] Grinband J, Savitskaya J, Wager TD, et al. The dorsal medial frontal cortex is sensitive to time on task, not response conflict or error likelihood. *Neuroimage* 2011;57:303–11.
- [24] Botvinick MM, Braver TS, Barch DM, Carter CS, Cohen JD. Conflict monitoring and cognitive control. *Psychol Rev* 2001;108:624–52.
- [25] Uher R, Brammer MJ, Murphy T, et al. Recovery and chronicity in anorexia nervosa: brain activity associated with differential outcomes. *Biol Psychiatry* 2003;54:934–42.
- [26] Uher R, Murphy T, Brammer MJ, et al. Medial prefrontal cortex activity associated with symptom provocation in eating disorders. *Am J Psychiatry* 2004;161:1238–46.
- [27] Stachenfeld NS. Sex hormone effects on body fluid regulation. *Exerc Sport Sci Rev* 2008;36:152–9.
- [28] Rasgon NL, Small GW, Siddarth P, et al. Estrogen use and brain metabolic change in older adults. A preliminary report. *Psychiatry Res* 2001;107:11–8.
- [29] Eberling JL, Wu C, Tong-Turnbeaugh R, Jagust WJ. Estrogen- and tamoxifen-associated effects on brain structure and function. *Neuroimage* 2004;21:364–71.
- [30] Archer J. Testosterone and human aggression: an evaluation of the challenge hypothesis. *Neurosci Biobehav Rev* 2006;30:319–45.