

Current Ablation Type Surgical Treatment Modalities in Treatment-Resistant Major Depression: Review of The Recent Major Surgical Series

Bulent Bakar¹, Cansel Cetin¹, Jonathan Oppong², Ahmet Melih Erdogan²

¹Kirikkale University Faculty of Medicine, Department of Neurosurgery, Kirikkale, Turkey

²Kirikkale University Faculty of Medicine, Kirikkale, Turkey

Address for Correspondence: Bulent Bakar, **E-mail:** bulentbanrs@yahoo.com

Received: 13.06.2018; **Accepted:** 14.08.2018; **Available Online Date:** 23.01.2019

©Copyright 2018 by Dokuz Eylül University, Institute of Health Sciences - Available online at www.jbachs.org

Cite this article as: Bakar B, Cetin C, Oppong J, Erdogan AM. Current Ablation Type Surgical Treatment Modalities In Treatment-Resistant Major Depression: Review of The Recent Major Surgical Series. J Basic Clin Health Sci 2019; 3:1-8. <https://doi.org/10.30621/jbachs.2019.452>

Abstract

Purpose: Major depression is currently a disease with high morbidity and mortality rates. About 20% of patients have treatment-resistant major depression (TRMD). This article which consisted of a recent large clinical case series reported in medical literature is constituted to screen ablative surgical treatment methods and their safety and efficacy in patients with TRMD.

Methods: Four types of ablative surgical modality (i. e. anterior cingulotomy, anterior capsulotomy, subcaudate tractotomy, limbic leucotomy) in TRMD patients were evaluated and patients' data which was used to describe the basis of radiologic and operative procedures and findings, and outcome was obtained from PubMed/Medline database between years 2000-2018.

Results: In literature, studies showed that about 40-60% of patients had complete remission and 35% of patients showed partial remission following anterior cingulotomy. It was reported that approximately 50% of patients were responsive and 40% of patients were remission following anterior capsulotomy. Studies demonstrated that about 55-75% of patients were responsive to treatment after performing subcaudate tractotomy. Long term clinical recovery was seen 36-76% of patients applied limbic leucotomy in literature.

Conclusion: In conclusion, the long term therapeutic effects and mechanism of action of these surgical techniques that were used last two decades in the management of patients with TRMD are still under investigation and the need for research on the long-term benefits of these surgical modalities should be considered.

Key words: cingulotomy, capsulotomy, subcaudate tractotomy, limbic leucotomy, treatment-resistant major depression

INTRODUCTION

Major depression is currently a disease with high morbidity and mortality rates and one also that brings severe economic burden to both patient and country (1). About 20% of all patients with major depression have treatment-resistant major depression (TRMD), which is defined in literature as patients with symptoms persisting for more than 2 years with no response to anti-depressant drug treatment (i. e. no response to two or more antidepressant regimens of adequate duration and dosage), electroconvulsive treatment and psychotherapies (1,2). Currently, in the management of the patients with TRMD, most of new treatment techniques (such as surgical approaches on the cingulum bundle and other brain regions, vagus nerve stimulation, deep brain stimulation, radiosurgery, MR-guided focused ultrasound etc.) are still in the advanced trial phase and the long term therapeutic effects are still under investigation (1). However, for these techniques to be applied, it is envisioned that patients with resistance to all medical treatments and psychotherapy, and those extremely affected for a protracted period should be selected (3-6). Although, there is

a rise in the number of reports about the new surgical treatment methods and the results of these treatment modalities in patients with treatment resistant major depression (TRMD), to the best of our knowledge, most of these researches present case reports, and a few number of large series exists in medical literature.

This article which consisted of findings of a *recent* large clinical case series reported in medical literature is constituted for the purpose of screening the four types of the ablative surgical treatment methods (i.e., anterior cingulotomy, anterior capsulotomy, subcaudate tractotomy, limbic leucotomy) and their safety and efficacy in patients with TRMD. Moreover, these findings were discussed with the findings of patients applied either deep brain stimulation (DBS) or vagal nerve stimulation (VNS) in both terms of safety and efficacy. The articles reporting other surgical techniques other than the four types of ablation techniques mentioned in this article, non-English spelling articles, and case reports were excluded from this article.

Table 1. Table demonstrates the recommended surgical criteria for patients with treatment-resistant major depression that may be subjected to psychosurgical treatment**INCLUSION CRITERIA FOR ABLATION TYPE SURGICAL TREATMENT**

1. Existing symptoms of the patients should be prevalent for longer than one year
2. The patients' symptoms should be consistent with the under listed DSM-V diagnostic criteria:
There should be at least five of the following symptoms that occur in most of the day, almost every day for two consecutive weeks. One of the symptoms should be a depressive mood or loss of interest.
 - Depressive mood – sadness, breakdown, emptiness, feelings of desperation
 - Loss of interest and desire
 - Sleeplessness or excessive sleep
 - Loss of appetite or weight changes
 - Psychomotor retardation or agitation
 - Low energy
 - Poor concentration
 - Thoughts of worthlessness or guilt
 - Repetitive thoughts of death or suicide.

The above -mentioned symptoms are not related to substance use or the psychological effects of a general medical situation.
3. These existing symptoms should have been documented by a treatment team to be resistant to primary medical treatment (such as tri-cyclic anti depressants, MAO inhibitors, serotonin receptor re-uptake inhibitors) and secondary treatment modalities (Lithium, narcoleptics, anticonvulsants, thyroid hormones, etc)
4. The patient must have had electroconvulsive therapy for at least twice but with recurring symptoms.
5. Patient must not have benefited from cognitive behavioral therapy and/ or psychotherapy methods.
6. Despite all these treatments, patients should be severely affected.
7. Patients should have agreed to undergo surgical treatment applied to them.
8. The diagnostic criteria of personality disorder should not be found in patient.

EXCLUSION CRITERIA FOR ABLATION TYPE SURGICAL TREATMENT

1. Patients with Axis I disease (organic brain syndrome, delusional disease, alcohol/substance abuse)
2. Patients with Axis III disease (medium / severe brain atrophy, concussion, tumor, previous history of brain trauma)

MATERIALS and METHODS**Materials**

In this study, ablation type surgical modalities in TRMD patients were evaluated and patients' data which was used to describe the basis of radiologic and operative findings, operative procedures, and postoperative outcome was obtained from 11 of the major current clinical studies reported in the PubMed/Medline database between the years 2000–2018. To search the medical literature, the key words "treatment resistant major depression", "psychosurgery", "ablation type surgery", "ablative surgery", "cingulotomy", "anterior capsulotomy", "subcaudate tractotomy", "limbic leucotomy", "vagus nerve stimulation", "VNS", "deep brain stimulation", and "DBS" were used.

The recommended surgical criteria for TRMD patients that may be subjected to surgical treatment are described in Table 1 (7).

Stereotactic ablative surgical techniques

Currently, the main ablation type surgical techniques applied are as follows (Table 2, Figure 1):

- Anterior Cingulotomy: In this stereotactic surgical method, the location of the areas on which thermocoagulation is often applied are described as follows (8–11):
 - 15–20 mm posterior to the tip of the frontal horn of the lateral ventricle for each brain hemisphere, initial lesions are made 2–5 mm above the upper surface of the corpus callosum and 7 mm away from the midline laterally (the midline is generally determined by the falx cerebri).

- Following this, the electrodes are withdrawn 7–8 mm backwards for the secondary lesions. At the end of the procedure, the relevant brain areas are expected to have lesions ellipto-cylindrical in shape, 18 mm in depth, 13 mm antero-posterior in length and 6 mm in width.
- Anterior Capsulotomy (ACAP): In this treatment method, bilateral ablation is applied to the anterior 1/3 and middle 1/3 portions of the capsula interna formation. In this aim, lesions are often made 17 mm from the midline laterally, 10 mm from the anterior commissura rostrally and a 15–18 mm long and 4–5 mm wide thermocoagulative lesion is made 8 mm above the intercommissural line (2, 10, 12).
- Subcaudate Tractotomy (Innominotomy): The location of the thermocoagulative lesions of this surgical treatment is described as immediately below the head of the caudate nucleus (7–15 mm lateral to the midline of the posteromedial orbitofrontal cortex, i. e. the postero-infero-medial quadrant of the frontal lobe). Formation of the lesion is aimed at the anteroposterior plane at the level of the planum sphenoidale between 6–18 mm from the midline and stretching 20 mm antero-posteriorly (3, 13, 14).
- Limbic Leucotomy: This surgical treatment is a combination of the "anterior cingulotomy" and the "subcaudate tractotomy" techniques (3, 13–15).

RESULTS

The details of the ablation type stereotactic surgical treatment methods and their safety and efficacy in patients obtained from the 11 of the clinical trials reported in literature could be seen in Table 2 and Table 3.

Table 2. Table describes the current psychosurgical treatment modalities in treatment resistant major depression

Surgery	Usually preferred cerebral ablation target points	Purpose
Anterior cingulotomy [1, 4, 8, 9, 10, 11, 14]	First lesions, 15-20 mm posterior to the tip of the frontal horn of the lateral ventricle, 2-5 mm above the upper surface of the corpus callosum, and 7 mm above from the midline of the brain which is usually marked by falx. For the second lesion, the electrodes are pulled back 7-8 mm	To cut the fibers between the dorsal anterior cingulate cortex and the orbitofrontal cortex, amygdala and hippocampus
Anterior capsulotomy [2, 8, 10, 12, 16]	Ablation to 1/3 anterior and 1/3 middle parts of the frontal leg of the bilateral capsular interna formation (next to foramen Monro level). For this purpose thermocoagulative lesion is made 17 mm lateral of the midline, 10 mm rostral to the anterior commissure	To cut the connection from the orbitofrontal cortex, the subgenual cingulate cortex and the caudate nucleus to the medial, dorsomedial and anterior thalamus
Subcaudate tractotomy [3, 13, 14, 17]	Just below the head of the caudate nucleus (the posteroinferomedial quadrant of the frontal lobe, 7-15 mm laterally from the midline of the posteromedial orbitofrontal cortex)	To cut the connections between the orbitofrontal cortex, subgenual cingulate cortex, striatum, thalamus and amygdala
Limbic leukotomy [3, 13, 14, 15, 18, 19, 20]	Combination of "anterior cingulotomy" and "subcaudate tractotomy" techniques	
Vagus nevre stimulation [30, 31, 32, 33]	Left vagus nerve	To induce potentials on the ventroposterior complex and intralaminar areas through the thalamocortical pathways, resulting in effects on hypothalamus, amygdala and other cortical structures
Deep brain stimulation [1, 21, 34, 35, 36, 37, 38]	Subcallosal cingulate gyrus Nucleus accumbens Ventral capsule/ ventral striatum	To produce inhibition by depolarization blockade and excitatory axonal response and alter the activity in the neuronal circuits

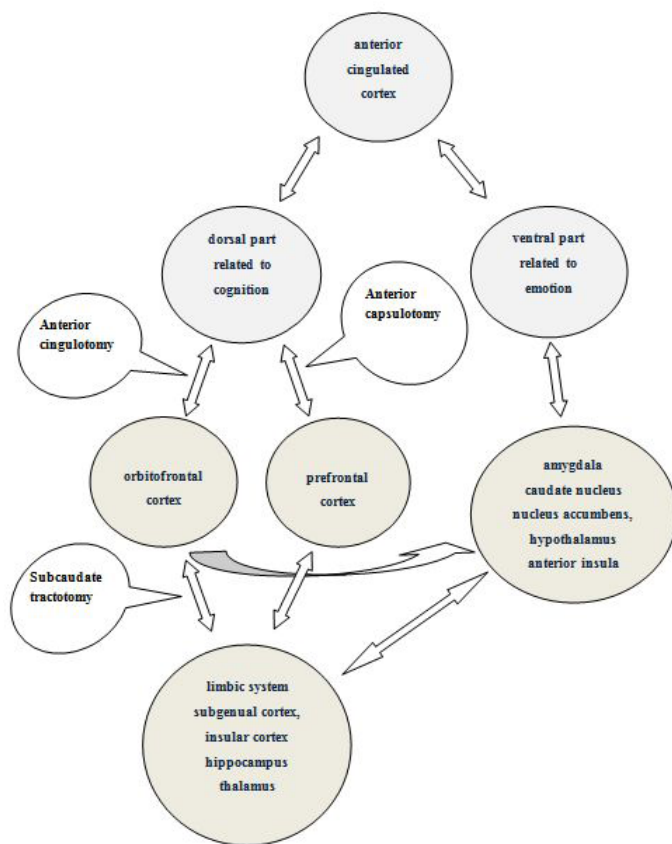


Figure 1. Schematic illustration of the commonly preferred cerebral target points of the current ablative surgical techniques.

Shields et al. showed approximately 41.2% of patients with complete remission and 35.3% of patients with partial remission following anterior cingulotomy. They reported that complications related to this technique include transient or permanent urinary incontinence (12.1%), transient speech disorders (3%), transient memory defects (3%), epilepsy (3%) and secondary infections (3%) (14). Steele et al. reported that approximately 62% of patients were responsive and 25% of patients were non-responsive following anterior cingulotomy (11). On the other hand, Eljamel et al. founded that 60% of patients were responsive and 20% of the patients were in remission (9). Additionally, Christmas et al. declared that 60% of patients were responsive and 20% of the patients in remission following anterior cingulotomy. They reported that most of the complications include "transient seizure", "urinary impairment" and "headache" (8).

In the study conducted by Christmas et al., 50% of patients were responsive and 40% of patients were found to be in remission, and 10% had deteriorated following anterior capsulotomy. A few number of patients showed concentration problems (10%), motivation impairment (20%) and memory deficits (10%). Additionally, 10% of patients were found to have urinary incontinence and dizziness. Suicide attempts and suicides were not reported in any patient (8). Hurwitz et al. reported that 50% of the patients were responsive in long term follow-up (2-3 years) postoperatively. Some of the patients showed transient postoperative confusion (25.0%), fatigue (25.0%), and subjective emotional blunting (25.0%). Several patients suffered from a decline in neuropsychological capacities (disorders in attention, mental acuity, recent verbal memory, and problem solving) which were either unchanged or improved (10). Eljamel et al. reported that 25% of patients were responsive and 10% patients were in remission after anterior capsulotomy. Some of the patients had

Table 3. Table demonstrates the findings of the recent large clinical case series reported in medical literature according to the name of the authors

Surgical approach	Author(s)	N	Outcome	Complication
Anterior cingulotomy	Shields et al ¹⁴	17	Responsive: 41.2% Partial remission: 35.3% Non-responsive: 23.5%	Transient or permanent urinary incontinence (12.1%), transient speech disorders (3%), transient memory problems (3%), epilepsy (3%), secondary infections (3%)
	Steele et al ¹¹	8	Responsive: 62% Non-responsive: 25%	-
	Eljamel et al ⁹	20	Responsive: 60% Remission: 20%	Headache, nausea, dizziness, incontinence, epilepsy, confusion
	Christmas et al ⁸	5	Responsive: 60% Remission: 20%	Transient epilepsy, urinary retention
Anterior capsulotomy	Christmas et al ²	23	Responsive: 50% Remission: 40% Non-responsive: 10%	Concentration problems (10%), motivation impairment (20%), memory deficits (10%), urinary incontinence (10%), dizziness (10%)
	Hurwitz et al ¹⁰		Responsive: 50%	Transient postoperative confusion (25.0%), fatigue (25.0%), subjective emotional blunting (25.0%)
	Eljamel et al ⁹	5	Responsive: 25% Remission: 10%	Headache, nausea, dizziness, incontinence, epilepsy, confusion
	Christmas et al ⁸	5	Responsive: 40% Remission: 40%	Memory difficulties, headache
	Subramanian et al ¹⁶	37	Responsive: 50%	Epilepsy, transient and mild confusion, motivation impairment, memory problems, transient incontinence of urine
	Hodgkiss et al ¹⁷		Responsive: 35% Remission: 32% Non-responsive: 32%	Transient lethargy, transient and mild confusion, transient incontinence of urine, headache
	Kim et al ⁷	7	Responsive: 71% Non-responsive: 29%	Transient incontinence of urine
Subcaudate tractotomy	Kelly et al ¹⁸	17	Responsive: 78% Non-responsive: 22%	-
	Montoya ¹³	21	Responsive: 50%	Transient headache, confusion, lost of motivation, perseverative behavior and incontinence, suicide
Limbic leukotomy				

headache, nausea, dizziness, incontinence, epilepsy, confusion (9). Christmas et al. reported in 2015 that 40% of patients were responsive and 40% of patients were in remission after anterior capsulotomy surgery (8). Subramanian et al. showed that 50% of the patients were responsive and some of the patients had epilepsy, transient and mild confusion, motivation impairment, memory problems, transient incontinence of urine (16). However, no deterioration in executive functions, attention and concentration or memory functions on formal psychometric testing was found in any patient (16).

Hodgkiss et al. reported that approximately 35% of the patients recovered, 32% improved and 32% were unchanged or worse following the subcaudate tractotomy (innominotomy). Furthermore, they reported side effects such as transient lethargy, transient and mild confusion, transient incontinence of urine, and headache (17). However, Kim et al. showed that 71% of the patients performed subcaudate capsulotomy were responsive while 29% were non-responsive (7).

Following the limbic leukotomy, Kelly et al. reported that 78% of the patients improved and 22% were unchanged in long

term follow-up (18, 19). Additionally, Montaya et al. declared that 50% of the patients were responsive (13). In the long term, clinical recovery was seen in 36–76% of patients on which limbic leucotomy was applied (3, 13, 14). Although Kelly et al. did not report any side effect, Montaya et al. reported some side effects that included transient headache, confusion, loss of motivation, perseverative behavior and incontinence and no patient showed memory and attention disorders (3, 13, 14).

DISCUSSION

Anatomically, the cingulate cortex is divided into two parts namely the anterior and posterior. The anterior cingulate cortex is located in the dorsal-inferior part of the frontal lobe, the dorsal parts playing roles in cognitive functions and the ventral parts playing roles in emotional functions. As a result, the cognitive part is related to the prefrontal cortex, the parietal cortex and the orbitofrontal cortex areas. The emotional part is also related to the amygdala, nucleus accumbens, hypothalamus and anterior insula (20, 21). Pathologic lesions in this region lead to such findings as emotional imbalance, failure to reason out mistakes,

decrease in concentration and akinetic mutism. The functions of the anterior cingulate cortex are discussed in literature as follows: Subconscious processing, language processing, visual field processing, recognizing changes in physical conditions and modifying behavior, participation in emotional connections (limbic system, autonomic nervous system, insular cortex), participation in cognitive activities (concentration, cognitive control, processing memory, achievement aimed behavior), distinguishing between positive, negative or good/bad emotional stimulus by the relation with the orbitofrontal cortex (22, 23). The cingulum bundle on the other hand forms dense connections with the frontal, temporal and parietal cortical structures and based on these connections, plays important roles in the implementation of cognitive functions, decision making and emotion (24). The basic functions and anatomic structures of this bundle however have not been fully understood. The structures of the orbitofrontal cortex however form dense connections with the limbic system through the subgenual cortex, insular cortex and the hippocampus (25). The posterior cingulate cortex is the dorsal continuation of the anterior cingulate cortex and is located in the inferior portion of the parietal lobe. Here it is in a tight relationship with the prefrontal cortex. Due to this, it takes over roles such as motor control management, pain, autobiographic memory (recall of the past and people), visual attention and the control of eye movement. The aftermath of pathologic lesions or abnormal metabolism brings about such diseases as Alzheimer's disease, schizophrenia, autism, attention deficit hyperactivity disorder and depression (26).

Radiologic analysis of patients with major depression has shown abnormalities in the cortico-striato-thalamo-cortical pathways as well as in the cingulate cortex. Patients had increased metabolism and blood flow in the posterior orbitofrontal cortex and rostral anterior cingulate cortex. This metabolism was a marked increase in patients who did not undergo medical treatment whereas this increase was significantly reduced in patients in remission (24, 27). On the other hand, positron emission tomography (PET) and functional magnetic resonance imaging (fMRI) studies showed increased metabolism in the orbitofrontal cortex, insula, medial thalamus and amygdala in contrast with decreased metabolism in the dorsolateral prefrontal cortex and anterior cingulate cortex of patients. These imbalances have been known to approach normal after treatment (3). However, information about the abnormalities in the structures of the lateral and medial prefrontal cortex remains controversial.

In *anterior cingulotomy*, the aim is to disrupt the fibers stretched across the dorsal anterior cingulate cortex, orbitofrontal cortex, amygdala and hippocampus (8-11). The fibers in this area show an inclination towards the anterior and posterior and are interconnected with the amygdala, thalamus, prefrontal cortices, dorsomedial frontal cortices and the precuneus. While the dorsal anterior cingulate cortex mostly forms connections with the hippocampus (papez circuit) and lateral prefrontal cortex, the subgenual cingulate cortex (regional aim of subcaudate tractotomy) forms connections with the amygdala, nucleus accumbens, hypothalamus, orbitofrontal cortex and

the visceromotor brain stem regions (14). The success of this surgical treatment is defended as being related to the degree of involvement of the fibers stretching towards the amygdala (25). Studies have shown 40% of patients had complete remission and 35% of patients were partial remission following this surgery. Complications include transient or permanent urinary incontinence, transient speech disorders, transient memory defects, epilepsy and secondary infections to surgical interventions (14). On the other hand, with the study conducted by Ridout et al, patients on which cingulotomy alone or additive anterior cingulotomy was performed, emotional breakdown and secondary to this, impairment in concentration was shown (12). With the survey study conducted by Leiphart et al., at the end of stereotactic surgical approaches performed on 413 major depression patients, anterior cingulotomy was found to produce better results as compared to anterior capsulotomy, subcaudate tractotomy and limbic leucotomy. Furthermore, it was propounded that interventions on single anatomic locations produced better results than interventions on combined anatomic locations (4). With *the anterior capsulotomy* approach, the fronto-thalamic pathways found in the 1/3 anterior part of the fore limb of the internal capsule, which interconnects the prefrontal cortex and the anterior cingulate cortex with the thalamus, the hippocampus and amygdala are damaged by using thermocoagulation. The aim of this treatment method is to disrupt the connection stretching from the orbitofrontal cortex, subgenual cingulate cortex and caudate nucleus to the medial, dorsomedial and anterior thalamus and by so doing reduce the connections of emotional processing (10, 12). In recent publications, the middle segment of the anterior internal capsule is beginning to be added to this anatomic area (3). Following anterior capsulotomy, 50% of patients were responsive and 40% of patients were found to be in remission. In the neuropsychological evaluation (general intelligence, memory, executive functions), very few patients showed concentration problems, motivation impairment and memory deficits. Additionally, patients were found to have urinary incontinence and dizziness. Suicide attempts or suicides were however not reported in any patient (8). On the other hand, Subramanian et al. reported no deterioration in executive functions, attention and concentration or memory functions in any patients (16). Unfortunately, in literature, excluding patients with depression, suicidal tendencies, transient headache, confusion, disinhibition, weight gain, lethargy, urinary incontinence has been noticed in patients with other psychiatric disorders for which this surgical approach is applied (3). The aim of the formation of lesions in *subcaudate tractotomy* is to damage the connections between the orbitofrontal cortex, subgenual cingulate cortex, striatum, thalamus and amygdala (3, 13, 14). Subcaudate tractotomy (innominotomy) showed about 55-75% of patients responding to treatment. One percent of the patients showed suicidal tendencies and 6-7% could develop epilepsy. Furthermore, it has been reported that side effects including transient lethargy, transient and mild confusion, transient urine incontinence, and headache, may occur (3, 28). With the approach of *limbic leucotomy*, the aim is to form a wider lesion with the combination of anterior cingulotomy and subcaudate tractotomy

techniques. Long term clinical recovery was seen in 36–76% of patients on which this approach was applied. Side effects have been reported to include transient headache, confusion, loss of motivation, perseverative behavior and incontinence. No patient showed memory and attention disorders (3, 13, 14).

On the other hand, alternative surgical treatment modalities to permanent surgical treatment techniques have begun to be discussed in literature. Thus, a new method known as *vagus nerve stimulation (VNS)* that has begun to be used has been shown to produce successful results. Studies have been reported that VNS critically effects on the mood through the orbital cortex and the limbic system in the treatment of depression. The mechanism of effect of the VNS is not fully known and studies are being performed in various fields to clarify this subject. By affecting the vagus nerve, VNS creates stimulated potentials in the ventro-posterior complex of the thalamus and the intralaminar areas, which in turn by the thalamocortical pathways create effects on the hypothalamus, amygdala and other cortical structures (such as ventromedial prefrontal cortex) (29, 30). Following quite a number of clinical studies, long term follow-up results of patients showed an average of 30–55% with full recovery, and 20–40% of patients proven to have met recovery criteria. Side effects although rare include infections, breakage and/or displacement in position of electrodes, cardiac rhythm disorders, hypomania, voice changes and an increase in the tendency to commit suicide (31, 32). On the other hand, Christmas et al. described the 12-month clinical outcomes of patients with TRMD treated with anterior capsulotomy, anterior cingulotomy or vagus nerve stimulation. The response rates were 40% for anterior capsulotomy, 60% for anterior cingulotomy and 20% for VNS. They pointed out that adverse effects in all three procedures were relatively mild, and transient in most cases. There were no deaths. Although their study sample was small, they concluded that anterior capsulotomy and anterior cingulotomy, but not VNS, were associated with favorable response rates at 12 months (8). Andrade et al. concluded that VNS has shown its beneficial effect with its low number of unwanted side effects at long-term follow-up, although its effectiveness is low immediately postoperatively and at short-term follow-up (29).

Another surgical technique that is still under development is *deep brain stimulation (DBS)*. In this surgical technique, stimulatory VNS-like electrodes are placed through stereotactic methods in specified brain areas (such as the subcallosal cingulate gyrus, nucleus accumbens, ventral capsule/ventral striatum, inferior thalamic peduncle, habenula/lateral habenula, and the medial forebrain bundle) (1, 33). In this surgery, a lesion is not produced and its effects are reversible. However, the exact mechanism of action of the DBS is still unknown and it was concluded that DBS may produce inhibition by depolarization blockade and excitatory axonal response and it alters the activity in the neuronal circuits (6). Patients on which stimulations were applied on the subcallosal cingulate gyrus showed 60–70% response to treatment and 40–50% ratio of remission obtained in long term follow-up. On other brain areas on which stimulation was applied, these values reduced to 40–50% response to treatment and 20–30% remission

rates were found (20). Additionally, Lozano et al. reported that 60% cases responded to stimulation of the subcallosal cingulate gyrus and remission obtained in 35% patients (34). On the other hand, Kennedy et al. showed that the average response rates 3 years after DBS applied to the subcallosal cingulate gyrus were 75%, and average response rate was 64.3%. No significant adverse events were reported, although two patients died by suicide during depressive relapses (35). Malone et al. pointed that following the stimulation of ventral capsule/ventral striatum, 53.3% of patients were responsive and 40% of patients were in remission at long term follow-up (37). As side effects, infection, breakage/displacement of electrodes, transient anxiety, nervousness, hypomania and insomnia have been reported rarely. Due to the tendency to commit suicide, the need for long term follow up of these patients is recommended (3, 5, 30, 36). Narang et al. concluded in their review article that response and remission at all DBS positioning targets (such as subcallosal cingulate gyrus, ventral capsule/ventral striatum, nucleus accumbens, and medial forebrain bundle) are promising, with response rates of 40% to 70%, while remission rates vary depending on the stimulation target location. For example, remission rates at 1 year were 26%-subcallosal cingulate gyrus, 41%-ventral capsule/ventral striatum, and 45%-nucleus accumbens. They hypothesized that treatment at the subcallosal cingulate gyrus tends to improve mood, whereas stimulation of the other brain targets induces better motivation (37).

With these findings mentioned above, it could be said that because of its broadly similar clinical improvements and acceptable side-effect profile with DBS and VNS procedures, stereotactic ablation surgery for patients with TRMD is likely to boost the interest amongst patients and clinicians, although there have been some insufficiencies in these surgical procedures (such as cost, local availability of the procedures, lack of knowledge about this treatment modality for severely refractory patients) and recent development of several DBS procedures (16). On the other hand, it was seen at the end of this study that the discussion of the properties of the ablative procedures were restricted by several factors in this review. 1) To achieve the maximum therapeutic result in patients with TRMD, no optimal cerebral target point for both ablative surgery and/or DBS has still been described in the literature (33). It was thought that this restriction was related to a small number of clinical trials which consisted of a small number of patients being reported in this regard. 2) In literature, there has been found little information about the neurocognitive disabilities occurred following ablative surgeries. Therefore, it is concluded that the preoperative and postoperative application of neurocognitive test batteries is necessary to determine the neurocognitive deficiencies that may occur in these patient groups.

Limitations

This review article had some limitations. Firstly, other surgical modalities, VNS and especially the DBS technique, are gaining in popularity with the application convenience and the reason for the reversible effects. For these reasons, most of the researches are directed towards investigating these treatment methods and

most of studies about the ablative surgery had therefore to be consisted of few patients. On the other hand, very few articles have been found in the literature because the data of this review was obtained from the only one database but not gathered from other databases (such as EMBASE, Index Copernicus etc.). With these reasons, this study did not construct as a meta-analysis. In this manner, the findings of this review could not reflect the wide population, properly. However, the findings of this review demonstrated that these surgical modalities which may be cheaper than other surgical modalities have similar clinical improvements and acceptable side-effect profile with DBS and VNS procedures, and this study could be likely to boost the interest amongst patients and clinicians for stereotactic ablation surgery. Secondly, patients' characteristics (such as socio-demographic data, characteristics of depressive disorder, criteria for decision of resistance to treatment modalities etc.) were not described in this study. However, the main purpose of this study was to examine only the efficacy of ablation therapy in patients with treatment resistant major depression. It has been thought that the purpose of this article could be confused by the patients' characteristics described above when they were inserted into study. For this reason, those information was not included in this article.

CONCLUSION

In conclusion, the long term therapeutic effects and mechanism of action of these surgical techniques that were used last two decades in the management of patients with TRMD are still under investigation and the need for research on the long-term benefits of these surgical modalities should be considered.

Conflict of interest and financial disclosure statements

The authors declare that they have no conflict of interest. They also declare that they have not engaged in any financial relationship with any company whose product might be affected by the research described or with any company that makes or markets a competing product.

Peer-review: Externally peer-reviewed.

Author Contributions: Concept - B.B; Design - B.B, C.C, A.M.E; Supervision - B.B; Data Collection and/or Processing - B.B, C.C, J.O, A.M.E; Analysis and/or Interpretation - B.B; Literature Search - B.B, C.C, J.O, A.M.E; Writing Manuscript - B.B, J.O; Critical Review - B.B, J.O.

Conflict of Interest: No conflict of interest was declared by the authors.

Financial Disclosure: The authors declared that this study has received no financial support.

REFERENCES

- Volpini M, Giacobbe P, Cosgrove GR, Levitt A, Lozano AM, Lipsman n. The history and future of ablative neurosurgery for major depressive disorder. *Stereotact Funct Neurosurg* 2017;95:216–228. [\[CrossRef\]](#)
- Christmas D, Eljamel MS, Butler S, et al. Long term outcome of thermal anterior capsulotomy for chronic, treatment refractory depression. *J Neurol Neurosurg Psychiatry* 2011;82:594–600. [\[CrossRef\]](#)
- Lapidus KA, Kopell BH, Ben-Haim S, Rezai AR, Goodman WK. History of psychosurgery: a psychiatrist's perspective. *World Neurosurg* 2013;80:S27.e1–16. [\[CrossRef\]](#)
- Leiphart JW, Valone FH 3rd. Stereotactic lesions for the treatment of psychiatric disorders. *J Neurosurg* 2010;113:1204–1211. [\[CrossRef\]](#)
- Luigjes J, de Kwaasteniet BP, de Koning PP, et al. Surgery for psychiatric disorders. *World Neurosurg* 2013;80:S31.e17–28. [\[CrossRef\]](#)
- Sachdev PS, Chen X. Neurosurgical treatment of mood disorders: traditional psychosurgery and the advent of deep brain stimulation. *Curr Opin Psychiatry* 2009;22:25–31. [\[CrossRef\]](#)
- Kim MC, Lee TK, Choi CR. Review of long-term results of stereotactic psychosurgery. *Neurol Med Chir (Tokyo)* 2002;42:365–371. [\[CrossRef\]](#)
- Christmas D, Matthews K. Neurosurgical treatments for patients with chronic, treatment-refractory depression: a retrospective, consecutive, case series comparison of anterior capsulotomy, anterior cingulotomy and vagus nerve stimulation. *Stereotact Funct Neurosurg* 2015;93:387–392. [\[CrossRef\]](#)
- Eljamel MS. Ablative neurosurgery for mental disorders: is there still a role in the 21st century? A personal perspective. *Neurosurg Focus* 2008;25:E4. [\[CrossRef\]](#)
- Hurwitz TA, Honey CR, Allen J, et al. Bilateral anterior capsulotomy for intractable depression. *J Neuropsychiatry Clin Neurosci* 2012;24:176–182. [\[CrossRef\]](#)
- Steele JD, Christmas D, Eljamel MS, Matthews K. Anterior cingulotomy for major depression: clinical outcome and relationship to lesion characteristics. *Biol Psychiatry* 2008;63:670–677. [\[CrossRef\]](#)
- Ridout N, O'Carroll RE, Dritschel B, Christmas D, Eljamel M, Matthews K. Emotion recognition from dynamic emotional displays following anterior cingulotomy and anterior capsulotomy for chronic depression. *Neuropsychologia* 2007;45:1735–1743. [\[CrossRef\]](#)
- Montoya A, Weiss AP, Price BH, et al. Magnetic resonance imaging-guided stereotactic limbic leukotomy for treatment of intractable psychiatric disease. *Neurosurgery* 2002;50:1043–1052. [\[CrossRef\]](#)
- Shields DC, Asaad W, Eskandar EN, et al. Prospective assessment of stereotactic ablative surgery for intractable major depression. *Biol Psychiatry* 2008;64:449–454. [\[CrossRef\]](#)
- Kelly D, Richardson A, Mitchell-Heggs N. Stereotactic limbic leukotomy: neurophysiological aspects and operative technique. *Br J Psychiatry* 1973;123:133–140. [\[CrossRef\]](#)
- Subramanian L, Bracht T, Jenkins P, et al. Clinical improvements following bilateral anterior capsulotomy in treatment-resistant depression. *Psychol Med* 2017;47:1097–1106. [\[CrossRef\]](#)
- Hodgkiss AD, Malizia AL, Bartlett JR, Bridges PK. Outcome after the psychosurgical operation of stereotactic subcaudate tractotomy, 1979–1991. *J Neuropsychiatry Clin Neurosci* 1995;7:230–234. [\[CrossRef\]](#)
- Kelly D, Richardson A, Mitchell-Heggs N, Greenup J, Chen C, Hafner RJ. Stereotactic limbic leukotomy: a preliminary report on forty patients. *Br J Psychiatry* 1973;123:141–148. [\[CrossRef\]](#)
- Kelly D, Mitchell-Heggs N. Stereotactic limbic leukotomy - a follow-up study of thirty patients. *Postgrad Med J* 1973;49:865–882. [\[CrossRef\]](#)
- Krack P, Hariz MI, Baunez C, Guridi J, Obeso JA. Deep brain stimulation: from neurology to psychiatry? *Trends Neurosci* 2010;33:474–484. [\[CrossRef\]](#)

21. Richter EO, Davis KD, Hamani C, Hutchison WD, Dostrovsky JO, Lozano AM. Cingulotomy for psychiatric disease: microelectrode guidance, a callosal reference system for documenting lesion location, and clinical results. *Neurosurgery* 2008;62(6 Suppl 3):622-630. [\[CrossRef\]](#)
22. Aydin S, Abuzayed B. Psychosurgery: review of latest concepts and applications. *J Neurol Surg A Cent Eur Neurosurg* 2013;74:29-46. [\[CrossRef\]](#)
23. Gentil AF, Eskandar EN, Marci CD, Evans KC, Dougherty DD. Physiological responses to brain stimulation during limbic surgery: further evidence of anterior cingulate modulation of autonomic arousal. *Biol Psychiatry* 2009;66:695-701. [\[CrossRef\]](#)
24. Shah DB, Pesiridou A, Baltuch GH, Malone DA, O'Reardon JP. Functional neurosurgery in the treatment of severe obsessive compulsive disorder and major depression: overview of disease circuits and therapeutic targeting for the clinician. *Psychiatry (Edmont)* 2008;5:24-33.
25. Heilbronner SR, Haber SN. Frontal cortical and subcortical projections provide a basis for segmenting the cingulum bundle: implications for neuroimaging and psychiatric disorders. *J Neurosci* 2014;34:10041-10054. [\[CrossRef\]](#)
26. Gasquoin PG. Localization of function in anterior cingulate cortex: from psychosurgery to functional neuroimaging. *Neurosci Biobehav Rev* 2013;37:340-348. [\[CrossRef\]](#)
27. Steele JD, Currie J, Lawrie SM, Reid I. Prefrontal cortical functional abnormality in major depressive disorder: a stereotactic meta-analysis. *J Affect Disord* 2007;101:1-11. [\[CrossRef\]](#)
28. Bridges PK, Bartlett JR, Hale AS, Poynton AM, Malizia AL, Hodgkiss AD. Psychosurgery: stereotactic subcaudate tractomy. An indispensable treatment. *Br J Psychiatry* 1994;165:599-611. [\[CrossRef\]](#)
29. Andrade P, Noblesse LH, Temel Y, et al. Neurostimulatory and ablative treatment options in major depressive disorder: a systematic review. *Acta Neurochir (Wien)* 2010;152:565-577. [\[CrossRef\]](#)
30. Rizvi SJ, Donovan M, Giacobbe P, Placenza F, Rotzinger S, Kennedy SH. Neurostimulation therapies for treatment resistant depression: a focus on vagus nerve stimulation and deep brain stimulation. *Int Rev Psychiatry* 2011;23:424-436. [\[CrossRef\]](#)
31. Rush AJ, George MS, Sackeim HA, et al. Vagus nerve stimulation (VNS) for treatment-resistant depressions: a multicenter study. *Biol Psychiatry* 2000;47:276-286. [\[CrossRef\]](#)
32. Rush AJ, Marangell LB, Sackeim HA, et al. Vagus nerve stimulation for treatment-resistant depression: a randomized, controlled acute phase trial. *Biol Psychiatry* 2005;58:347-354. [\[CrossRef\]](#)
33. Morishita T, Fayad SM, Higuchi MA, Nestor KA, Foote KD. Deep brain stimulation for treatment-resistant depression: systematic review of clinical outcomes. *Neurotherapeutics* 2014;11:475-484. [\[CrossRef\]](#)
34. Lozano AM, Mayberg HS, Giacobbe P, Hamani C, Craddock RC, Kennedy SH. Subcallosal cingulate gyrus deep brain stimulation for treatment-resistant depression. *Biol Psychiatry* 2008;64:461-467. [\[CrossRef\]](#) <https://doi.org/10.1016/j.biopsych.2008.05.034>
35. Kennedy SH, Giacobbe P, Rizvi SJ, et al. Deep brain stimulation for treatment-resistant depression: follow-up after 3 to 6 years. *Am J Psychiatry* 2011;168:502-510. [\[CrossRef\]](#)
36. Malone DA Jr, Dougherty DD, Rezai AR, et al. Deep brain stimulation of the ventral capsule/ventral striatum for treatment-resistant depression. *Biol Psychiatry* 2009;65:267-275. [\[CrossRef\]](#)
37. Narang P, Retzlaff A, Brar K, Lippmann S. Deep brain stimulation for treatment-refractory depression. *South Med J* 2016;109:700-703. [\[CrossRef\]](#)